

Mucus recirculation by missed sinus ostium

A 66-year-old woman presented with persistent postnasal discharge and a history of recurrent maxillary sinusitis despite having had antibiotic treatment for several years. She had undergone endoscopic sinus surgery including middle meatal antrostomy 10 years before. The 70° nasal endoscopic examination revealed the presence of the so-called ‘missed maxillary sinus ostium’, mucus collection flowing back from the surgical maxillary sinusotomy into the natural maxillary ostium (Figure 1 and Video 1; available at www.bjhm.co.uk). A bridge of scarring tissue creating the surgical ostium was identified (Figure 2), and two ostia were joined to form one ostium using backbiting forceps and a microdebrider instrument through the revised maxillary antrostomy. At 2-month postoperative follow up, mucus recirculation was completely resolved and the maxillary antrostomy remained patent. The patient did well without any specific nasal discomfort. When mucus recirculation is recognised after nasal sinus surgery, the treatment of choice is to connect the surgically created ostium with the natural ostium (Levine and Casiano, 2017).

Author details

¹Department of Otorhinolaryngology, Jeju National University School of Medicine, Jeju, South Korea

Reference

Levine CG, Casiano RR. Revision functional endoscopic sinus surgery. *Otolaryngol Clin North Am.* 2017;50(1):143–164. <https://doi.org/10.1016/j.otc.2016.08.012>

Hyun Jung Kim¹

Jae-Yeop Sim¹

Hee Jun Yi¹

Jeong Hong Kim¹

Author details can be found at the end of this article

Correspondence to:

Jeong Hong Kim;
sevent70@gmail.com

How to cite this article:

Kim HJ, Sim J-Y, Yi HJ, Kim JH. Mucus recirculation by missed sinus ostium. *Br J Hosp Med.* 2022. <https://doi.org/10.12968/hmed.2021.0463>

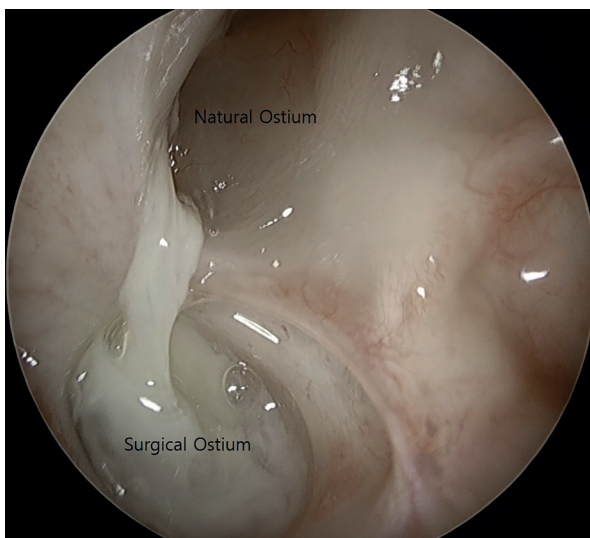


Figure 1. The 70° nasal endoscopic examination revealed the presence of the mucus collection flowing back from the surgical maxillary sinusotomy into the natural maxillary ostium.

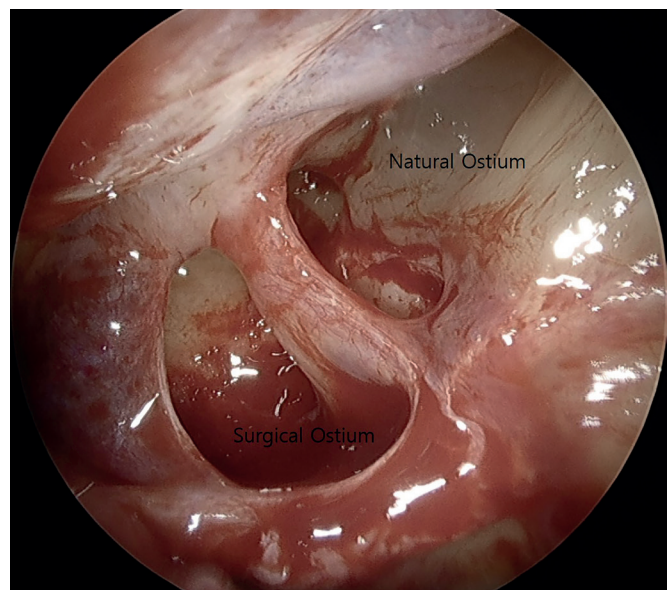


Figure 2. A bridge of scarring tissue between the natural ostium and the surgical ostium was identified.