

Therapeutic emergency laparoscopy for small bowel obstruction secondary to a congenital peritoneal band

Introduction

Patients with small bowel obstruction are frequently seen on the acute surgical take, presenting with vomiting, constipation, abdominal distension and colicky abdominal pain. Common causes include postoperative adhesions and incarcerated hernias. Congenital peritoneal bands are a rare cause of small bowel obstruction in adults.

This article reports a case of small bowel obstruction which presented atypically and was clinically and radiologically of unclear aetiology. Diagnostic laparoscopy identified a congenital peritoneal band in an unusual location, between the anterior abdominal wall and proximal ileum. The authors discuss the approach to the diagnostic uncertainty and management decisions, and the therapeutic use of laparoscopy in this case.

Discussion

Congenital peritoneal bands arise during embryogenesis caused by abnormal adhesion of peritoneal folds, possibly resulting from infective or ischaemic events (Yang et al, 2016). Owing to their congenital nature, they usually present in childhood, and thus only a few

Devika Arambepola¹

Hannah Blades²

Rakesh Sinha³

Diwakar Sarma¹

Author details can be found at the end of this article

Correspondence to:

Devika Arambepola;

d.arambepola@hotmail.com

Case report

A 51-year-old man with no surgical history presented with a 1-day history of vomiting and epigastric pain radiating to the back, with no change in bowel habit. His abdomen was soft with mild epigastric discomfort on palpation. Blood tests were normal, including full blood count, electrolytes, liver function and amylase level. Abdominal ultrasonography showed a thin-walled gallbladder containing a 5 mm calculus. On review the patient's symptoms had resolved. He was diagnosed with biliary colic and listed for elective cholecystectomy.

The patient re-presented 3 days later with absolute constipation since discharge and worsening vomiting. His abdomen was distended but soft and non-tender. Plain abdominal X-ray revealed a dilated bowel loop. Computed tomography examination with intravenous contrast showed small bowel obstruction with a transition point in the right lumbar region but no clear aetiology.

Conservative management with nasogastric decompression and intravenous fluids was trialled. However, the symptoms worsened so computed tomography was repeated, which again demonstrated obstruction with the same transition point. On review by a specialist gastrointestinal radiologist, underlying malrotation was suggested, because the third part of the duodenum and the duodenojejunal flexure were twisted and located to the right of the mesenteric vessels (**Figure 1a**), causing marked gastric and proximal duodenal distension. Unusually, there was also marked jejunal distension on the left side of the abdomen and collapsed loops of distal ileum (**Figures 1b** and **c**). The possibility of partial malrotation coexistent with congenital bands and internal hernias was raised. After discussing management options with the patient, the decision was made to proceed to diagnostic laparoscopy.

Laparoscopy on day three of admission identified a single band of fibrous tissue extending from the anterior abdominal wall in the right upper quadrant to the proximal ileum (**Figure 2**). The small bowel was rotated around this band causing obstruction. The duodenum, jejunum, ileum and caecum were in the normal anatomical position, thus defining normal rotation. The band was taken down with sharp dissection.

The patient progressed well and was discharged 3 days later when passing flatus and tolerating an oral diet.

How to cite this article:

Arambepola D, Blades H, Sinha R, Sarma D.

Therapeutic emergency laparoscopy for small bowel obstruction secondary to a congenital peritoneal band.

Br J Hosp Med. 2022.

<https://doi.org/10.12968/hmed.2021.0505>

hmed.2021.0505

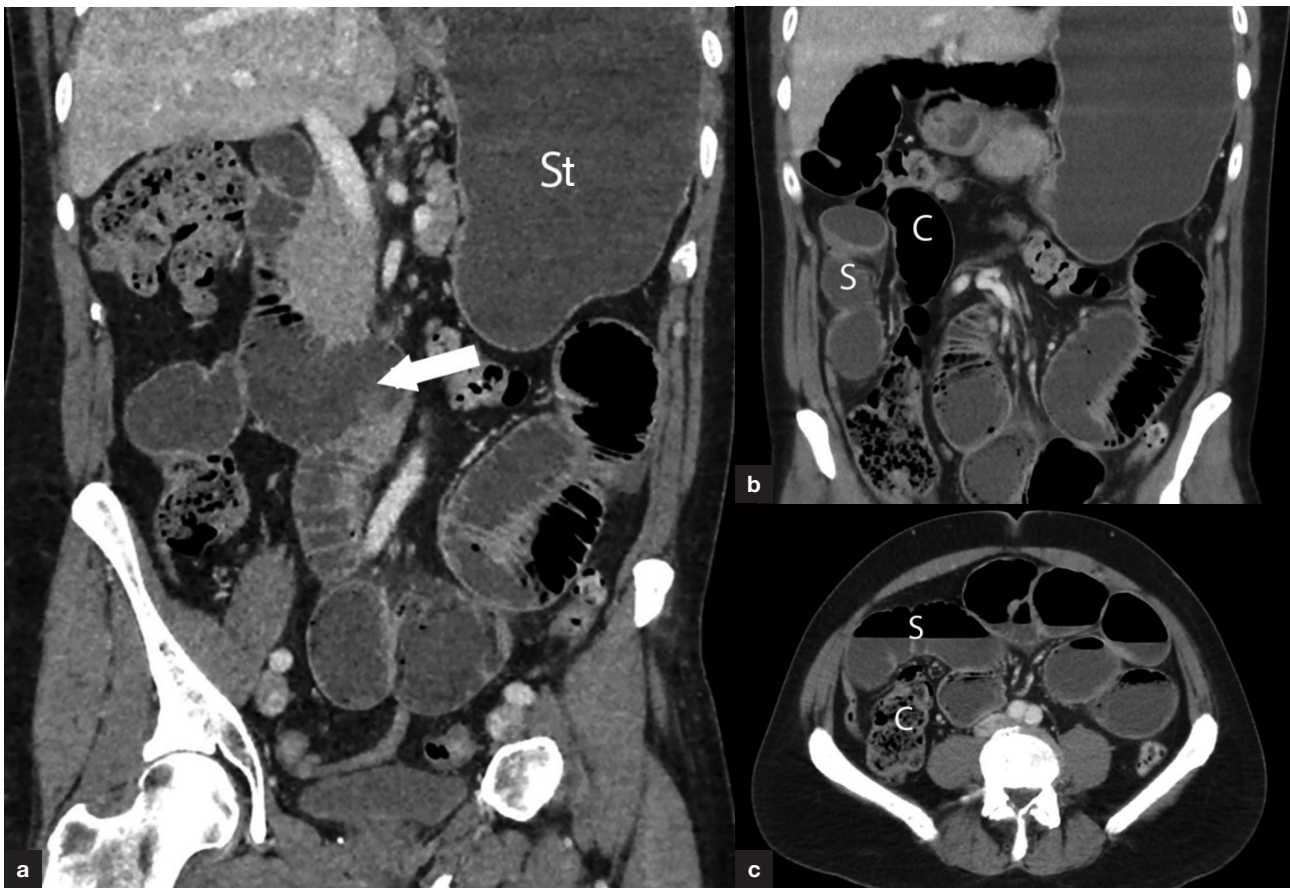


Figure 1. Computed tomography images. a. The third part of the duodenum is twisted and lies on the right side (arrow). Note distended stomach (St). b and c. Dilated small bowel (S) lies lateral to the ascending colon (C), with twisted mesenteric vessels.

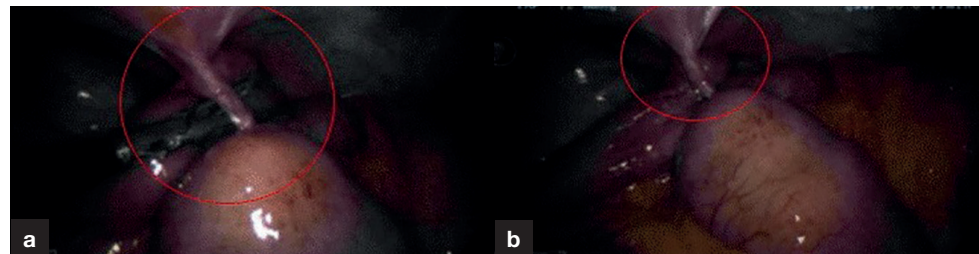

Figure 2. Intraoperative images showing a single fibrous band (circled) between the anterior abdominal wall and proximal ileum.

cases are reported in adulthood. Most of these presented in early adulthood, with very few cases in individuals as old as this patient (Sozen et al, 2012; Nicolas et al, 2016).

Small bowel obstruction was not diagnosed in this patient until his second presentation. His initial symptomatology was consistent with biliary pathology: acute onset, colicky, epigastric pain, vomiting and spontaneous resolution, with no change in bowel habit. Normal blood results and ultrasound confirmation of a gallstone further supported this diagnosis. However, in retrospect, it appears that the ultrasound finding was incidental rather than explanatory for his presentation.

The atypical nature of his presentation may be related to the unusual location of the band in the right upper quadrant. Although congenital peritoneal bands have been found in a number of intra-abdominal locations, none similar to this have been reported (Kerkeni et al, 2020). It is exceedingly unusual to find a congenital band between the abdominal wall and the intestine, with the exception of Ladd's bands in patients with intestinal malrotation. The authors suggest that the location of the band combined with the gross dilatation of the small bowel led to the radiological suggestion of intestinal malrotation, which was no longer evident once the bowel was decompressed.

Learning points

- Although rare, adhesional bands should not be ruled out as a cause of small bowel obstruction in a virgin abdomen.
- Congenital peritoneal bands may not be clearly identified radiologically, especially in the presence of gross dilatation and resultant anatomical distortion.
- Laparoscopy is a safe and appropriate surgical intervention for congenital peritoneal bands.

In this case, laparoscopy proved a useful tool for both diagnostic and therapeutic purposes. The authors were able to identify the cause of obstruction, assess the viability of the obstructed bowel and perform simple adhesiolysis without need for more invasive open surgery, thus leading to timely patient recovery.

Author details

¹Department of General Surgery, South Warwickshire NHS Foundation Trust, Warwick, UK

²Acute Care Unit, Homerton University Hospital Foundation Trust, London, UK

³Department of Radiology, South Warwickshire NHS Foundation Trust, Warwick, UK

References

- Kerkeni Y, Aicha B, Hamzaoui M. Idiopathic congenital anomalous bands: about ten cases with systematic review of the literature. *Int J Pediatr Adolesc Med.* 2020;7(4):157–160. <https://doi.org/10.1016/j.ijpam.2020.03.006>
- Nicolas G, Kfoury T, Shimlati R et al. Diagnosis and treatment of small bowel strangulation due to congenital band: three cases of congenital band in adults lacking a history of trauma or surgery. *Am J Case Rep.* 2016;17:712–719. <https://doi.org/10.12659/AJCR.899664>
- Sozen S, Emir S, Yazar FM et al. Small bowel obstruction due to anomalous congenital peritoneal bands - case series in adults. *Bratisl Lek Listy.* 2012;113(3):186–189. https://doi.org/10.4149/blil_2012_043
- Yang K-H, Lee T-B, Lee S-H et al. Congenital adhesion band causing small bowel obstruction: what's the difference in various age groups, pediatric and adult patients? *BMC Surg.* 2016;16(1):79. <https://doi.org/10.1186/s12893-016-0196-4>