

## Without a leg to stand on: a case of anterior cerebral artery infarction

Asha Bissessar<sup>1</sup>

Aravinth Sivagnanaratnam<sup>1</sup>

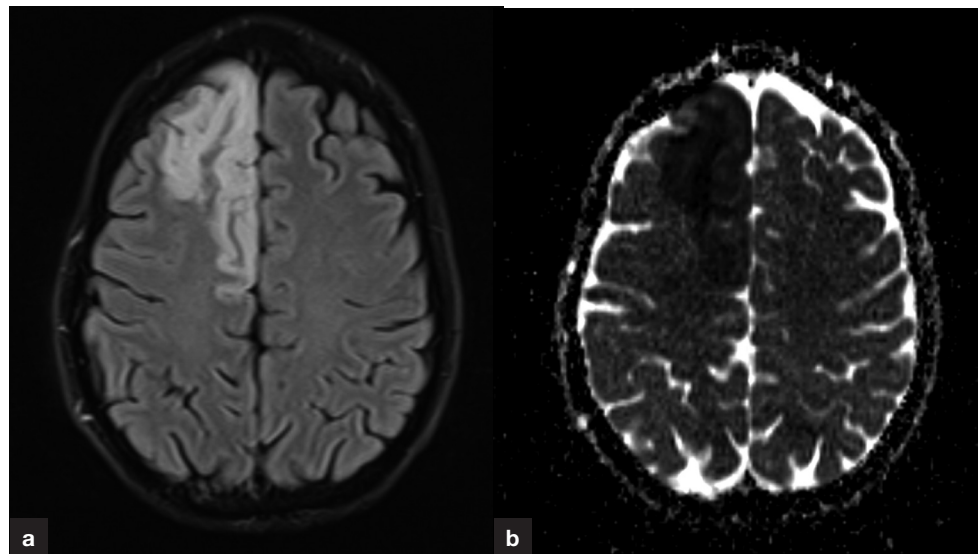
Author details can be found  
at the end of this article

Correspondence to:

Asha Bissessar;  
a.bissessar@nhs.net

A 50-year-old man presented with sudden onset left-sided weakness and numbness. Computed tomography of the brain and computed tomography angiogram were unremarkable. Despite thrombolysis, the weakness of the patient's left leg persisted.

Subsequent magnetic resonance imaging of the brain (**Figures 1a** and **b**) showed an acute right anterior cerebral artery territory infarct.



**Figure 1.** a. Diffusion-weighted magnetic resonance imaging sequence showing restricted diffusion in the right anterior cerebral artery territory. b. Magnetic resonance imaging apparent diffusion coefficient sequence confirming ischaemic changes.

Anterior cerebral artery strokes comprise approximately 2% of ischaemic strokes (Kang and Kim, 2008), likely secondary to the strong complex of anastomoses within this artery. Anterior cerebral artery infarcts commonly result in contralateral hemiplegia, predominantly affecting the leg (Banker and Prasanna, 2021) since it supplies the medial aspect of the cerebral hemispheres.

Stroke is a clinical diagnosis as ischaemia takes time to be revealed on computed tomography. After excluding radiological and other contraindications, patients with a normal computed tomography scan often receive thrombolysis. When paired with apparent diffusion coefficient images, diffusion-weighted magnetic resonance imaging usually confirms an acute infarct if performed within 14 days of the clinical event.

It is important that anterior cerebral artery infarction is recognised early to allow optimal treatment and improve patient outcomes.

### Author details

<sup>1</sup>Stroke Unit, Northwick Park Hospital, London, UK

### How to cite this article:

Bissessar A, Sivagnanaratnam A. Without a leg to stand on: a case of anterior cerebral artery infarction. *Br J Hosp Med.* 2022. <https://doi.org/10.12968/hmed.2021.0521>

### References

- Banker L, Tadi P. Neuroanatomy, Precentral Gyrus. In: StatPearls. Treasure Island (FL): StatPearls Publishing; 2021
- Kang SY, Kim JS. Anterior cerebral artery infarction: stroke mechanism and clinical-imaging study in 100 patients. *Neurology.* 2008;70(24 Pt 2):2386–2393. <https://doi.org/10.1212/01.wnl.0000314686.94007.d0>