

Complicated peritonsillar abscess extending into the buccal space: an unusual clinical presentation

Mohamed Amin¹

Guled M Jama¹

Usama Ahmed¹

Avril Horsburgh²

Amro Hassaan¹

Author details can be found at the end of this article

Correspondence to:

Mohamed Amin;

Mohamed.amin@nhs.net

Introduction

A peritonsillar abscess usually results from an episode of acute tonsillitis (Hur et al, 2018). As the infection progresses into a collection, it may extend inferiorly, leading to a deep neck abscess. This article reports an unusual case of a patient who presented with a peritonsillar abscess extending anteriorly to involve the buccal space.

Discussion

The cervical fascia is divided broadly into superficial and multiple deep layers that divide the neck into multiple named spaces. The buccal space is a small potential ovoid space

Case report

A 72-year-old woman presented to the emergency department with a 3-day history of worsening sore throat, odynophagia and reduced oral intake. She had predominantly left-sided symptoms that had developed gradually and were accompanied by fever.

On examination, she had mild trismus. There was evidence of a left-sided peritonsillar swelling with associated uvular deviation to the contralateral side. Her vital signs were within normal ranges. Initial blood tests revealed a white blood cell count of $16.0 \times 10^9/\text{litre}$ (normal range $4.5\text{--}11.0 \times 10^9/\text{litre}$) and a C-reactive protein level of 46 mg/litre (normal range $<5 \text{ mg/litre}$).

She was commenced on intravenous clarithromycin 500 mg twice daily, metronidazole 500 mg three times a day, dexamethasone 8 mg three times a day, fluids and analgesia. Needle aspiration of the abscess was performed, and pus sent for microbiology culture. Within a day, her symptoms had markedly improved and she was able to eat and drink without difficulty. Her inflammatory markers also continued to improve, and she remained clinically well. She was discharged from hospital a day after her admission on a course of oral antibiotics and analgesia.

She re-presented to the emergency department 2 days later. She reported worsening symptoms of sore throat, 'hot potato' voice change, trismus and a new-onset left-sided cheek swelling. On examination, there was a visible, large, diffuse, erythematous and fluctuant swelling overlying her left cheek. Oropharyngeal examination revealed a recurrent left peritonsillar swelling with a deviated uvula to the right (Figure 1). There were no signs of dental infection or periapical abscess. Repeat white cell count was $24.0 \times 10^9/\text{litre}$ with a C-reactive protein level of 53 mg/dl. Microbiology from her first presentation revealed heavy growth of *Candida albicans* and scanty growth of *Streptococcus mitis*. She was readmitted and commenced on intravenous clarithromycin 500 mg twice daily, metronidazole 500 mg three times a day, dexamethasone 8 mg three times a day and oral analgesics.

Magnetic resonance imaging scan of the neck with contrast revealed a large heterogeneously rim-enhancing and loculated appearing lesion involving the left peritonsillar space. It appeared to be extending through the left retromolar trigone into the masseter muscles and the soft tissues of the cheek within the buccal space with significant oedema of the overlying cheek subcutaneous tissues (Figure 2).

Intraoral surgical drainage of the abscess was carried out under local anaesthesia. A 2.5 cm long oblique incision was placed in the left peritonsillar area followed by a similarly sized horizontal incision along the left buccal mucosa at the maximal point of fluctuance. She continued to be treated in hospital and her symptoms continued to improve. Neck ultrasound 2 days later showed no significant collection. Three days after surgical drainage, she was fit to be discharged from hospital on a course of oral antibiotics with no recurrence of collection thereafter.

How to cite this article:

Amin M, Jama GM, Ahmed U, Horsburgh A, Hassaan A. Complicated peritonsillar abscess extending into the buccal space: an unusual clinical presentation. Br J Hosp Med. 2022. <https://doi.org/10.12968/hmed.2021.0591>

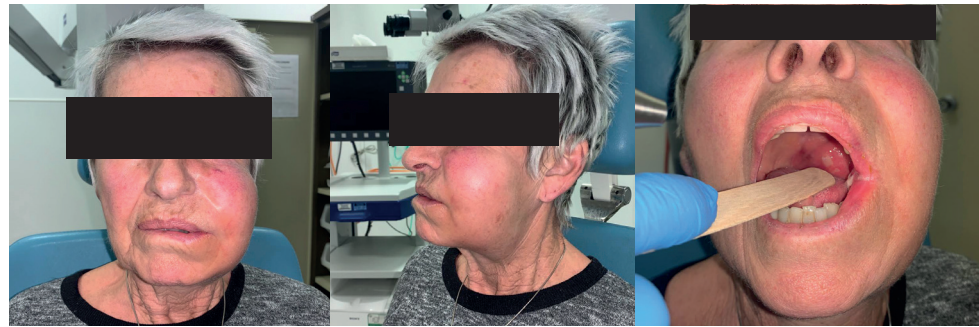

Figure 1. Clinical photographs demonstrating left peritonsillar abscess and buccal swelling.

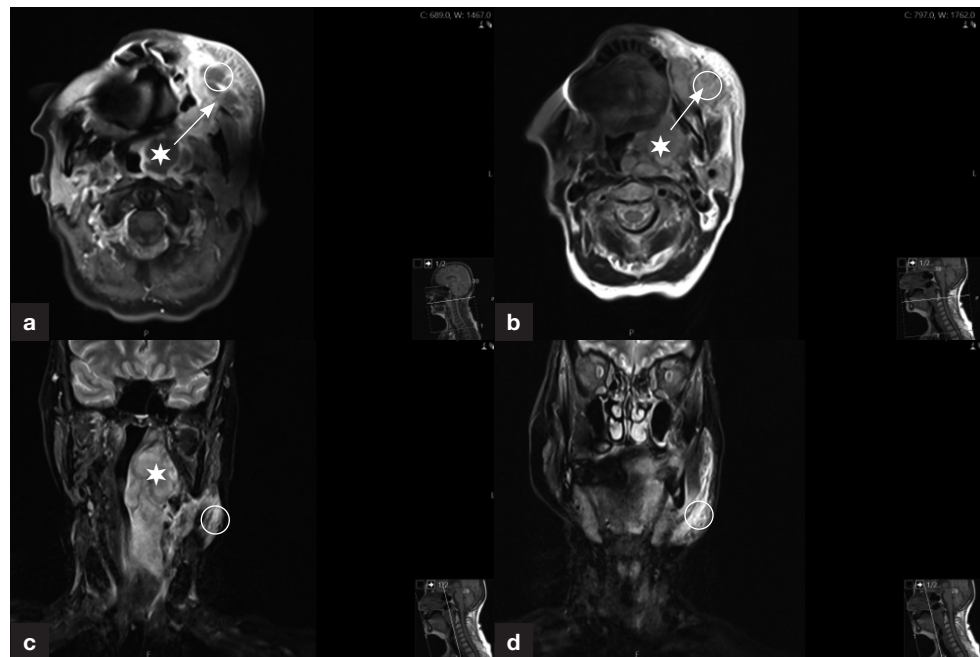


Figure 2. Magnetic resonance imaging scan with gadolinium enhancement showing a large, heterogeneous, rim-enhancing collection involving the left peritonsillar and retropharyngeal space extending anteriorly through the left retromolar trigone into the masseter space and inferiorly into the hypopharynx. a. Magnetic resonance imaging axial short-T1 inversion recovery (STIR) with contrast. b. Magnetic resonance imaging axial T2 images. c. Magnetic resonance imaging coronal T1 STIR. d. Magnetic resonance imaging coronal T1 STIR. Star=left peritonsillar abscess; arrow=direction of infection; circle=buccal abscess.

located anatomically between the skin and subcutaneous tissue laterally, buccinator muscles medially, and lying anterior to the ramus of the mandible, masseter and pterygoid muscles (Iwanaga et al, 2020).

Buccal space infections usually arise from periapical infection in one of three maxillary molars, presenting as cheek oedema, and buccal infection does not cause trismus, unless there is infection in another space (Brook, 2004).

By contrast, peritonsillar abscesses are mainly consequences of tonsillitis or pharyngitis resulting from the location lateral to the tonsillar capsule and medial to superior constrictor muscle. Peritonsillar abscesses extend usually to parapharyngeal and retropharyngeal spaces. Nevertheless, three prior cases are documented before with unusual extension to the masticator space (Hidaka et al, 2013; 2014). In the present case, the peritonsillar abscess extended to the masticator space and beyond to the buccal space. The masticator space contains muscles of mastication with four subspaces in between and is connected to the buccal space (Iwanaga et al, 2020).

It is considered unusual in the context of buccal space infection originating from peritonsillar abscess, without evidence of odontogenic source on panoramic dental radiograph (Figure 3).

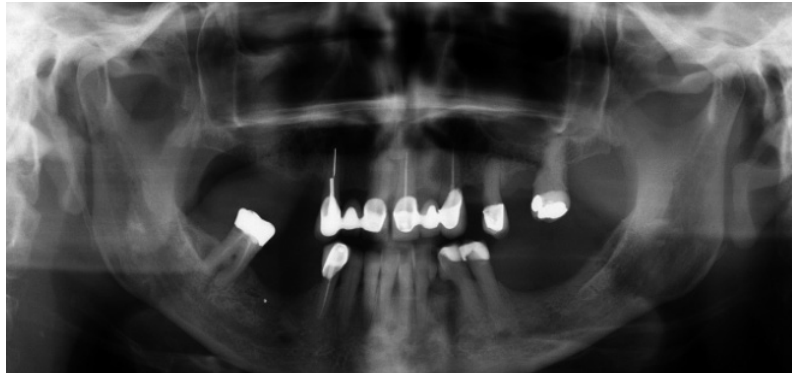

Figure 3. Orthopantomogram showing no evidence of dental infection or collection.

The patient presented the second time with cheek swelling, which suggested an odontogenic infection. Therefore, magnetic resonance imaging was preferred to computed tomography, contrary to usual management of neck abscess, to better evaluate the fascial spaces and oral muscles.

Conclusions

Buccal space infections are usually odontogenic in aetiology. However, in the absence of dental infection, early sectional imaging should be considered as peri-tonsillar abscesses can occasionally extend to the buccal space. Early senior review and multidisciplinary involvement of maxillofacial and otolaryngology surgeons are recommended, particularly in complex cases.

Author details

¹Department of Otolaryngology, Queen's Hospital, Barking, Havering and Redbridge University Hospitals NHS Trust, Romford, UK

²Department of Radiology, Queen's Hospital, Barking, Havering and Redbridge University Hospitals NHS Trust, Romford, UK

References

- Brook I. Microbiology and management of peritonsillar, retropharyngeal, and parapharyngeal abscesses. *J Oral Maxillofac Surg.* 2004;62(12):1545–1550. <https://doi.org/10.1016/j.joms.2003.12.043>
- Hidaka H, Suzuki T, Ishida E, Kakuta R, Yano H. Unique extension of peritonsillar abscess to the masticator space encountered in the early phase of antiviral therapy for hepatitis C. *Clin Microbiol.* 2013;2(5):1–4. <https://doi.org/10.4172/2327-5073.1000117>
- Hidaka H, Ishida E, Suzuki T et al. Unusual parapharyngeal extension of peritonsillar abscess to the masticator space: successfully drained by extraoral and intraoral endoscopic approaches. *Ann Otol Rhinol Laryngol.* 2014;123(5):333–337. <https://doi.org/10.1177/0003489414526360>
- Hur K, Zhou S, Kysh L. Adjunct steroids in the treatment of peritonsillar abscess: a systematic review. *Laryngoscope.* 2018;128(1):72–77. <https://doi.org/10.1002/lary.26672>
- Iwanaga J, Watanabe K, Anand MK, Tubbs RS. Air dissection of the spaces of the head and neck: a new teaching and dissection method. *Clin Anat.* 2020;33(2):207–213. <https://doi.org/10.1002/ca.23454>

Learning points

- Recurrent peritonsillar abscess should be treated carefully because of its deep extension and recollection, which needs sectional imaging.
- Buccal space infection might be an extension of peritonsillar abscess, not necessarily related to dental causes.
- Clinicians should be aware of neck spaces and their potential connection to facial spaces.