

# A rare cause of unilateral opaque lung: giant primary myxoid spindle cell liposarcoma

Veysel Ayyildiz<sup>1</sup>

Ali Koksal<sup>2,3</sup>

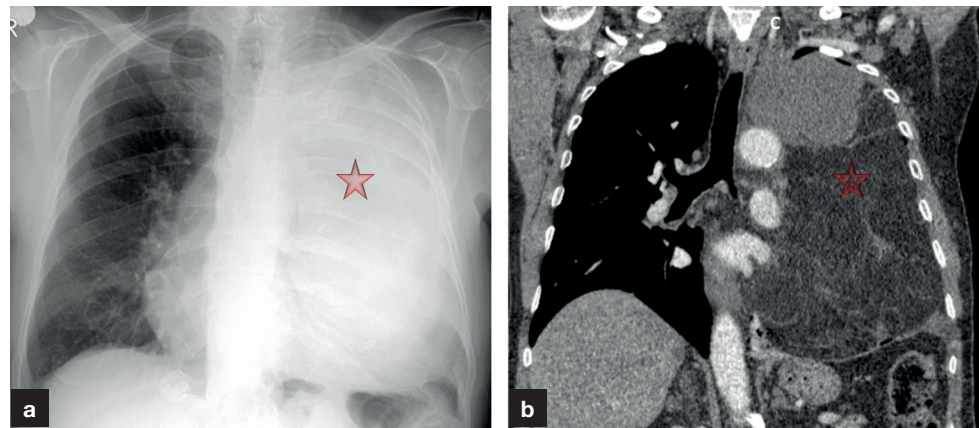
Yener Aydin<sup>4,5</sup>

Hayri Ogul<sup>5,6</sup>

Author details can be found  
at the end of this article

Correspondence to:  
Hayri Ogul;  
drhogul@gmail.com

A 72-year-old man presented with chest pain that had been increasing for 6 months. On X-ray, his left lung was completely radio-opaque (**Figure 1a**). Computed tomography scan showed a giant lipomatous mass in the left hemithorax (**Figure 1b**). Following histopathology of this mass, the patient was diagnosed with spindle cell liposarcoma.



**Figure 1.** a. Posterior-anterior chest radiography reveals left hemiopaque lung (asterisk). b. Coronal computed tomography scan shows a giant lipomatous mass (asterisk) in the left hemithorax.

Primary pulmonary myxoid spindle cell liposarcoma is a very rare low-grade malignant sarcoma. The aetiology and prognostic factors of the tumour have not been clearly revealed. It is mostly diagnosed in smokers and patients over the age of 65 years (Doğan et al, 2017). Primary pulmonary myxoid spindle cell liposarcoma has a very aggressive course, and the 5-year survival rate does not exceed 20% (Doğan et al, 2017). Owing to the rarity and poor prognosis of primary pulmonary myxoid spindle cell liposarcoma, its clinical and pathological features have not been fully elucidated. Larger case series on these rare tumours are needed to determine clinical, radiological and effective treatment.

## Author details

<sup>1</sup>Department of Radiology, Medical Faculty, Suleyman Demirel University, Isparta, Turkey

<sup>2</sup>Department of Radiology, Ankara Bayindir Private Hospital, Ankara, Turkey

<sup>3</sup>Department of Radiology, Vocational School of Health Services, Atılım University, Ankara, Turkey

<sup>4</sup>Department of Thoracic Surgery, Medical Faculty, Ataturk University, Erzurum, Turkey

<sup>5</sup>Anesthesiology Clinical Research Office, Ataturk University, Erzurum, Turkey

<sup>6</sup>Department of Radiology, Medical Faculty, Duzce University, Duzce, Turkey

## Reference

Doğan C, Şener Cömert S, Çağlayan B et al. A rare tumor of the lung: sarcomatoid carcinoma. *South Clin Ist Euras*. 2017;28(2):135–138. <https://doi.org/10.14744/scie.2017.27482>

## How to cite this article:

Ayyildiz V, Koksal A, Aydin Y, Ogul H. A rare cause of unilateral opaque lung: giant primary myxoid spindle cell liposarcoma. *Br J Hosp Med*. 2022. <https://doi.org/10.12968/hmed.2021.0662>