

Multisystem involvement in COVID-19: what have we learnt?

Abstract

The COVID-19 illness trajectory involves persistent cardio-renal inflammation, activation of the haemostatic pathway and lung involvement. Results of a study carried out by the authors' team demonstrate a link between post-COVID-19 syndrome (people who have long COVID) and multisystem disease, which partly explains the lingering impairments in patient-reported health-related quality of life, physical function and psychological wellbeing after COVID-19. This article discusses what hospital physicians need to be aware of when considering the likelihood of myocarditis in patients with post-COVID-19 syndrome and the implications in the longer term.

Key words: COVID-19; Multi-system involvement; Myocardial inflammation; Myocarditis; Post-COVID-19 syndrome; SARS-CoV-2

Submitted: 17 June 2022; accepted following double-blind peer review: 21 June 2022

Kenneth Mangion^{1,2,3}

Colin Berry^{1,2,3}

Author details can be found at the end of this article

Correspondence to:

Colin Berry;
colin.berry@glasgow.ac.uk

Introduction

Since the first reported case of severe acute respiratory syndrome coronavirus 2 (SARS-CoV-2) in humans there has been an evolving evidence base around the multiorgan involvement in COVID-19 (Gupta et al, 2020) and persisting symptoms in the longer term. The pathogenesis of multiorgan inflammation in COVID-19 may involve direct virus toxicity (Puelles et al, 2020; Sungnak et al, 2020), endothelial dysfunction (Guzik et al, 2020), thrombotic microvascular angiopathy (Varga et al, 2020), immune system dysregulation (Cummings et al, 2020; Ruan et al, 2020) or dysregulation of the renin-angiotensin-aldosterone system (Guzik et al, 2020).

The authors' team (Pellicori et al, 2021) carried out a review of observational studies and registries published between December 2019 and July 2020 investigating the nature and rate of cardiovascular complications in people with COVID-19. In hospitalised patients, the most common cardiovascular complications were arrhythmias (weighted mean incidence 9%), heart failure (weighted mean incidence 7%) and thromboembolic complications (weighted mean incidence 7%). A limitation is that most of the studies included in this review were retrospective, making them highly susceptible to reporting bias.

A multi-system, multi-modality investigation of post-COVID-19 illness

The authors designed a prospective, cohort study within the Greater Glasgow and Clyde region (population served >1.1 million) (Mangion et al, 2020) to investigate the incidence, nature and clinical significance of cardiovascular involvement in patients with COVID-19. The setting involved two large academic centres and a district general hospital. Hospitalised patients >18 years of age with a polymerase chain reaction diagnosis of COVID-19 were screened, with minimal exclusion criteria (inability to provide informed consent or undertake study procedures, for example contraindication to magnetic resonance imaging). The study procedures are explained in detail elsewhere (Mangion et al, 2020). In brief, the published study involved a first visit (in one of the three hospitals or shortly after discharge) where clinical information, electrocardiogram, blood and urine biomarkers and patient-reported outcome measures were acquired. The second visit was carried out 28–60 days post discharge at a dedicated research imaging centre. Besides gathering similar data to those collected during the first visit, chest computed tomography including pulmonary

Distributed under Creative Commons CC BY 4.0

OPEN ACCESS

How to cite this article:

Mangion K, Berry C. Multisystem involvement in COVID-19: what have we learnt? *Br J Hosp Med.* 2022. <https://doi.org/10.12968/hmed.2022.0290>

and coronary angiography and cardio-renal magnetic resonance imaging were acquired. A contemporary control group of at least 20 individuals (controls) who were negative for COVID-19 by polymerase chain reaction and IgG were matched to the characteristics of the participants with COVID-19 and enrolled. These were matched for age, sex, ethnicity and cardiovascular risk factors.

Results

A total of 159 participants were recruited who had been admitted for hospital treatment for COVID-19 between 22 May 2020 and 16 March 2021 and 29 matched control patients (Morrow et al, 2022). Of the participants, 139 (87%) were white, and 69 (43%) were women. Fourteen (19%) patients required invasive ventilation, 31 (20%) received non-invasive ventilation and 109 (69%) required oxygen. Thirty-six (23%) were healthcare workers. To reduce bias, a panel ($n=5$ per participant) of consultant cardiologists independent of the research team was asked to independently adjudicate the likelihood of myocarditis (very likely/probable/unlikely/not present) and the aetiology of myocarditis based on the European Society of Cardiology Working Group on Myocardial and Pericardial Disease position statement on myocarditis (Caforio et al, 2013) and modified Lake Louise diagnostic criteria for myocarditis using magnetic resonance imaging (Ferreira et al, 2018).

Electrocardiogram findings

Participants adjudicated to very likely or probably have myocarditis secondary to COVID-19 infection had electrocardiogram changes suggestive of myopericarditis (the changes may be specific for myocarditis, eg concave ST-elevation, or non-specific, eg ventricular arrhythmias, heart block, ectopy or intraventricular conduction delay (Caforio et al, 2013; Morrow et al, 2022)). Thus, the authors would suggest that hospital doctors review the clinical history (chest pain or palpitations) together with the electrocardiogram in patients hospitalised with COVID-19 illness to consider myocarditis in the differential diagnosis.

Computed tomography findings

Pulmonary ground glass opacity and/or consolidation ($n=70$, 45%), and reticulation or architectural distortion ($n=47$, 30%) were common at 28–60 days post discharge. Twenty-one (14%) patients had obstructive coronary artery disease and five (3%) had evidence of pulmonary thromboembolism (Morrow et al, 2022). These findings were associated with persisting reported breathlessness on exertion in patients attending hospital or clinic 4–8 weeks after COVID-19 pneumonitis.

Magnetic resonance imaging findings

While biventricular function was on average within the normal range, participants with COVID-19 had lower ejection fractions and increased left ventricular volumes when compared with patient controls. Findings consistent with myocardial inflammation in suspected myocarditis include evidence of high T2 (oedema) on T2-weighted imaging on magnetic resonance imaging (T2 mapping, T2 prepared sequences) and high T1 (oedema, inflammation) or scar on T1-weighted imaging (T1 mapping, extracellular volume fraction, early and late gadolinium enhancement) (Figure 1). These are conventionally known as the modified Lake Louise criteria (Ferreira et al, 2018). When requesting a cardiac magnetic resonance imaging exam, the authors would recommend providing adequate clinical information on the request form, to ensure that the cardiologist or radiologist protocolising the exam ensures the right sequences are acquired. Of note, myocardial T2 values can be raised as a result of myocardial infarction (Mangion et al, 2016), T1 values can be raised as a result of diffuse fibrosis such as in hypertensive heart disease or amyloidosis (Taylor et al, 2016), and scar may be present on late gadolinium imaging in cases of myocardial infarction and in certain cardiomyopathies.

Biomarkers

Raised circulating concentrations of several serum biomarkers were observed both during the acute phase of COVID-19 illness and in the longer term. Circulating concentrations of

C-reactive protein, ferritin, D-dimers, fibrinogen, factor VIII and von Willebrand factor were higher in the post-COVID-19 group at enrolment compared to the control group, consistent with activation of the haemostatic pathway. At 28–60 days post-discharge, the

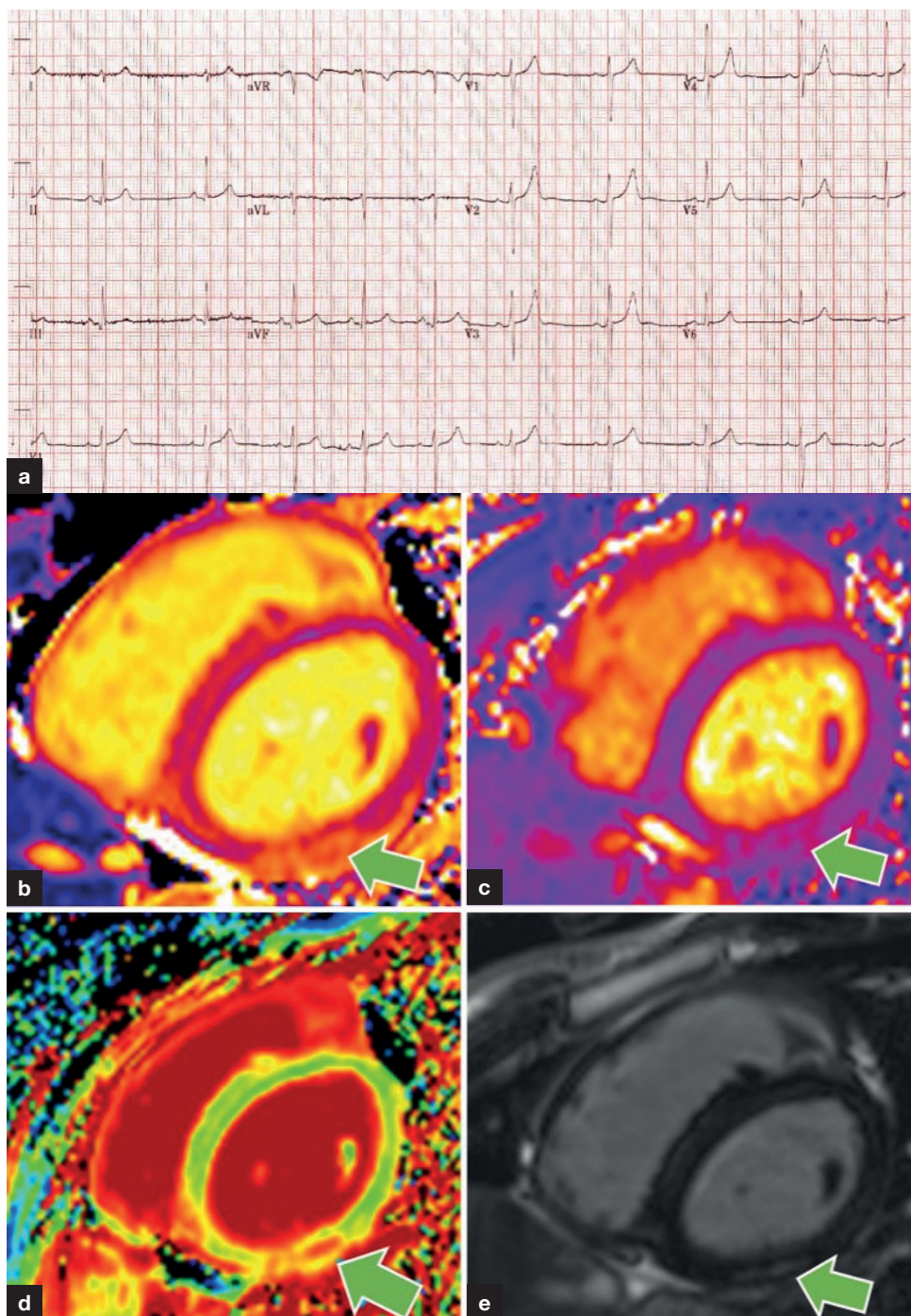


Figure 1. A 19-year-old male non-smoker with no past medical history presented with chest pain and dyspnoea on the background of a recent polymerase chain reaction-positive test for SARS-CoV-2. He described central chest pain radiating to his left arm and jaw lasting approximately 90 minutes. a. A 12-lead electrocardiogram revealed saddle-shaped ST-elevation in the precordial leads (V1–V4) and the peak high sensitivity troponin-I was 4738 ng/litre. A transthoracic echocardiogram revealed preserved biventricular function. He was enrolled in the study. Research-indicated cardiac magnetic resonance imaging was acquired 28 days after discharge from hospital. In the inferior wall (green arrow), localised, mid-wall elevations in (b) myocardial native T1, (c) T2, (d) extracellular volume fraction indicative of acute myocardial inflammation co-localised with (e) sub-epicardial late gadolinium enhancement indicative of scar. These magnetic resonance imaging changes met the Lake Louise criteria for myocarditis.

Key points

- A prospective study evaluating 159 patients 28–60 days after hospitalisation for COVID-19 revealed increased cardio-renal inflammation, reduced lung function and poorer self-reported clinical outcomes in patients relative to those in control participants.
- Hospital physicians should have a high level of suspicion of myocarditis in patients presenting with symptoms, electrocardiogram changes and biomarkers suggestive of myocarditis or pericarditis and should consider seeking a cardiology opinion.
- Persisting changes on cross-sectional imaging (computed tomography, magnetic resonance imaging) and serum biomarkers are common.
- Adjudicated likelihood of myocarditis was associated with persisting poorer self-reported outcomes in patients post-COVID-19 infection at 8 weeks.

concentration of factor VIII remained high. Circulating concentrations of N-terminal pro B-type natriuretic peptide (NT-proBNP) were higher in the COVID-19 group at enrolment and 28–60 days post-discharge.

The authors suggest that cardiac biomarkers, notable high sensitivity troponin I and NT-proBNP, be measured in patients with acute or post-COVID-19 syndromes associated with cardiac symptoms and/or an abnormal electrocardiogram, especially if myocarditis is suspected. The authors observed an association between acute kidney injury and adjudicated likelihood of myocarditis (Morrow et al, 2022). Again, physicians should think about the whole clinical picture when considering multi-organ involvement.

Patient-reported outcome measures

The adjudicated likelihood of myocarditis was associated with patient-reported outcome measures at 28–60 days post-discharge, including lower health-related quality of life, enhanced illness perception, enhanced depression score and lower physical activity. This suggests that multisystem injury pathways (cardiac or renal injury, or haemostatic pathway activation) are the mediators of post-COVID-19 syndrome.

Conclusions

The clinical suspicion of cardiac involvement post-COVID-19 should be based on clinical history and electrocardiogram changes. When indicated, further imaging of heart pump function (echocardiogram or cardiac magnetic resonance imaging) and possible myocarditis should be considered (cardiac magnetic resonance imaging) based on clinical findings and serum biomarkers. Most of the authors' population was unvaccinated ($n=148$, 93%), highlighting the potential, protective benefits of vaccination against COVID-19.

Author details

¹British Heart Foundation Glasgow Cardiovascular Research Centre, Institute of Cardiovascular and Medical Sciences, University of Glasgow, Glasgow, UK

²Department of Cardiology, Elizabeth University Hospital, Glasgow, UK

³Department of Cardiology, Regional Heart and Lung Centre, NHS Golden Jubilee, Clydebank, UK

Conflicts of interest

The authors declare that there are no conflicts of interest.

References

Caforio ALP, Pankuweit S, Arbustini E et al. Current state of knowledge on aetiology, diagnosis, management, and therapy of myocarditis: a position statement of the European Society of Cardiology Working Group on Myocardial and Pericardial Diseases. *Eur Heart J*. 2013;34(33):2636–2648. <https://doi.org/10.1093/eurheartj/eh210>

- Cummings MJ, Baldwin MR, Abrams D et al. Epidemiology, clinical course, and outcomes of critically ill adults with COVID-19 in New York City: a prospective cohort study. *Lancet*. 2020;395(10239):1763–1770. [https://doi.org/10.1016/S0140-6736\(20\)31189-2](https://doi.org/10.1016/S0140-6736(20)31189-2)
- Ferreira VM, Schulz-Menger J, Holmvang G et al. Cardiovascular magnetic resonance in nonischemic myocardial inflammation: expert recommendations. *J Am Coll Cardiol*. 2018;72(24):3158–3176. <https://doi.org/10.1016/j.jacc.2018.09.072>
- Gupta A, Madhavan MV, Sehgal K et al. Extrapulmonary manifestations of COVID-19. *Nat Med*. 2020;26(7):1017–1032. <https://doi.org/10.1038/s41591-020-0968-3>
- Guzik TJ, Mohiddin SA, Dimarco A et al. COVID-19 and the cardiovascular system: implications for risk assessment, diagnosis, and treatment options. *Cardiovasc Res*. 2020;116(10):1666–1687. <https://doi.org/10.1093/cvr/cvaa106>
- Mangion K, Corcoran D, Carrick D, Berry C. New perspectives on the role of cardiac magnetic resonance imaging to evaluate myocardial salvage and myocardial hemorrhage after acute reperfused ST-elevation myocardial infarction. *Expert Rev Cardiovasc Ther*. 2016;14(7):843–854. <https://doi.org/10.1586/14779072.2016.1173544>
- Mangion K, Morrow A, Bagot C et al. The Chief Scientist Office Cardiovascular and Pulmonary Imaging in SARS Coronavirus disease-19 (CISCO-19) study. *Cardiovasc Res*. 2020;116(14):2185–2196. <https://doi.org/10.1093/cvr/cvaa209>
- Morrow AJ, Sykes R, McIntosh A et al. A multisystem, cardio-renal investigation of post-COVID-19 illness. *Nat Med*. 2022;28(6):1303–1311. <https://doi.org/10.1038/s41591-022-01837-9>
- Pellicori P, Doolub G, Wong CM et al. COVID-19 and its cardiovascular effects: a systematic review of prevalence studies. *Cochrane Database Syst Rev*. 2021;(3):CD013879. <https://doi.org/10.1002/14651858.cd013879>
- Puelles VG, Lütgehetmann M, Lindenmeyer MT et al. Multiorgan and Renal Tropism of SARS-CoV-2. *N Engl J Med*. 2020;383(6):590–592. <https://doi.org/10.1056/NEJMc2011400>
- Ruan Q, Yang K, Wang W, Jiang L, Song J. Clinical predictors of mortality due to COVID-19 based on an analysis of data of 150 patients from Wuhan, China. *Intensive Care Med*. 2020;46(5):846–848. <https://doi.org/10.1007/s00134-020-05991-x>
- Sungnak W, Huang N, Bécavin C et al. SARS-CoV-2 entry factors are highly expressed in nasal epithelial cells together with innate immune genes. *Nat Med*. 2020;26(5):681–687. <https://doi.org/10.1038/s41591-020-0868-6>
- Taylor AJ, Salerno M, Dharmakumar R, Jerosch-Herold M. T1 mapping: basic techniques and clinical applications. *JACC Cardiovasc Imaging*. 2016;9(1):67–81. <https://doi.org/10.1016/j.jcmg.2015.11.005>
- Varga Z, Flammer AJ, Steiger P et al. Endothelial cell infection and endotheliitis in COVID-19. *Lancet*. 2020;395(10234):1417–1418. [https://doi.org/10.1016/S0140-6736\(20\)30937-5](https://doi.org/10.1016/S0140-6736(20)30937-5)