

Infrapatellar ganglion cyst extending under the skin through a defect in the lateral patellar retinaculum

Introduction

Cystic structures are common around the knee joint, and most occur around the popliteal fossa (Nikolopoulos et al, 2011). Ganglion cyst is a tumour-like lesion of unknown aetiology that is most commonly seen on the dorsum of the wrist (Saha et al, 2015; Miljko et al, 2019). Intra-articular ganglion cysts of the knee joint are rare. These cysts are usually found incidentally on magnetic resonance imaging or arthroscopic examination (Krudwig et al, 2004).

The lateral retinaculum of the knee consists of various fascial layers on the anterolateral aspect of the joint (Merican and Amis, 2008). Kim et al (2017) reported detecting 26% of existing defects on magnetic resonance imaging, while Moraux et al (2019) reported finding defects in all patients on an ultrasonography study.

Very few ganglion cysts in the knee originate from the infrapatellar fat pad (Miljko et al, 2019). Moraux et al (2019) reported that ganglion cysts originating from the infrapatellar fat pad may present as a palpable mass in the anterior aspect of the knee joint. However, ganglion cyst originating from the infrapatellar fat pad and extending through a retinaculum defect to present subcutaneously are very rare (Saha et al, 2015).

Discussion

Ganglion cyst in the knee joint was first reported by Caan (1924). Ganglion cysts in the knee joint are rare, reported in 0.2–1% of magnetic resonance imaging examinations and around 0.6% on arthroscopy (Nikolopoulos et al, 2011). These may arise from anterior or posterior cruciate ligaments, menisci, popliteal tendon, infrapatellar fat pad or subchondral bone cysts (Saha et al, 2015).

Cystic and cyst-like lesions around the knee joint can be easily visualised on ultrasonography, computed tomography and magnetic resonance imaging. These ‘benign cysts’ include synovial, ganglion, meniscal and intraosseous cysts; ‘cyst-like’ lesions are classified as normal knee bursae, normal knee recesses and various cyst-like lesions (Perdikakis and Skiadas, 2013).

Case report

A 45-year-old male presented to the orthopaedic service with a complaint of swelling that appeared suddenly with a tearing sound coming from the knee following sudden, hard pressing on the ground. His laboratory findings were normal. There was no pain during or after the event. He had previously experienced pain when bending the knee, going up and down stairs, and had consulted a doctor about this.

Tenderness and a 5x3cm swelling in the anterolateral aspect of the knee were detected on examination, and crepitation, varus stress and valgus stress examinations were negative (Figure 1). Magnetic resonance imaging was requested with a preliminary diagnosis of meniscopathy and bursitis. After this was carried out (1 week later), ultrasonography examination was requested and performed by the same radiologist who evaluated the magnetic resonance images.

Magnetic resonance imaging and ultrasonography showed a defect or tear in the lateral patellar retinaculum of the knee. A cystic structure 3.5x2.5x2.5 cm in size, with lobulated contours, extending under the skin through the retinaculum defect, was detected in the infrapatellar adipose tissue (Figures 2a and b). Magnetic resonance imaging also revealed effusion in the knee joint, iliotibial friction, stage 1–2 degeneration in the medial meniscus and a focal tear in the lateral meniscus. The patient was scheduled for surgery. Partial medial meniscectomy and cyst excision were performed under spinal anaesthesia, and pathology revealed this to be a ganglion cyst.

Fatih Çankal^{1,2}

Berin Tuğtağ Demir²

Author details can be found at the end of this article

Correspondence to:

Berin Tuğtağ Demir;
berrintugtag@hotmail.com

How to cite this article:

Çankal F, Tuğtağ Demir B. Infrapatellar ganglion cyst extending under the skin through a defect in the lateral patellar retinaculum. *Br J Hosp Med.* 2024 <https://doi.org/10.12968/hmed.2023.0400>

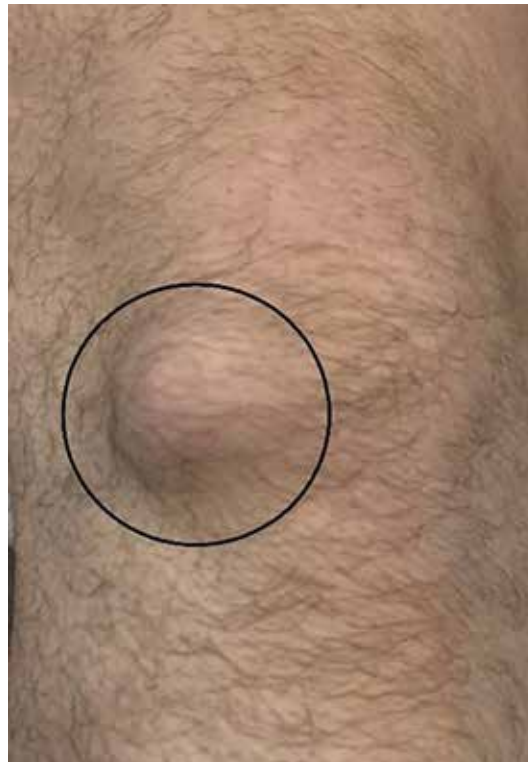

Figure 1. Visible swelling on the lateral knee.

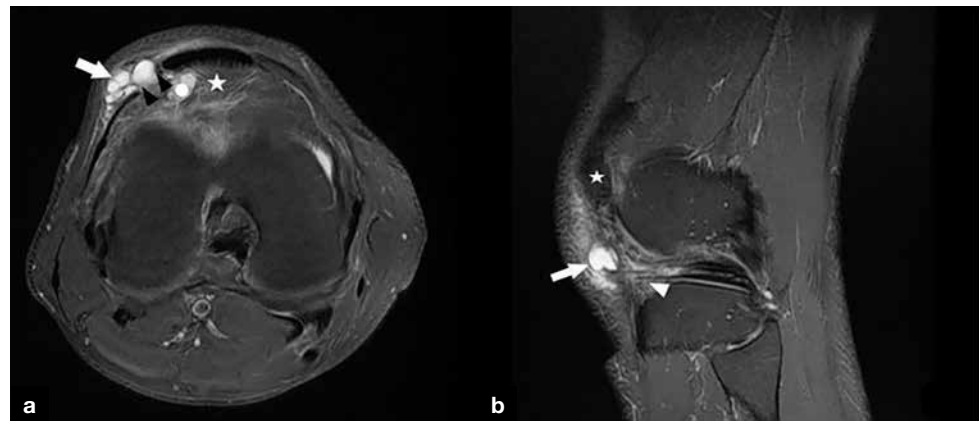


Figure 2. a. Coronal and (b) sagittal magnetic resonance images. White arrow: subcutaneous cyst; white arrowhead: infrapatellar cyst; white star: patella; black arrowheads: patellar retinaculum defect.

A literature review found only three cases of subcutaneous extension of infrapatellar ganglion cysts. One extended from the infrapatellar fat pad to the anterior of the patellar tendon through the defect in the lateral retinaculum and the other two were medial (Saha et al, 2015; Kim et al, 2017), highlighting the rarity of this case. On magnetic resonance imaging, the connection of the cystic structure with the infrapatellar adipose tissue could be easily seen. As in other published cases, this did not cause the patient pain or discomfort. In other cases, serial magnetic resonance imaging examinations were performed as the cystic structure grew over time, but this case has no growth history as the patient presented for the first time.

Conclusions

Ganglion cysts in and around the knee joint may present with clinical findings other than the localisation of origin, as in this case. Understanding the relationship between lateral

Learning points

- Infrapatellar cysts, which are usually located posteriorly and laterally, should be carefully evaluated during magnetic resonance imaging reporting in terms of their close relationship with anterior cruciate ligament lesions and the clinical symptoms that they may cause.
- Infrapatellar ganglion cysts are usually encountered as incidental findings on magnetic resonance imaging or arthroscopic examination.
- Clinical diagnosis of an intra-articular cyst is difficult, but sometimes an infrapatellar fat pad cyst might be suspected as it is invisible and palpable. Magnetic resonance imaging is the best diagnostic option in all cases.

patellar retinaculum defects and pathologies from the infrapatellar fat pad and subcutaneous adipose tissue on magnetic resonance imaging and evaluating the accompanying pathologies the lesion will help clarify its aetiology and assist orthopaedic surgeons during surgery.

Author details

¹Faculty of Medicine, Department of Radiology, Pursaklar Hospital, Ankara, Turkey

²Faculty of Medicine, Department of Anatomy, Ankara Medipol University, Ankara, Turkey

Acknowledgements

This case was presented at the 8th International Symposium of Academic Studies in Health and Sports Sciences, 12 March 2022.

References

- Caan P. Zystenbildung (Ganglion) im Ligamentum cruciatum ant. genus. *Deutsche Zeitschrift f Chirurgie*. 1924;186(5–6):403–408. <https://doi.org/10.1007/BF02810955>
- Kim JS, Yun SJ, Jin W et al. A focal defect at the lateral patellar retinaculum on clinical knee MRI and cadaveric study: a normal variant or pathologic lesion? *AJR Am J Roentgenol*. 2017;208(5):1103–1109. <https://doi.org/10.2214/AJR.16.17034>
- Krudwig WK, Schulte KK, Heinemann C. Intra-articular ganglion cysts of the knee joint: a report of 85 cases and review of the literature. *Knee Surg Sports Traumatol Arthrosc*. 2004;12(2):123–129. <https://doi.org/10.1007/s00167-003-0372-9>
- Merican AM, Amis AA. Anatomy of the lateral retinaculum of the knee. *J Bone Joint Surg Br Vol*. 2008;90-B(4):527–534. <https://doi.org/10.1302/0301-620X.90B4.20085>
- Miljko M, Markotić V, Huseinbegović A et al. Giant infrapatellar ganglion cyst of Hoffa's fat pad. *Eur J Radiol Open*. 2019;6(2):275–280. <https://doi.org/10.1016/j.ejro.2019.07.003>
- Morau A, Bianchi S, Tassery F, Le Corroller T. The lateral patellar retinaculum defect: anatomical study using ultrasound. *Skeletal Radiol*. 2019;48(11):1753–1758. <https://doi.org/10.1007/s00256-019-03209-w>
- Nikolopoulos I, Krinas G, Kipriadis D et al. Large infrapatellar ganglionic cyst of the knee fat pad: a case report and review of the literature. *J Med Case Rep*. 2011;5(1):1–7. <https://doi.org/10.1186/1752-1947-5-351>
- Perdikakis E, Skiadas V. MRI characteristics of cysts and “cyst-like” lesions in and around the knee: what the radiologist needs to know. *Insights Imag*. 2013;4(3):257–272. <https://doi.org/10.1007/s13244-013-0240-1>
- Saha P, Bandyopadhyay U, Mukhopadhyay AS, Kundu S, Mandal S. Ganglion cyst of knee from Hoffa's fat pad protruding anterolaterally through retinacular rent: a case report. *J Orthop Case Rep*. 2015;5(1):69–71. <https://doi.org/10.13107/jocr.2250-0685.313>