

The patient with a painful knee

Abstract

Knee pain encompasses a wide array of differential diagnoses and can often pose a diagnostic challenge, as it can have traumatic or non-traumatic causes. A good clinical history, assessment and anatomical knowledge gives a strong foundation to narrow down the diagnosis, and understanding the correct imaging modality and findings further informs correct and timely management. This article reviews various disease processes including fractures, inflammatory, infective and neoplastic causes, and discusses the assessment and various imaging modalities to aid diagnosis in both primary and secondary care.

Key words: Assessment; Diagnosis; Knee; Orthopaedics; Painful; Radiology

Submitted: 15 November 2023; accepted following double-blind peer review: 27 November 2023

Prashant Bamanian¹

Humza T Osmani²

Philip Robinson³

Stephen McDonnell²

Naeem Ahmed¹

Author details can be found at the end of this article

Correspondence to:

Prashant Bamanian;
prashant.bamanian@nhs.net

Introduction

The knee is the second most common site for musculoskeletal pathology (traumatic and non-traumatic) after the spine (Khan et al, 2020) and constitutes a large proportion of primary and secondary care referrals in the UK (Jones and Rai, 2023). Knee pain is more common in women than men and is associated with obesity, age and previous knee injury. It is a common cause of disability and can have a significant impact on quality of life (Bliddal and Christensen, 2009).

This article reviews various disease processes that present as knee pain, ranging from traumatic to non-traumatic causes including infective, inflammatory and neoplastic processes. It outlines the most appropriate assessment, imaging investigations and findings serving as a basis for timely and accurate management.

Basic anatomy

The knee is a synovial joint, composed of the medial, lateral and patellofemoral compartments. It is a complex hinge, as it also allows anteroposterior, medial–lateral translation and rotational movements (Aweid et al, 2019). A basic understanding of this compartmental anatomy is crucial in diagnosis.

The hyaline articular cartilage reduces friction, and the medial and lateral menisci act as shock absorbers to improve stability and congruence. The joint capsule and synovial lining provide support and lubrication. Medially and laterally the capsule is reinforced by the collateral ligaments. The anterior and posterior cruciate ligaments are often involved in traumatic causes of knee pain. These prevent anterior and posterior subluxation of the tibia on the femur. The suprapatella bursa communicates with the knee joint directly and is an important site of effusion secondary to pathological processes. Several fat pads also contribute to pathology as part of the joint (Aweid et al, 2019; National Institute for Health and Care Excellence, 2022a). The neurovascular structures around the knee are outside the scope of this article.

Assessment

The principles of assessment include a detailed history and examination (Stiell et al, 1995). Key questions when assessing a painful and swollen knee include preceding trauma, recent illnesses, speed of onset of swelling, ability to weight bear, similar presentations and previous presentations or surgeries. Any orthopaedic examination includes ‘look, feel, move’ followed by special tests guided by the suspected underlying pathology (Harris and

How to cite this article:

Bamanian P, Osmani HT, Robinson P, McDonnell S, Ahmed N. The patient with a painful knee. *Br J Hosp Med*. 2024. <https://doi.org/10.12968/hmed.2023.0408>

Table 1. Ottawa knee rules

Radiographs are indicated if there is an acute knee injury and one or more of the following are present:

- Age >55 years
- Isolated patellar tenderness
- Tenderness of the fibular head
- Inability to flex knee to 90°
- Inability to weight bear immediately after the injury and in the emergency department (four steps) regardless of limping

From Hargett et al (2021)

Ali, 2014). However, these can be difficult to perform in the acute setting after a traumatic event because of pain and swelling.

Validated clinical scoring systems, such as the Oxford knee score, can be used to assess knee function and measure treatment outcomes (Stiell et al, 1995). Imaging is important to aid diagnosis, but timing and modality remain unclear. Choice of imaging is also affected by availability of local services and agreed pathways. Guidelines exist to help clinicians identify those who require imaging immediately to rule out acute bony injuries. An example is the Ottawa knee rules, a set of guidelines used to determine the need for radiograph imaging in patients presenting with knee injuries, created as a rapid way to avoid unnecessary imaging (Table 1) (Hargett et al, 2021). Blood tests and imaging should be guided by suspected differentials such as inflammatory markers for septic arthritis. The National Institute for Health and Care Excellence (2022b) also provides guidance on the non-operative (lifestyle modifications, physiotherapy and analgesia, eg non-steroidal anti-inflammatory drugs) and operative management of common knee presentations, if other treatments have failed. Overall, there is emphasis on the importance of a thorough assessment and a conservative approach to management (Stiell et al, 1995; Hargett et al, 2021).

Traumatic causes of knee pain

Patella fracture and dislocation

The patella is the largest sesamoid bone in the body, and is most commonly fractured via direct impact or indirect extensor contraction injury (Hargett et al, 2021). There are several types of patellar fractures, including transverse, vertical, comminuted and osteochondral fractures (Hargett et al, 2021; Hanschen et al, 2021) (Figure 1).

Plain radiographs are often used as the initial imaging modality, with computed tomography and magnetic resonance imaging reserved for more complex or severe cases (Jarraya et al, 2016).

Both patient and fracture factors must be considered when planning management. In terms of fracture factors, non-operative management may be appropriate for non-displaced transverse fractures or vertical fractures with less than 3 mm of displacement. This may involve immobilisation in a cast or brace, initially in extension, followed by physiotherapy to help with strength and range of movement (Steinmetz et al, 2020).

Surgical intervention involves open reduction and internal fixation; specific techniques will vary depending on fracture configuration and surgeon preference. In some cases, partial or total patellectomy may be necessary, especially in cases where there is significant damage to the cartilage (Steinmetz et al, 2020).

Patella dislocations occur secondary to twisting injuries or direct medial blow to the knee. It accounts for approximately 2% of knee injuries and is more common in those with chronic laxity. Plain radiographs are often first line to assess the type of dislocation. Computed tomography can be used to calculate the tibial tuberosity to trochlear groove distance, an important parameter in the management. Magnetic resonance imaging is reserved for assessing associated soft tissue injury. Prompt reduction is used in the acute setting, with surgical management considered in situations involving osteochondral loose bodies, disruption of medial patellofemoral ligament or recurrent dislocations (Hayat et al, 2023).

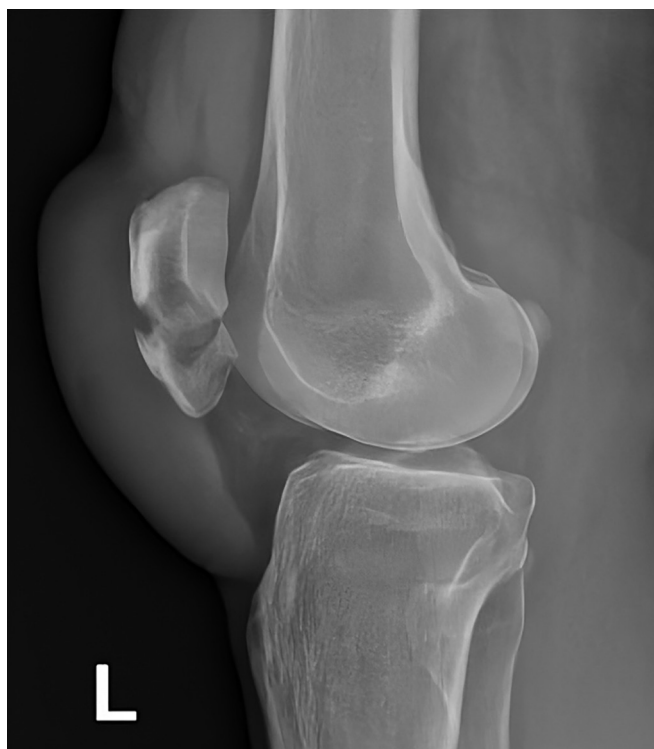


Figure 1. Lateral view of a transverse patella fracture.

Tibial plateau fractures

Tibial plateau fractures involve the articular surface of the proximal tibia which is important for weight bearing and stability. They can result from axial compressive forces with varus or valgus stress on the knee joint. More than 50% are associated with meniscal injuries and 25% with ligament injuries (Júnior et al, 2009).

Imaging plays a crucial role and radiographs are usually the first-line imaging modality. However, plain films have a sensitivity of 85% so tibial plateau fractures can be difficult to identify (Mthethwa and Chikate, 2017). Computed tomography can provide three-dimensional reconstructions and detailed information on the fracture pattern and degree of comminution, which helps with surgical planning (Chan et al, 1997). Magnetic resonance imaging can provide additional information such as ligamentous or meniscal tears, which often coexist with tibial plateau fractures (Liu et al, 2020).

The Schatzker classification system is used to describe tibial plateau fractures based on the pattern of injury and can help to guide treatment decisions (Figure 2) (Zeltser and Leopold, 2012).

Management depends on patient factors (eg ambulatory status and suitability for surgery as a result of comorbidities) and fracture factors. Fracture factors include severity of articular depression, comminution, widening of the plateau, instability (varus or valgus), fracture configuration and associated injuries (soft tissue injuries, eg meniscal, open fractures or neurovascular injuries). Non-operative management may involve the use of a hinged brace or plaster of Paris, while surgical options include open reduction and internal fixation, external fixators (eg circular frames) and arthroplasty (Prat-Fabregat and Camacho-Carrasco, 2016).

Postoperative management involves early mobilisation and physical therapy to restore range of motion, muscle strength, and joint function. Follow-up imaging and clinical evaluation are important for assessing healing and identifying any complications (Prat-Fabregat and Camacho-Carrasco, 2016).

Cruciate ligament injury

The anterior and posterior cruciate ligaments are important stabilisers of the knee joint. Acute anterior cruciate ligament injuries are commonly caused by non-contact pivoting injuries, where the tibia moves anteriorly and the knee is in flexion and valgus. The frequency of these injuries continues to increase, especially in the adolescent population (Weitz et al,

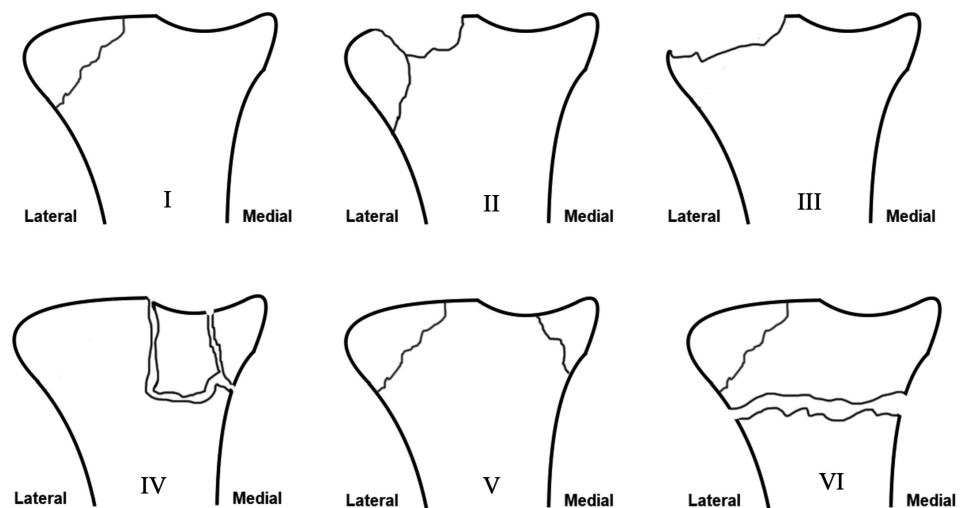


Figure 2. Schatzker classification for tibial plateau fractures. I. Lateral tibial plateau split; II. Lateral tibial plateau split depression; III. Central depression fracture; IV. Medial tibial plateau split; V. Bicondylar fracture; VI. Metaphysis and diaphysis dissociation.

2019). Patients typically present with sudden onset of pain, swelling and instability of the knee. Posterior cruciate ligament injuries are less common and are usually caused by a direct blow to the anterior aspect of the knee, such as dashboard injuries. Special tests to assess the anterior cruciate ligament include the anterior drawer, Lachmann's and pivot shift, while the posterior drawer test and observation for a 'posterior sag' can help identify a posterior cruciate ligament injury. Associated posterolateral corner injuries must not be forgotten and this can be assessed clinically with the dial test at 90° (Kassim, 2014). Both anterior and posterior cruciate ligament injury can be classified based upon the radiological severity of injury, as well as the amount of translation anteroposteriorly during clinical examination: grade 1 (<5 mm), grade 2 (5–10 mm) and grade 3 (>10 mm) (Ng et al, 2011).

Magnetic resonance imaging is the preferred imaging modality for diagnosing both anterior and posterior cruciate ligament injuries with a sensitivity and specificity of >90% (Zhao et al, 2020). Magnetic resonance imaging can provide detailed information on the extent of ligament damage and can identify associated injuries, such as meniscal or cartilage damage (Figures 3a–c) (van der List et al, 2017).

Management of anterior cruciate ligament injuries depends on the severity of the injury, the patient's age, activity level, functional goals and symptoms (ongoing instability). A period of non-operative, physiotherapy-led management to improve quadriceps strength and prevent stiffness is important before consideration of surgical intervention. Ongoing instability in chronic injuries improves with delayed operative management and should be considered where appropriate (Beard et al, 2022). Surgical management involves reconstruction using autografts (hamstring, bone patellar tendon, quadriceps), although in some situations an allograft may be used. In paediatric cases, surgical techniques differ to prevent and mitigate damage to the growth plates. Irrespective of the management option, rehabilitation can take 9–12 months before return to sport or pivoting activities (Evans et al, 2023).

Unlike anterior cruciate ligament injuries, many posterior cruciate ligament injuries can be managed non-surgically with rehabilitation and bracing. However, surgical intervention may be necessary in cases of significant instability or associated injuries (Raj et al, 2023).

Non-traumatic causes of knee pain

Septic arthritis

Septic arthritis is a surgical emergency. The knee is the most commonly affected joint (Carpenter et al, 2011). Patients often present with sudden onset of severe pain, swelling and warmth, accompanied by fever. There may be restricted mobility of the joint as a result of pain and swelling in the acute stages (Long et al, 2019).

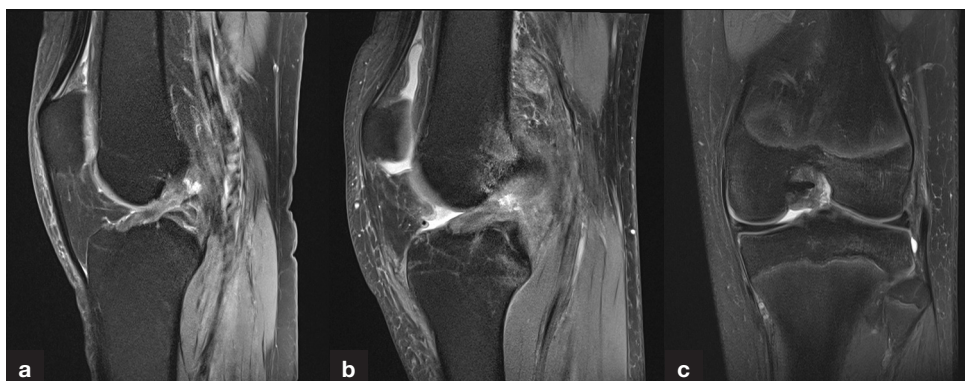

Figure 3. Magnetic resonance imaging of the left knee. a. Sagittal view demonstrating a mid-substance anterior cruciate ligament tear. b. Sagittal view demonstrating a proximal anterior cruciate ligament tear. c. Coronal view demonstrating a proximal anterior cruciate ligament tear.

Plain radiographs, consisting of antero-posterior and lateral views, are used to exclude other pathologies, such as fractures or degeneration. Soft tissue swelling and joint effusion may be present (Abbod et al, 2018).

Magnetic resonance imaging is useful to evaluate the joint space and assess for an effusion, synovial thickening, or bone involvement including oedema. Magnetic resonance imaging is a highly sensitive and specific method for detecting early cartilaginous damage. Contrast-enhanced T1-weighted imaging can reveal synovial enhancement reflecting synovitis, as well as pericapsular enhancement (Karchevsky et al, 2004).

Levels of biochemical markers of inflammation are often raised, including white blood cell count, C-reactive protein and erythrocyte sedimentation rate (Chan et al, 2020).

Joint aspiration remains the gold standard for diagnosing septic arthritis, and *Staphylococcus aureus* is the most common causative organism (Chan et al, 2020).

Management should be initiated promptly to prevent joint destruction and systemic spread of infection. Empirical antibiotic therapy should be started promptly after joint aspiration, based on local antibiotic guidelines. Intravenous antibiotics should be adjusted according to joint aspirate analysis. Surgical washout (usually arthroscopic) is required to reduce infective load (Coakley et al, 2006).

In addition to analgesia, physiotherapy can help improve joint mobility and function after the acute phase of the infection to reduce stiffness. Early intervention and close follow up are crucial to achieve a successful outcome (Coakley et al, 2006).

Osteoarthritis

Osteoarthritis is a common degenerative joint disorder that can affect the knee joint. Patients often present with chronic knee pain, stiffness and swelling. The pain may worsen with activity and improve with rest. Examination findings include joint swelling, tenderness and reduced range of movement, with crepitus associated with movement (Mora et al, 2018).

Plain film findings are diagnostic, and include joint space narrowing, osteophyte formation, subchondral sclerosis and subchondral cysts (Figure 4).

Where diagnosis is unclear, or symptoms are out of keeping with the severity of changes on radiographs, magnetic resonance imaging provides further detailed information regarding cartilaginous loss, bone marrow oedema and synovitis (Roemer et al, 2020).

Markers of inflammation may be elevated (C-reactive protein levels, erythrocyte sedimentation rate), especially during an acute flare, although these tests are not specific to osteoarthritis.

Management should be tailored to the individual patient's need with the aim of minimising pain, and improving joint mobility and thereby quality of life. The National Institute for Health and Care Excellence (2022b) guidelines recommend a combination of non-pharmacological and pharmacological interventions.

Non-pharmacological interventions include lifestyle factors such as weight loss, exercise, physical therapy, and use of assistive devices such as braces. The aim is to reduce the load on the knee joint therefore reducing pain and stiffness (Mora et al, 2018; National Institute for Health and Care Excellence, 2022b).

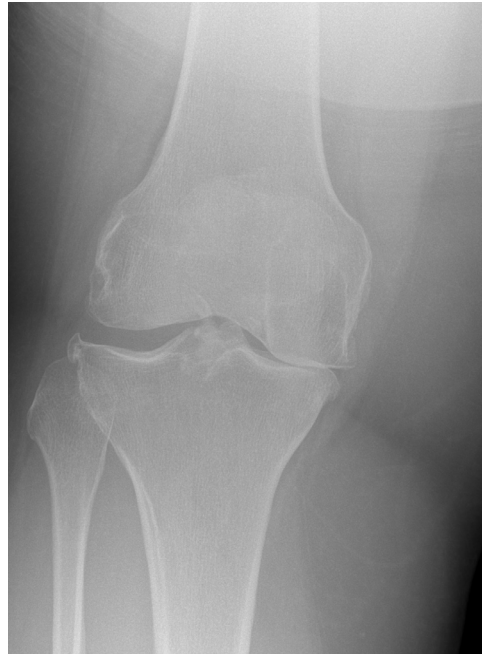

Figure 4. Radiograph demonstrates joint space narrowing, subchondral sclerosis and osteophyte formation especially of the medial compartment in keeping with osteoarthritis.

Pharmacological interventions include analgesia, topical treatments or intra-articular corticosteroid injections often performed under ultrasound guidance. Non-steroidal anti-inflammatory drugs reduce both pain and inflammation. Intra-articular corticosteroid injections provide targeted pain relief, often lasting several months (Mora et al, 2018; National Institute for Health and Care Excellence, 2022b).

Where non-operative interventions fail to control symptoms, surgical options include osteotomies (distal femur, proximal tibia), uni-compartmental knee replacements or total knee replacements. Factors which affect the decision regarding which operation to perform include disease severity, affected compartment(s), patient's age, comorbidities and function.

Gout

Gout is an inflammatory arthritis resulting from the deposition of uric acid crystals in joints and soft tissues. It typically presents with acute onset of pain, swelling and redness in the affected joint, most commonly the big toe, but can involve other joints such as the ankle, knee, wrist or fingers (Ragab et al, 2017).

Imaging is not necessary for diagnosis, which is usually made based on clinical presentation and confirmation of hyperuricaemia, but can be helpful when diagnosis is uncertain or to assess for complications. Radiographs may demonstrate joint erosion, soft tissue swelling and the presence of tophi, although appearances may be normal in the early stages. Ultrasound can detect the presence of urate crystal deposits in the joint. This is useful for monitoring disease activity and confirming diagnosis (Chowalloor et al, 2014).

A more advanced imaging technique is the use of dual-energy computed tomography that accurately identifies the presence of deposits of uric acid crystals. Dual-energy computed tomography is more sensitive than ultrasound and is useful for assessing multiple joints simultaneously (Tanikawa et al, 2018).

Acute attacks are typically treated with non-steroidal anti-inflammatory drugs, colchicine or corticosteroids to reduce inflammation and pain. Non-steroidal anti-inflammatory drugs are the first-line treatment for most patients. Long-term management involves reducing serum urate levels to prevent future attacks, via lifestyle modifications, such as weight loss and dietary changes, and use of drugs such as allopurinol. These medications decrease the production or increase the excretion of uric acid from the body. It is important to continue measuring serum urate levels as the reduction can take months to years (National Institute for Health and Care Excellence, 2022c). The goal of treatment is to prevent future attacks and complications by maintaining a serum urate level below 6mg/dl (Burns and Wortmann, 2012).

Pseudogout

Pseudogout results from the deposition of calcium pyrophosphate crystals most commonly within the knee joint. It typically presents with acute onset of pain, swelling, and stiffness (Rosenthal and Ryan, 2016).

Again, diagnosis is usually made based on clinical presentation and confirmation of deposition of calcium pyrophosphate crystals via synovial fluid analysis.

Radiographs may show joint effusions, joint space narrowing, and the presence of chondrocalcinosis. Dual-energy computed tomography provides good sensitivity and specificity for detection of calcium pyrophosphate crystals. Computed tomography and magnetic resonance imaging can be used when joint effusions or other soft tissue abnormalities are present (Miksaneck and Rosenthal, 2015; Tanikawa et al, 2018).

Similar to gout, non-steroidal anti-inflammatory drugs, colchicine or corticosteroids are used in acute attacks to reduce pain and inflammation (Burns and Wortmann, 2012). Long-term management of pseudogout involves reducing the frequency and severity of attacks and preventing complications through lifestyle modifications. In some cases, medications such as hydroxychloroquine or methotrexate may be used to help prevent attacks and reduce joint damage (MacMullan and McCarthy, 2011).

Neoplastic causes of knee pain

Neoplastic causes refer to malignant or benign growths affecting the knee. Pain may be persistent, unexplained or associated with systemic red flag symptoms (Andrade Neto et al, 2016). Some benign and malignant causes are listed in [Table 2](#).

Radiology plays a crucial role in the investigation, diagnosis and evaluation of neoplastic causes of knee pain. A combination of radiography, computed tomography and magnetic

Table 2. Benign and malignant bone pathologies around the knee joint differentiated by age group

Age	Type of pathology	Example
Under 30 years of age	Benign	Osteochondroma
		Enchondroma
		Chondroblastoma
		Aneurysmal bone cyst
		Unicameral bone cyst
		Osteoid osteoma
		Non-ossifying fibroma
		Osteomyelitis
	Malignant	Ewing's sarcoma
Osteosarcoma		
Over 30 years of age	Benign	Giant cell tumour
		Aneurysmal bone cyst
		Geode
		Osteomyelitis
	Malignant	Metastasis
		Osteosarcoma
		Lymphoma
		Chondrosarcoma
Myeloma		

Key points

- Knee pain can have both traumatic and non-traumatic causes, and clinical assessment and anatomical knowledge are both important.
- Traumatic causes, such as patella fractures and cruciate ligament injuries, are important to identify early with clinical assessment and imaging. This enables prompt diagnosis and management which includes early surgical intervention.
- Non-traumatic conditions, such as septic arthritis and osteoarthritis, can have a significant impact on a patient's ongoing quality of life and therefore imaging is important to identify associated changes which can be treated early on.
- Timely and appropriate imaging is important in facilitating early accurate diagnosis and therefore guiding prompt management for various causes of knee pain.

resonance imaging can be used to narrow differentials and tailor management. The radiological findings can vary depending on the type and stage of tumour. The first-line imaging modality is often plain radiograph used to evaluate bony abnormalities helping to identify lytic or sclerotic lesions, periosteal reactions or pathological fractures (Larbi et al, 2016). Early-stage tumours may not be evident on X-rays, and further imaging may be necessary (Andrade Neto et al, 2016; Larbi et al, 2016).

Magnetic resonance imaging is the modality of choice for neoplastic causes and is highly sensitive in detecting soft tissue abnormalities. It allows a detailed assessment of the extent of the tumour and involvement of surrounding structures. Magnetic resonance imaging can differentiate between different types of tumours thereby directing treatment for patients. Computed tomography scans may be used to assess bony structures and identify areas of bone destruction or remodelling (Andrade Neto et al, 2016). These findings help guide further management, including biopsy and surgical planning if deemed appropriate, and determine course of treatment (Larbi et al, 2016).

Conclusions

This article provides an overview of the common causes of knee pain ranging from traumatic to non-traumatic conditions, including the role of imaging, and management options available to junior doctors. A good clinical examination and review of appropriate imaging enables prompt and precise treatment contributing to better patient outcomes.

Author details

¹Department of Radiology, Chelsea and Westminster Hospital, London, UK

²Department of Trauma and Orthopaedics, Addenbrooke's Hospital, Cambridge, UK

³University of Leeds and Biochemical Research Centre, Musculoskeletal Centre, Department of Radiology, Chapel Allerton Hospital, Leeds Teaching Hospitals, Leeds, UK

Conflicts of interest

The authors declare that there are no conflicts of interest.

References

- Abbod H, Al-Otaibi L, Alshamiri K. Septic arthritis. *Int J Pediatr Adolesc Med.* 2018;5(4):152–154. <https://doi.org/10.1016/j.ijpam.2018.12.005>
- Andrade Neto F, Teixeira MJD, Araújo LDC, Ponte CEB. Knee bone tumors: findings on conventional radiology. *Radiol Bras.* 2016;49(3):182–189. <https://doi.org/10.1590/0100-3984.2013.0007>
- Aweid O, Osmani H, Melton J. Biomechanics of the knee. *Orthop Trauma.* 2019;33(4):224–230. <https://doi.org/10.1016/j.mporth.2019.05.004>
- Beard DJ, Davies L, Cook JA et al. Rehabilitation versus surgical reconstruction for non-acute anterior cruciate ligament injury (ACL SNNAP): a pragmatic randomised controlled trial. *Lancet.* 2022;400(10352):605–615. [https://doi.org/10.1016/s0140-6736\(22\)01424-6](https://doi.org/10.1016/s0140-6736(22)01424-6)

- Bliddal H, Christensen R. The treatment and prevention of knee osteoarthritis: a tool for clinical decision-making. *Expert Opin Pharmacother*. 2009;10(11):1793–1804. <https://doi.org/10.1517/14656560903018911>
- Burns CM, Wortmann RL. Latest evidence on gout management: what the clinician needs to know. *Ther Adv Chronic Dis*. 2012;3(6):271–286. <https://doi.org/10.1177/2040622312462056>
- Carpenter CR, Schuur JD, Everett WW, Pines JM. Evidence-based diagnostics: adult septic arthritis. *Acad Emerg Med*. 2011;18(8):781–796. <https://doi.org/10.1111/j.1553-2712.2011.01121.x>
- Chan PSH, Klimkiewicz JJ, Luchetti WT et al. Impact of CT scan on treatment plan and fracture classification of tibial plateau fractures. *J Orthop Trauma*. 1997;11(7):484–489. <https://doi.org/10.1097/00005131-199710000-00005>
- Chan BY, Crawford AM, Kobes PH et al. Septic arthritis: an evidence-based review of diagnosis and image-guided aspiration. *AJR Am J Roentgenol*. 2020;215(3):568–581. <https://doi.org/10.2214/ajr.20.22773>
- Chowalloor PV, Siew TK, Keen HI. Imaging in gout: a review of the recent developments. *Ther Adv Musculoskelet Dis*. 2014;6(4):131–143. <https://doi.org/10.1177/1759720X14542960>
- Coakley G, Mathews C, Field M et al. BSR and BHP, BOA, RCGP and BSAC guidelines for management of the hot swollen joint in adults. *Rheumatology*. 2006;45(8):1039–1041. <https://doi.org/10.1093/rheumatology/ke1163a>
- Evans J, Mabrouk A, Nielson JL. Anterior cruciate ligament knee injury. 2023. <https://www.ncbi.nlm.nih.gov/books/NBK499848/> (accessed 17 January 2024)
- Hanschen M, Biberthaler P, Waddell JP. Knee fractures. Cham, Switzerland: Springer Nature; 2021
- Hargett DI, Sanderson BR, Little MTM. Patella fractures: approach to treatment. *J Am Acad Orthop Surg*. 2021;29(6):244–253. <https://doi.org/10.5435/jaaos-d-20-00591>
- Harris N, Ali F. Examination techniques in orthopaedics. Cambridge: Cambridge University Press; 2014
- Hayat Z, El Bitar Y, Case JL. Patella dislocation. Treasure Island (FL): StatPearls Publishing; 2023
- Jarraya M, Diaz LE, Arndt WF, Roemer FW, Guermazi A. Imaging of patellar fractures. *Insights Imaging*. 2016;8(1):49–57. <https://doi.org/10.1007/s13244-016-0535-0>
- Jones C, Rai P. Knee pain in adults. *InnovAiT*. 2023;16(4):196–202. <https://doi.org/10.1177/17557380221149753>
- Júnior MK, Fogagnolo F, Bitar RC et al. Tibial plateau fractures. *Rev Bras Ortop*. 2009;44(6):468–474. <https://doi.org/10.1590/S0102-36162009000600002>
- Karchevsky M, Schweitzer ME, Morrison WB, Parellada JA. MRI findings of septic arthritis and associated osteomyelitis in adults. *AJR Am J Roentgenol*. 2004;182(1):119–122. <https://doi.org/10.2214/ajr.182.1.1820119>
- Kassim M. FRCS trauma and orthopaedics exam. London: Mint Associates Ltd; 2014
- Khan S, Logan PC, Asokan A, Handford C, Moores T. The assessment and management of the arthritic knee: an update. *Cureus*. 2020;12(11):e11582. <https://doi.org/10.7759/cureus.11582>
- Larbi A, Viala P, Cyteval C et al. Imaging of tumors and tumor-like lesions of the knee. *Diagn Interv Imaging*. 2016;97(7–8):767–777. <https://doi.org/10.1016/j.diii.2016.06.004>
- Liu XD, Wang HB, Zhang TC, Wan Y, Zhang CZ. Comparison between computed tomography and magnetic resonance imaging in clinical diagnosis and treatment of tibial platform fractures. *World J Clin Cases*. 2020;8(18):4067–4074. <https://doi.org/10.12998/wjcc.v8.i18.4067>
- Long B, Koyfman A, Gottlieb M. Evaluation and management of septic arthritis and its mimics in the emergency department. *West J Emerg Med*. 2019;20(2):331–341. <https://doi.org/10.5811/westjem.2018.10.40974>
- MacMullan P, McCarthy G. Treatment and management of pseudogout: insights for the clinician. *Ther Adv Musculoskelet Dis*. 2011;4(2):121–131. <https://doi.org/10.1177/1759720x11432559>
- Miksaneck J, Rosenthal AK. Imaging of calcium pyrophosphate deposition disease. *Curr Rheumatol Rep*. 2015;17(3). <https://doi.org/10.1007/s11926-015-0496-1>
- Mora JC, Przkora R, Cruz-Almeida Y. Knee osteoarthritis: pathophysiology and current treatment modalities. *J Pain Res*. 2018;11(11):2189–2196. <https://doi.org/10.2147/jpr.s154002>
- Mthethwa J, Chikate A. A review of the management of tibial plateau fractures. *Musculoskelet Surg*. 2017;102(2):119–127. <https://doi.org/10.1007/s12306-017-0514-8>
- National Institute for Health and Care Excellence. Knee pain - assessment. 2022a. <https://cks.nice.org.uk/topics/knee-pain-assessment/> (accessed 17 January 2024)
- National Institute for Health and Care Excellence. Osteoarthritis in over 16s: diagnosis and management. 2022b. <https://www.nice.org.uk/guidance/ng226> (accessed 17 January 2024)
- National Institute for Health and Care Excellence. Gout: diagnosis and management. 2022c. <https://www.nice.org.uk/guidance/ng219/chapter/Recommendations> (accessed 17 January 2024)

- Ng WH, Griffith JF, Hung EH, Paunipagar B, Law BK, Yung PS. Imaging of the anterior cruciate ligament. *World J Orthop*. 2011;2(8):75–84. <https://doi.org/10.5312/wjo.v2.i8.75>
- Prat-Fabregat S, Camacho-Carrasco P. Treatment strategy for tibial plateau fractures: an update. *EFORT Open Rev*. 2016;1(5):225–232. <https://doi.org/10.1302/2058-5241.1.000031>
- Ragab G, Elshahaly M, Bardin T. Gout: an old disease in new perspective – a review. *J Adv Res*. 2017;8(5):495–511. <https://doi.org/10.1016/j.jare.2017.04.008>
- Raj MA, Mabrouk A, Varacallo M. Posterior cruciate ligament knee injuries. 2023. <https://www.ncbi.nlm.nih.gov/books/NBK430726/> (accessed 17 January 2024)
- Roemer FW, Demehri S, Omoumi P et al. State of the art: imaging of osteoarthritis—revisited 2020. *Radiology*. 2020;296(1):5–21. <https://doi.org/10.1148/radiol.2020192498>
- Rosenthal AK, Ryan LM. Calcium pyrophosphate deposition disease. *N Engl J Med*. 2016;374(26):2575–2584. <https://doi.org/10.1056/NEJMra1511117>
- Steinmetz S, Brgger A, Chauveau J et al. Practical guidelines for the treatment of patellar fractures in adults. *Swiss Med Wkly*. 2020;150(0102). <https://doi.org/10.4414/smw.2020.20165>
- Stiell IG, Greenberg GH, Wells GA et al. Derivation of a decision rule for the use of radiography in acute knee injuries. *Ann Emerg Med*. 1995;26(4):405–413. [https://doi.org/10.1016/s0196-0644\(95\)70106-0](https://doi.org/10.1016/s0196-0644(95)70106-0)
- Tanikawa H, Ogawa R, Okuma K et al. Detection of calcium pyrophosphate dihydrate crystals in knee meniscus by dual-energy computed tomography. *J Orthop Surg Res*. 2018;13(1):73. <https://doi.org/10.1186/s13018-018-0787-0>
- van der List JP, Mintz DN, DiFelice GS. The location of anterior cruciate ligament tears: a prevalence study using magnetic resonance imaging. *Orthop J Sports Med*. 2017;5(6):232596711770996. <https://doi.org/10.1177/2325967117709966>
- Weitz FK, Sillanpää PJ, Mattila VM. The incidence of paediatric ACL injury is increasing in Finland. *Knee Surg Sports Traumatol Arthrosc*. 2019;28(2):363–368. <https://doi.org/10.1007/s00167-019-05553-9>
- Zeltser DW, Leopold SS. Classifications in brief: schatzker classification of tibial plateau fractures. *Clin Orthop Relat Res*. 2012;471(2):371–374. <https://doi.org/10.1007/s11999-012-2451-z>
- Zhao M, Zhou Y, Chang J et al. The accuracy of MRI in the diagnosis of anterior cruciate ligament injury. *Ann Transl Med*. 2020;8(24):1657–1657. <https://doi.org/10.21037/atm-20-7391>