

# Contained gastric ulcer perforation presenting with acute pancreatitis

Uluhan Eryuruk<sup>1</sup>

Tumay Bekci<sup>1</sup>

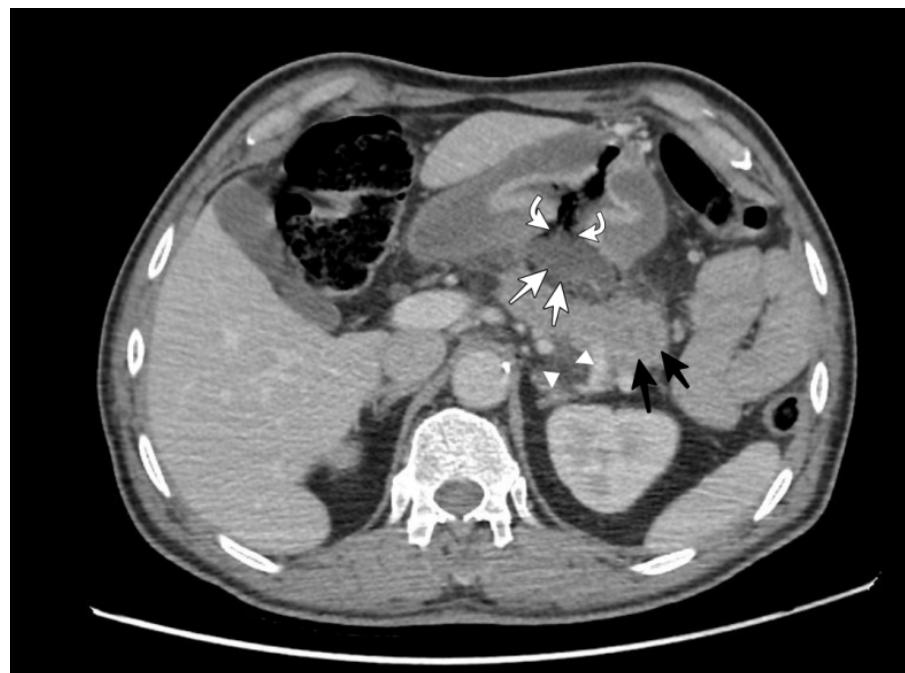
Serdar Aslan<sup>1</sup>

Author details can be found at the end of this article

Correspondence to:

Uluhan Eryuruk;  
uluhaneryuruk@gmail.com

A 62-year-old male patient was admitted to the emergency department with upper abdominal pain. Laboratory tests revealed an amylase level of 519 U/L and a lipase level of 946 U/L. Abdominal computed tomography showed a large gastric ulceration with gastric contents extending posteriorly and confined by the pancreas. A slight increase in the thickness of the pancreatic tail and stranding of the surrounding fat were observed (Figure 1). Imaging and laboratory findings suggested acute pancreatitis due to a contained gastric perforation. The patient received medical treatment, showing clinical improvement in follow-up.



**Figure 1.** Abdominal computed tomography shows gastric content (white arrows) extending posteriorly from large gastric ulceration (curved arrows), confined by the pancreas, and increased thickness of the pancreatic tail (black arrows) with stranding of the surrounding fat (arrowheads).

Gastric perforation is a well-known serious complication of necrotising pancreatitis (Bansal et al, 2019). In contrast, gastric perforation leading to acute pancreatitis is rare. In our case, the mild pancreatitis with the absence of necrosis, and confined gastric perforation suggested that gastric perforation caused pancreatitis. The patient's recovery with medical treatment further supported this. Awareness of this rare association of gastric perforation with acute pancreatitis will benefit clinicians in the treatment and follow-up of patients.

## Author details

<sup>1</sup>Department of Radiology, Faculty of Medicine, Giresun University, Giresun, Turkey

## Reference

Bansal A, Gupta P, Singh H et al. Gastrointestinal complications in acute and chronic pancreatitis. *JGH Open*. 2019;3(6):450–455. <https://doi.org/10.1002/jgh3.12185>

## How to cite this article:

Eryuruk U, Bekci T, Aslan S. Contained gastric ulcer perforation presenting with acute pancreatitis. *Br J Hosp Med*. 2024. <https://doi.org/10.12968/hmed.2024.0026>