

An unusual case of enterococcal tricuspid valve endocarditis

J Kelly, A Prasan, J Costello

A case of enterococcal tricuspid valve endocarditis in a previously healthy middle-aged male is presented. He was not actively using intravenous drugs although he had done so for a short time 30 years previously. The presentation with pulmonary symptoms on a background of constitutional disturbance and the presence of a circumscribed mass on the chest X-ray (CXR) led to an initial presumptive diagnosis of malignancy.

The diagnosis of right-sided endocarditis in non-addicted patients requires a high index of suspicion. Presentation is with pleuropulmonary rather than cardiac symptoms and misdiagnoses such as neoplasia, pneumonia and vasculitis are common.

DISCUSSION

Right-sided endocarditis accounts for approximately 5–10% of all cases of endocarditis and usually affects the tricuspid valve. The majority of cases are secondary to *Staphylococcus aureus* in

intravenous drug users (IVDUs), in whom the tricuspid valve is almost always normal before infection. In non-IVDUs, there is usually a history of underlying cardiac disease. Risk factors in this group include indwelling central venous catheters, right heart catheterization and inadequately treated sepsis (Chan et al, 1989; Panidis et al, 1984; Naidoo, 1993).

In one series of non-addicted patients with isolated native tricuspid valve endocarditis, *S. aureus*, group D streptococci and candida species accounted for 70% of cases. Over 70% of patients had important underlying medical conditions and diagnostic delays were common. Community-acquired pneumonia, malignancy and vasculitis (in view of pulmonary infiltrates and microscopic haematuria) were common initial misdiagnoses (Nandakumar and Raju, 1997).

Septic pulmonary emboli occur in 60–100% of patients with right-sided

endocarditis (Panidis et al, 1984). These usually affect the lower zones, are often multiple, may appear sequentially and cavitate. They may continue for several weeks following effective treatment.

A systolic murmur is found at presentation in approximately 70% of cases (Hecht and Berger, 1992) but may be misinterpreted as a flow murmur as a consequence of fever and anaemia. There may be no clinical signs of cardiac disease. It is notable that the presenting features are fre-

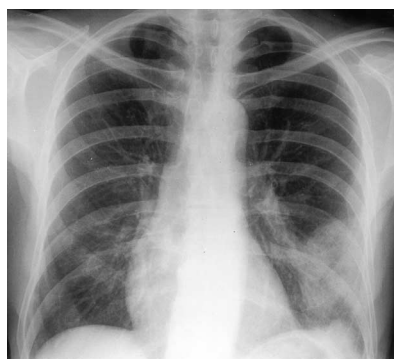


Figure 1. Chest X-ray appearance.

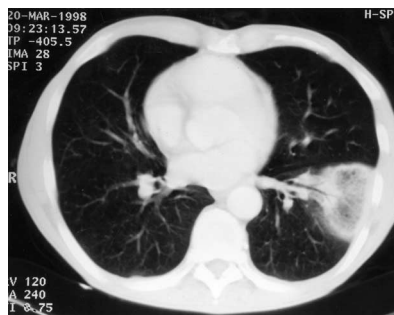


Figure 2. Computed tomography appearance of lesion, showing a cavitating septic pulmonary infarct.

CASE REPORT

A 52-year-old male smoker presented with a 10-week history of weight loss and malaise, together with a 1-week history of left-sided pleuritic chest pain, haemoptysis and mild dyspnoea. He had used intravenous drugs for a short time 30 years previously although he denied any intravenous drug use since. There was no other past medical history of note.

On examination, he was thin and appeared chronically unwell. He was afebrile. There was a left pleural rub. There were no murmurs or stigmata of endocarditis. There were no other findings of note.

Full blood screen was normal apart from a white cell count of 11.2×10^9 /litre (normal range $4.0\text{--}11.0 \times 10^9$ /litre). Erythrocyte sedimentation rate was 52 mm/hr and C-reactive protein was 16 mg/litre (normal range <7.0 mg/litre). Urinalysis and urine culture were normal. The chest X-ray showed a circumscribed left lower zone lesion (Figure 1). Figure 2 shows the computed tomography appearance of the lesion.

At this stage, pulmonary malignancy was suspected (either a primary or secondary). The following day, two sets of blood cultures were taken in view of a low grade pyrexia. *Enterococcus faecalis* grew from all four bottles and the patient was started on intravenous amoxicillin.

Five days after admission a new soft pansystolic murmur at the left sternal edge was noted. Intravenous gentamicin was added. Transthoracic echocardiogram was normal but was repeated after an interval of 10 days in view of continuing low grade pyrexia and at this stage showed a vegetation adherent to the tricuspid valve (Figure 3).

The patient was treated with intravenous amoxicillin and gentamicin for a total of 6 weeks. He did not develop any further complications and has remained well at follow up.

Dr J Kelly is Specialist Registrar in the Department of Health Care for the Elderly, Queen Mary's Hospital, Sidcup, Dr A Prasan is Specialist Registrar in the Department of Cardiology and Dr J Costello is Consultant in the Department of Thoracic Medicine, King's College Hospital, London

Correspondence to: Dr J Kelly, Northbrook, 32 Fairmile Lane, Cobham, Surrey KT11 2DQ

quently pleuropulmonary (cough, haemoptysis, pleuritic pain and dyspnoea) rather than cardiac.

In IVDUs, the prognosis of isolated, native right-sided endocarditis is good with a mortality of around 7% (Hecht and Berger, 1992). Seventy five per cent of patients respond to medical therapy (Chan et al, 1989), although the presence of vegetations >1.0 cm are associated with a lower response rate (Robbins et al, 1986).

Severe heart failure and uncontrolled infection are the two major indications for surgery. Continuing septic pulmonary emboli do not have the same implications as systemic emboli in left-sided endocarditis and are not necessarily an indication for surgery.

In this case, the relevance of the past history of intravenous drug use is unclear. Recent intravenous drug use was strongly denied. Although the initial transthoracic echocardiogram showed a structurally normal heart, it is possible that earlier endothelial damage resulting from bombardment of the tricuspid valve with particulate matter while using intravenous drugs acted as a substrate for infection many years later, although this remains speculative. Diverticular disease was demonstrated at colonoscopy and was the likely source of the initial *Enterococcus faecalis* bacteraemia.

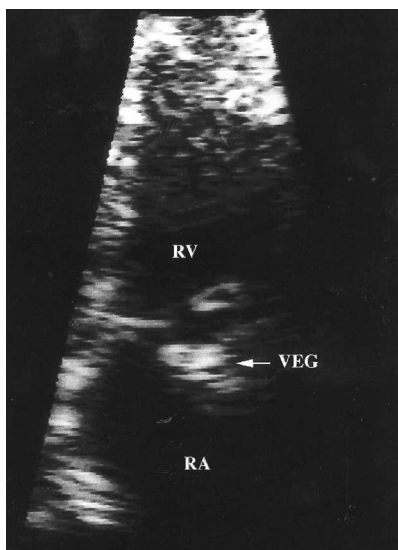


Figure 3. Transthoracic echocardiogram showing vegetation (VEG) adherent to tricuspid valve. RA = right atrium; RV = right ventricle.

The group D streptococci are divided into enterococcal (*E. faecalis* accounting for 80–90% within this group) and non-enterococcal (typified by *Streptococcus bovis*) species. Enterococcal bacteraemia usually arises from the genitourinary or gastrointestinal tract and may be nosocomial (75% of cases; Maki and Agger, 1988) or community acquired.

Enterococci now account for around 10% of all cases of native valve endocarditis (Working Party of the British Society for Antimicrobial Chemotherapy, 1997). The probability of underlying endocarditis in enterococcal bacteraemia depends on the setting in which the bacteraemia has been acquired. It is found in one-third of patients presenting from the community (Maki and Agger, 1988), but occurs in only 1% of nosocomial cases (Megran, 1992). In one series, 70% of cases of cryptogenic (with no obvious source) community-acquired cases of enterococcaemia were eventually found to have endocarditis (Maki and Agger, 1988). The author concluded that such cases should therefore be treated as endocarditis until proven otherwise. In other cases where an extracardiac source for infection is apparent, a careful search for evidence of endocarditis should be made during and after treatment.

The clinical features and complications of enterococcal endocarditis do not differ from those seen with other infective agents. However, it tends to be a more indolent illness (Megran, 1992).

Although the association of *Strep. bovis* endocarditis and underlying colonic carcinoma is well established (McMahon et al, 1991), there is little published literature examining such a potential relationship with enterococci. In one series of patients with group D streptococcal endocarditis, colonic carcinoma was found in 18% of the cases caused by *Strep. bovis* but in only 2% of those caused by enterococci (Leport et al, 1987).

Unlike other streptococci, enterococci are not reliably killed by penicillin or ampicillin alone in vitro. Recent guidelines therefore suggest that effective treatment requires the addition of an aminoglycoside for at least 4 weeks

(Working Party of the British Society for Antimicrobial Chemotherapy, 1997).

This case illustrates the way in which the diagnosis of right-sided endocarditis may be delayed because of a clinical picture that is dominated by extracardiac symptoms, particularly respiratory symptoms resulting from septic pulmonary emboli. The diagnosis may not be considered in patients who are not active IVDUs.

The diagnosis of right-sided endocarditis should be suspected in a patient presenting with pleuropulmonary symptoms or focal CXR abnormalities and bacteraemia with an endocarditis-type organism, even if there are no overt signs of cardiac disease and classical risk factors are absent. The triad of recurrent pulmonary events, anaemia and microscopic haematuria should also suggest the diagnosis (Nandakumar and Raju, 1997).

A diligent search should be made for evidence of underlying endocarditis in any patient presenting from the community with enterococcal bacteraemia, particularly where an extracardiac source of infection cannot be demonstrated. Initial presumptive treatment for endocarditis may be appropriate in these cases. **HM**

- Chan P, Ogilby JD, Segal B (1989) Tricuspid valve endocarditis. *Am Heart J* **117**: 1140–6
- Hecht SR, Berger M (1992) Right sided endocarditis in intravenous drug users. *Ann Intern Med* **117**: 560–6
- Leport C, Bure A, Leport J, Vilde J (1987) Incidence of colonic lesions in *Streptococcus bovis* and enterococcal endocarditis. *Lancet* **ii**: 748
- McMahon AJ, Auld CD, Dale BA, Walls AD, McCormick JS (1991) *Streptococcus bovis* septicaemia associated with uncomplicated colonic carcinoma. *Br J Surg* **78**: 883–5
- Maki DG, Agger WA (1988) Enterococcal bacteraemia: clinical features, the risk of endocarditis and management. *Medicine* **67**: 248–69
- Megran DW (1992) Enterococcal endocarditis. *Clin Infect Dis* **15**: 63–71
- Naidoo DP (1993) Right sided endocarditis in the non-drug addict. *Postgrad Med J* **69**: 615–20
- Nandakumar R, Raju G (1997) Isolated tricuspid valve endocarditis in non-addicted patients: a diagnostic challenge. *Am J Med Sci* **314**: 207–12
- Panidis IP, Kotler MN, Mintz GS, Segal B, Ross JJ (1984) Right heart endocarditis: clinical and echocardiographic features. *Am Heart J* **107**: 759–64
- Robbins MJ, Frater RW, Soeiro R, Frishman WH, Strom JA (1986) Influence of vegetation size on clinical outcome of right sided infective endocarditis. *Am J Med* **80**: 165–71
- Working party of the British Society for Antimicrobial Chemotherapy (1997) Antibiotic treatment of streptococcal, enterococcal and staphylococcal endocarditis. British Society for Antimicrobial Chemotherapy, London: 207–10