

Post-intubation tracheal stenosis

I Ahmad, AL Pahor

INTRODUCTION

Ventilatory support is frequently employed in the management of critically ill patients. This may be life saving, but several adverse effects have been recognized. These include damage to larynx and trachea from the prolonged use of endotracheal and tracheostomy tubes. Tracheal stenosis has been described in about 19% of critically ill patients requiring prolonged endotracheal intubation (Stauffer et al, 1981).

DISCUSSION

Prolonged pressure on the structures of the upper respiratory tract, caused either by the tube itself or more likely the cuff, causes mucosal oedema which may progress to ulceration. This later heals by granulation with the development of fibrotic scar tissue. The commonly involved mucosal sites are posterior aspects of vocal cords, subglottic space and the site at

the level of the cuff in the trachea. The onset of tracheal stenosis has been described from 2 to 24 weeks following extubation (Ching et al, 1974).

The other factors increasing the risk of mucosal damage include an episode of hypotension during which mucosal blood flow is compromised and tracheitis caused by pooling of infected material above the cuff. It has been shown that by using high-volume pre-shaped low-pressure cuffs made of non-irritant material, the severity of tracheal injury can be minimized (Grillo et al, 1971).

Diagnosis of tracheal stenosis is clinical, helped by the flow-volume loop measurements. The latter shows severe reduction of flow at all lung volumes during both inspiration and expiration with a 'plateau' typical of large airway obstruction. Flexible fibreoptic bronchoscopy, a standard diagnostic utility frequently employed in care of the crit-

ically ill patients (Tai, 1998), allows direct inspection of the upper and lower airway to localize the site of obstruction. Laryngotracheal tomograms are useful to determine the extent of lesions and planning the treatment.

In early cases the use of systemic corticosteroids and antibiotics have been very helpful (Braidley et al, 1989). This regimen may influence the inflammatory response and preclude the need for reconstructive surgery. Laser ablation of the granulations is also a treatment option. However, once established, tracheal stenosis is usually treated surgically (Grillo, 1982). Repair involving the subglottic area is much more difficult than of the trachea

CASE REPORT

A 42-year-old insulin-dependent diabetic woman was admitted in the intensive care unit with aspiration pneumonia following an episode of hypoglycaemia. She was managed by mechanical ventilation with endotracheal intubation. During her stay she had a pulmonary embolism for which she was heparinized. Myocardial infarction further delayed her weaning from the ventilator. She remained intubated for 11 days. She was discharged after 3 weeks hospital stay, in a satisfactory condition.

After 3 weeks, she presented as an ear, nose and throat emergency with breathing difficulty. She was found to have biphasic stridor and arterial oxygen saturation concentration ranged from 70 to 80%. Flexible naso-laryngoscopy showed normal vocal cords. A plain X-ray lateral view of the neck showed narrowing of the air column in the upper trachea. Her flow-volume curve showed features of severe tracheal obstruction with a reduction in peak expiratory and inspiratory flow. All routine blood tests and chest X-ray were normal. She was managed by humidified oxygen, intravenous hydrocortisone (100 mg three times a day) and co-amoxiclav (1.2 g three times a day). She responded to this treatment very well.

A tomogram of larynx and trachea performed the next day showed a narrowing of the upper tracheal lumen (Figure 1). Flexible bronchoscopy showed a ring of granulations, resulting in a circumferential narrowing of the upper trachea of 2–2.5 cm in length.

She settled with conservative treatment. Serial flow-volume curve measurements also showed a significant improvement. She was discharged after a week and maintained on a reducing dose of oral steroids for 2 weeks. She is still under close follow-up.

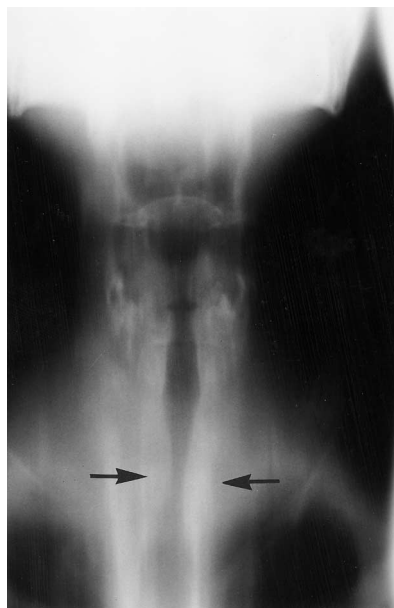


Figure 1. A coronal laryngotracheal tomogram showing narrowing (arrows) of the upper tracheal lumen.

Mr I Ahmad is Registrar and Mr AL Pahor is Consultant in the Department of Otolaryngology, City Hospital, Birmingham B18 7QH

Correspondence to: Mr I Ahmad, 26 Paganal Drive, Dudley DY1 4AY

alone (Mathisen and Grillo, 1994). Therefore it is important to determine the site of lesion by radiological and endoscopic methods.

CONCLUSIONS

This case highlights the importance of early detection of this potentially serious complication. The diagnosis is clinical helped by flow-volume loop measurements, tomography and flexible bronchoscopy. The latter is a commonly used diagnostic and therapeutic

tool for examination of upper and lower airways in critically ill patients. In cases of prolonged endotracheal intubation, flexible bronchoscopy should be considered before the patient is discharged from the intensive care unit. **HM**

Braidy J, Breton G, Clement L (1989) Effects of corticosteroids on post-intubation tracheal stenosis. *Thorax* **44**: 753-5
Ching NPH, Ayres SM, Spina RC, Nealton TF (1974) Endotracheal damage during continuous ventilatory support. *Ann Surg* **179**: 123-7
Grillo HC, Cooper JD, Geffin B, Pontoppidan H (1971) A low-pressure cuff for tracheostomy

tubes to minimise tracheal injury. A comparative clinical trial. *J Thorac Cardiovasc Surg* **62(6)**: 898-907

Grillo H (1982) Primary reconstruction of airway after resection of subglottic laryngeal and tracheal stenosis. *Ann Thorac Surg* **33**: 3-18

Mathisen D, Grillo HC (1994) The trachea. In: Morris PJ, Malt RA, eds. *Oxford Textbook of Surgery*. Vol 2. Oxford Medical Publications, New York: 1884-6

Stauffer J, Olson D, Petty T (1981) Complications and consequences of endotracheal intubation and tracheostomy. A prospective study of 150 critically ill patients. *Am J Med* **70**: 65-76

Tai DY (1998) Bronchoscopy in the intensive care unit. *Ann Acad Med Singapore* **27(4)**: 552-9
