

Nasogastric tube insertion using flexible fiberoptic nasendoscope

YG Karagama, JL Lancaster, A Karkanevatos

The insertion of a nasogastric tube, especially a fine bore feeding tube, can occasionally be problematic because of an anatomical variation or pathology. A method of passing an nasogastric tube under direct vision using a flexible fiberoptic nasendoscope introduced through the nostril is described, which is reserved for cases where traditional methods of insertion failed.

The insertion of a nasogastric tube (NGT) is common practice in most branches of medicine. It can occasionally be problematic either because of an anatomical variation or pathology. This article describes a simple and safe bedside method of passing a nasogastric tube with certainty of entering the oesophagus.

MATERIALS AND METHODS

The insertion of a fine bore NGT under direct vision using a flexible fiberoptic nasendoscope (Olympus ENF-P3, Optor-Electronics Co Ltd, Japan) was demonstrated in a healthy volunteer.

The subject was seated in an upright position and facing the examiner. A lubricated nasendoscope was passed through the right nostril after spraying the nasal cavity with a local anaesthetic agent (Cophenylcaine, lidocaine 5% and phenylephrine hydrochloride 0.5%). The

nasendoscope was then advanced until the epiglottis, the vocal cords and the oesophageal inlet came into direct view (Figure 1). A lubricated NGT was passed through the same nostril (the contralateral nostril may be used) and below the nasendoscope. The NGT was then manipulated under direct vision and guided into the oesophageal inlet (Figure 2). It was then advanced until the appropriate length had gone into the stomach according to the mark on the NGT (usually 50 cm).

Using a litmus paper test, the NGT was confirmed to be in the stomach. Because the passage into the oesophagus was visualized, it was not necessary to carry out an X-ray.

DISCUSSION

In most cases where an NGT is required, conventional methods of insertion by means of a 'push and swallow' technique at the bedside are

Figure 1. The oesophageal inlet as seen through the fiberoptic nasendoscope.

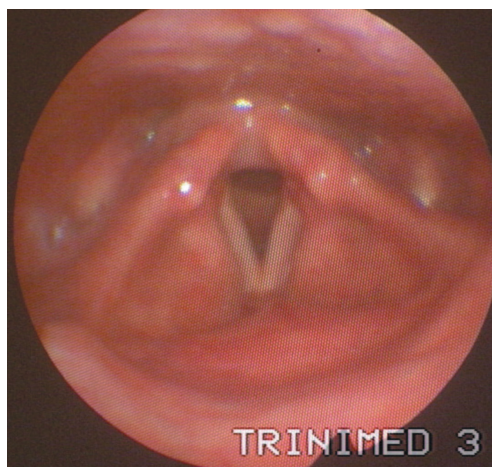
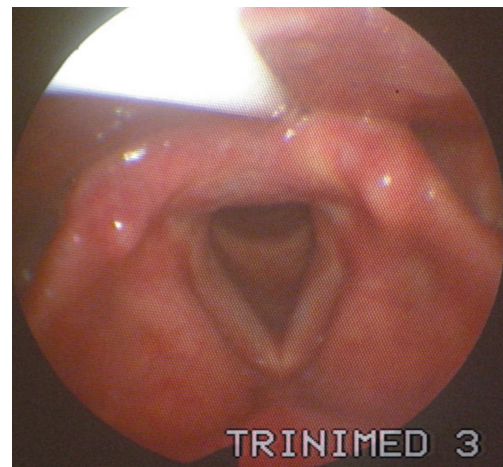


Figure 2. Showing the nasogastric tube as it enters the oesophageal inlet.



Mr YG Karagama is Senior House Officer, Mr JL Lancaster is Specialist Registrar and Mr A Karkanevatos is Specialist Registrar in the Department of Ear, Nose and Throat, Arrowe Park Hospital, Wirral CH49 5PE

Correspondence to: Mr YG Karagama

adequate. When this fails, physicians are left with few options. Occasionally, success can be achieved by passing them under radiological surveillance, but if this is unsuccessful, endoscopically aided insertion is required. In patients with pathological narrowing resulting from tumour or stricture, endoscopy is often indicated anyway for the purpose of gaining a diagnosis.

Problems arise in patients in whom difficulty in passing an NGT results from either awkward anatomy (e.g. kyphosis, nasal septal deviation, cervical osteophytes) or impaired swallowing reflexes secondary to neurological pathology (e.g. cerebrovascular accident, bulbar palsy, pseudo-bulbar palsy). Several different methods and manoeuvres have been described for insertion in difficult patients, but all refer to the anaesthetized or unconscious patient (Conway and Cohen, 1971; Sprague and Carter, 1980; Perel et al, 1985; Campbell, 1997).

CONCLUSION

This method of insertion is presented as a simple bedside procedure that can be carried out on most adult patients irrespective of their

level of consciousness. Neither general anaesthesia nor sedation is required. This method results in the certainty that incorrect positioning of the tube into the tracheobronchial tree does not occur in a comatose or desensitized patient. **HM**

Conflict of interest: none.

- Campbell B (1997) A novel method of nasogastric tube insertion. *Anaesthesia* **52**(12): 1234
Conway K, Cohen DD (1971) Nasogastric tube insertion. *Anaesth Analg* **50**: 1010-1
Perel A, Ya'ara Y, Pizov R (1985) Forward displacement of the larynx for nasogastric tube insertion in intubated patients. *Crit Care Med* **13**: 204-5
Sprague DH, Carter SR (1980) An alternate method for nasogastric tube insertion. *Anaesthesiology* **53**: 436

KEY POINTS

- The use of nasogastric tubes is essential for providing nutrition to certain groups of medical and surgical patients.
- Its passage can result in serious lung complications if not done properly.
- Medical personnel who pass a nasogastric tube should be aware of this safe method of passing difficult nasogastric tubes.