

Neuroimaging in schizophrenia: from theory to practice

Jessica Sheringham, Veena Kumari, Alexander Sumich, Tonmoy Sharma

Schizophrenia is a serious mental illness that affects 1% of the population. It is beset with problems of diagnosis and difficulties in assessing treatment. Neuroimaging has long contributed to our understanding of schizophrenia but recent developments suggest it may ultimately play a practical role in its early detection and management.

Schizophrenia affects 1% of the population at some point during life (National Schizophrenia Fellowship Factsheet, 2001). A chronic and sometimes disabling condition, the illness has implications not just for those with schizophrenia but also their families and close friends.

Clinical management of schizophrenia is complicated by the fact that diagnosis and assessment can be problematic; loss of insight into one's symptoms is a primary sign of the illness and positive symptoms – hallucinations and delusions – often fluctuate during its course.

Reliable and specific biological markers such as structural, chemical and functional brain changes promise to improve diagnosis and assessment of symptoms of schizophrenia. Finding markers that signal the development of schizophrenia, however, is still beset by problems of ease of testing, predictability and specificity of test results (Copolov and Crook, 2000).

Neuroimaging techniques have revolutionized the study of schizophrenia; findings dating from the 1970s have demonstrated that there are clear brain structural abnormalities associated with the condition (Johnstone, 1976). Recent magnetic resonance imaging (MRI) research from the authors' research group has identified brain characteristics associated with the early stages of psychosis and studies using functional MRI (fMRI) have shown the effects of medication in the brain.

This article discusses how findings such as these indicate that neuroimaging techniques may prove useful in identifying biological markers and could ultimately act as aids to diagnosis and treatment selection in schizophrenia.

SCHIZOPHRENIA: CLINICAL CHALLENGES

'An essential part of the treatment of people who have schizophrenia must be to inform them of their diagnosis'
(Clafferty et al, 2000).

Although the nature of schizophrenia and the validity of diagnosis is always a matter of debate, many patients with any condition find that diagnosis is useful for providing some explanation of how they are feeling. While some argue that the term schizophrenia 'has increasingly taken on negative connotations' (Bracken et al, 2000), unexplained hallucinations, delusions, social withdrawal and cognitive problems can be immensely distressing for those affected as well as their close friends and family. For clinicians, some degree of diagnosis – whether of psychosis or schizophrenia – is often the first step to choosing an appropriate course of treatment.

Symptom fluctuations, loss of insight in patients and the controversies surrounding the nature of schizophrenia make diagnosis difficult with current clinical tools (usually based on assessment scales, clinical and carers' impressions). In addition, once a treatment course is decided upon, these same factors can complicate any assessment of response to treatment.

Biological markers for schizophrenia would greatly aid the diagnostic process and the assessment of treatment response. Indeed, many abnormalities, such as ventricular enlargement, dopamine D2 receptor density, amphetamine-stimulated central nervous system dopamine release, plasma homovanillic acid and smooth pursuit eye tracking dysfunction, are present in people experiencing their first episode of psychosis who later develop schizophrenia. But, in

Ms Jessica Sheringham is Project Director, Zeus Research Ltd, London,
Dr Veena Kumari is Beit Memorial Research Fellow with Senior Lecturer Status,
Dr Alexander Sumich is Research Worker and
Dr Tonmoy Sharma is Director of Clinical Neuroscience Research Centre, Stonehouse Hospital, Dartford, Kent DA2 6AU

Correspondence to:
Dr T Sharma

isolation, these 'abnormalities' lack specificity, that is, many are also present in those who do not develop schizophrenia but go on to develop other disorders (Copolov and Crook, 2000). Greater potential from biological markers for schizophrenia may come from the combination of assessment techniques, with imaging techniques adding the crucial ingredient of high resolution structural and functional assessment of brain regions.

STRUCTURAL BRAIN CHARACTERISTICS OF EARLY PSYCHOSIS

Structural studies of the brain in schizophrenia have reported many areas to be abnormal, the most robust findings being ventricular enlargement and loss of temporal lobe matter (McCarley et al, 1999; Wright et al, 2000). A number of other changes have also been reported, but with less consistency. While a full discussion of these is beyond the scope of the current article, useful papers on the subject include Wright et al (2000) and McCarley et al (1999).

Many imaging studies on schizophrenia to date have been conducted using patients with chronic schizophrenia. Studies of chronic patients, however, are susceptible to possible confounding effects of long-term institutionalization, neuroleptic exposure or neurodegenerative change. It is, therefore, hard to know whether observed brain changes are caused by these factors or the effects of the illness itself. By studying patients within their first episode of psychosis such confounding effects may be lessened, making findings more representative of the illness. In addition, while many of those in their first episode of psychosis may not experience another episode within 5 years, chronically ill patients recruited for studies usually represent a subset of schizophrenia with a particularly severe and enduring form of the illness.

An MRI study conducted by the authors' research group recruited a select group of first-episode psychosis patients. The study participants had little or no experience of antipsychotic medication and, unlike other first-episode studies, most of these patients had less than 6 months' experience of psychosis (Fannon et al, 2000a).

Researchers found that even at this early stage of illness, patients already showed a range of structural brain changes. Findings included deficits in temporal lobe (gray matter, superior temporal gyrus and hippocampus; Sumich et al, 2000), reduced whole brain volume, significant enlargement of lateral and third ventricles, and reduced thalamic volume (Fannon et al, 2000a; Ettinger et al, 2001).

Thalamic abnormalities are of particular interest in schizophrenia. The thalamus is associated with filtering sensory information, and has been called the brain's 'communication hub'. Because problems of information filtering, reflected as disturbed thought processes, are characteristic of schizophrenia, a defect in the structure or function of all or part of the thalamus may be central to the pathogenesis of schizophrenia (Andreasen, 1997). Supporting the theory that the thalamus plays a key role in schizophrenia, reduced thalamic volumes are found in patients with early psychosis (Ettinger et al, 2001). It has also been shown that this is not related to treatment or symptoms, but instead appears to be an indicator, or a function, of early psychosis.

The finding that significant diverse differences in brain structure are present and even diagnosable before schizophrenia supports the neurodevelopmental hypothesis, i.e. schizophrenia is an illness marked by problems in brain development before psychotic symptoms are evident. Schizophrenia may also involve a two or three 'hit' process. One theory suggests that in those who progress to a chronic form of schizophrenia, an early neurodevelopment lesion (first hit) affects certain brain structures, such as the left hippocampus and left planum temporale. This 'hit' is followed by a second and even third hit, resulting in further neurodegeneration of other brain regions (Velakoulis et al, 2000). MRI allows researchers to test these theories and identify brain regions particularly susceptible to progressive neural changes which may take place during different stages of the illness (Mathalon et al, 2001).

The authors' research group also studied the relationship between two potential preclinical markers of schizophrenia; third ventricle enlargement – a specific and robust regional brain change noted in schizophrenia – was examined in relation to problems in childhood development, an early warning sign of future schizophrenia. Those patients who experienced developmental problems in childhood (for example, delayed progress in speaking, walking or reading), also showed significant enlargements of the third ventricle (Fannon et al, 2000b). This research is consistent with other findings that indicate that those at high genetic risk of schizophrenia also show ventricle enlargement and behavioural abnormalities (Dykes et al, 1992).

FUNCTIONAL MRI IN SCHIZOPHRENIA

Since the late 1990s, fMRI has become the 'procedure of choice' for studying brain function in schizophrenia (Meltzer et al, 1999) and has

been employed to localize brain regions linked to cognitive deficits and/or symptoms. It has also proved useful for visualizing treatment response.

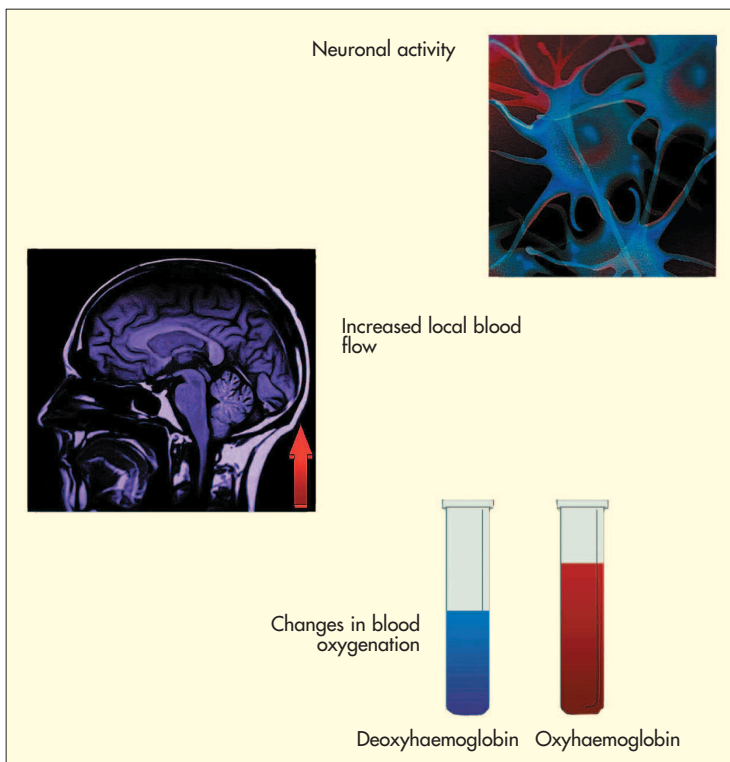
How it works

Blood oxygenation level-dependent (BOLD) imaging is the most common form of fMRI. The employment of this technique relies on the supposition that when neural activity increases, the flow of oxygenated blood to that particular region also increases. Because the supply of oxygenated blood outstrips demand for oxygen, it is possible to detect an excess of the amount of oxygenated blood compared with deoxygenated blood. The resulting change in the ratio of deoxyhaemoglobin to oxyhaemoglobin causes an increase in the magnetic resonance signal (*Figure 1*). The signal can then be mapped onto an anatomical scan to indicate the location of increased activity.

Advantages of fMRI

fMRI can be carried out in the same session as routine MRI using a clinical scanner, allowing both structural and functional information to be collected in the same visit. The process usually involves measuring the changes in cerebral blood flow (changes in the BOLD signal) while people are engaged in covert or overt responses (Longworth et al, 1999).

Figure 1. Principles of functional magnetic resonance imaging.



fMRI studies have enhanced the theoretical understanding of schizophrenia by identifying neural structures associated with observed cognitive problems and symptoms. For example, fMRI scans performed during working memory tasks (such as the two back or continuous performance test) have recorded reduced activity in frontal areas of the brain such as the dorsolateral prefrontal cortex. Also, Woodruff et al (1997) applied fMRI to localize neural correlates of auditory hallucinations to the temporal cortex.

fMRI has a spatial resolution within millimetres and it can capture responses in the brain over a few seconds (although analysis takes longer). Unlike older techniques such as positron emission tomography or single photon emission tomography, fMRI does not require radioactivity, instead it tracks the brain's natural response to neural activity by detecting changes in blood flow. This means that fMRI is a non-invasive and relatively safe technique, making it possible to repeat scans on the same individual as often as necessary. This allows researchers to track changes in the brain over time and monitor the response to treatment.

In a study of men switched from typical antipsychotics to an atypical drug, risperidone, fMRI indicated that atypical antipsychotics could restore activity in frontal areas of the brain, regions that are crucial for many thought processes (Honey et al, 1999). Men performed a working memory task in the scanner at baseline while on typical antipsychotics and 6 weeks after the commencement of atypical antipsychotic treatment. Risperidone restored frontoparietal activation (noted in controls, but not in patients during the baseline) as compared to the activation seen at baseline while the patients were on conventional antipsychotics. There was significantly greater change from baseline after 6 weeks in patients who were switched to risperidone than in those who remained on conventional antipsychotics.

These data provide the first direct evidence of enhanced prefrontal and premotor function following substitution of typical antipsychotics by risperidone. They also highlight the potential value of fMRI as a tool for longitudinal assessment of the effects of new pharmacological treatments. fMRI in this instance has allowed researchers to demonstrate differences between the effects of drug treatments on brain regions involved in cognition. Future studies could also examine its usefulness in monitoring and evaluating neurobiological responses to psychosocial therapies such as cognitive-behavioural therapy, which has shown promise in schizophrenia.

Limitations of fMRI

Although a promising technique, fMRI's use is still limited to research for several reasons. For example, the relationship between the BOLD signal and brain activation has still not yet been conclusively elucidated. Even assuming that theoretical assumptions underlying fMRI are correct, however, there are several practical and technical obstacles to be overcome before the technique can be clinically useful. Some older MRI machines are not capable of performing functional imaging. In addition, fMRI is also still relatively new in schizophrenia. Sample sizes used are often small (i.e. under 20 participants) and the lack of standardized methods of analysis have led to some conflicting results. Furthermore, the technique can produce artefacts, for example, movement of subjects in the scanner produces signal changes that mimic changes in neuronal activity (Callicott et al, 1998). Further research, from many fields including psychological, engineering and biostatistical sciences, is needed to iron out these problems.

CONCLUSION

Neuroimaging, in combination with other psychophysiological, clinical, social, behavioural and cognitive techniques has potential as a useful biological marker for the detection and assessment of schizophrenia. Research findings suggest that brain abnormalities detected on MRI may become powerful predictors of future psychosis. Its benefit in other fields is evident – MRI is increasingly used clinically on patients with other brain disorders, such as stroke, and for planning neurosurgery.

While fMRI is still some way off clinical use with schizophrenia, its benefits – safety, resolution and speed – have led to exciting information about the illness and the effects of treatment. It may ultimately prove a useful tool for determining treatment choice. **HM**

Figure 1 is adapted with permission from Longworth et al (1999).

Conflict of interest: none.

Andreasen N (1997) The role of the thalamus in schizophrenia. *Can J Psychiatry* **42**: 27–33
Bracken P, Thomas P, King J et al (2000) Treatment of schizophrenia. *Br Med J* **320**: 800
Callicott JH, Ramsey NF, Tallent K et al (1998) Functional magnetic resonance imaging brain mapping in psychiatry: methodological issues illustrated in a study of working memory in schizophrenia. *Neuropsychopharmacology* **18**: 186–96
Clafferty RA, McCabe E, Brown KW (2000) Telling patients with schizophrenia their diagnosis. Patients should be informed about their illness. *Br Med J* **321**: 384–5
Copolov D, Crook J (2000) Biological markers and schizophrenia. *Aust NZ J Psychiatry* **34** (Suppl): S108–12
Dykes KL, Mednick SA, Machon RA, Praestholm J, Parnas J

(1992) Adult third ventricle width and infant behavioral arousal in groups at high and low risk for schizophrenia. *Schizophr Res* **7**: 13–8
Ettinger U, Chitnis X, Kumari V et al (2001) Magnetic resonance imaging of the thalamus in first episode psychosis. *Am J Psychiatry* **158**: 116–18
Fannon D, Chitnis X, Doku V et al (2000a) Features of structural brain abnormality detected in first-episode psychosis. *Am J Psychiatry* **157**: 1829–34
Fannon D, Tennakoon L, Sumich A et al (2000b) Third ventricle enlargement and developmental delay in first-episode psychosis: preliminary findings. *Br J Psychiatry* **177**: 354–9
Honey GD, Bullmore ET, Soni W, Varatheesan M, Williams SC, Sharma T (1999) Differences in frontal cortical activation by a working memory task after substitution of risperidone for typical antipsychotic drugs in patients with schizophrenia. *Proc Natl Acad Sci USA* **96**: 13432–7
Johnstone EC, Crow TJ, Frith CD, Husband J, Kreel L (1976) Cerebral ventricular size and cognitive impairment in chronic schizophrenia. *Lancet* **ii**: 924–6
Longworth C, Honey G, Sharma T (1999) Science, medicine, and the future: functional magnetic resonance imaging in neuropsychiatry. *Br Med J* **319**: 1551–4
Mathalon DH, Sullivan EV, Lim KO, Pfefferbaum A (2001) Progressive brain volume changes and the clinical course of schizophrenia in men: a longitudinal magnetic resonance imaging study. *Arch Gen Psychiatry* **58**: 148–57
McCarley RW, Wible CG, Frumin M et al (1999) MRI anatomy of schizophrenia. *Biol Psychiatry* **45**: 1099–119
Meltzer HY, Park S, Kessler R (1999) Cognition, schizophrenia, and the atypical antipsychotic drugs. *Proc Natl Acad Sci USA* **96**: 13591–3
National Schizophrenia Fellowship Factsheet (2001) http://www.nsf.org.uk/information/whatis_schiz_01.html (accessed May 2001)
Sumich A, Chitnis XA, Lowe J et al (2000) Temporal lobe structures, symptomatology and first-episode psychosis. *Schizophrenia Res* **41**: 113–14
Velakoulis D, Wood SJ, McGorry PD, Pantelis C (2000) Evidence for progression of brain structural abnormalities in schizophrenia: beyond the neurodevelopmental model. *Aust NZ J Psychiatry* **34** (Suppl): S113–26
Woodruff PW, Wright IC, Bullmore ET et al (1997) Auditory hallucinations and the temporal cortical response to speech in schizophrenia: a functional magnetic resonance imaging study. *Am J Psychiatry* **154**: 1676–82
Wright IC, Rabe-Hesketh S, Woodruff PW, David AS, Murray RM, Bullmore ET (2000) Meta-analysis of regional brain volumes in schizophrenia. *Am J Psychiatry* **157**: 16–25

KEY POINTS

- Schizophrenia is a serious mental illness that affects 1% of the population.
- The clinical management of schizophrenia is complicated by problems diagnosing and assessing the condition partly because there are currently no reliable, specific biological markers for schizophrenia.
- Magnetic resonance imaging (MRI) of early psychosis, before schizophrenia has been diagnosed, indicates that structural changes in key areas of the brain are already evident.
- Brain changes detected by MRI may prove useful in early diagnosis of schizophrenia.
- Functional MRI is a new and useful technique that has improved the theoretical understanding of schizophrenia and that has shown promise as a tool for tracking treatment response.
- There are theoretical, technical and practical obstacles to be overcome before functional MRI can be useful as a clinical tool.
- Neuroimaging techniques in combination with other clinical, social, behavioural and cognitive techniques may provide useful biological markers for the detection, and assessment of schizophrenia.