

Department of Pharmaceutical Technology¹, Department of Pharmacology², Anadolu University, Faculty of Pharmacy; Department of Histology³, Osmangazi University, Faculty of Medicine, Eskişehir, Turkey

Chitosan gel formulations containing egg yolk oil and epidermal growth factor for dermal burn treatment

E. YENILMEZ¹, E. BAŞARAN¹, R. ARSLAN², M. S. BERKMAN¹, U. M. GÜVEN¹, C. BAYÇU³, Y. YAZAN¹

Received August 27, 2014, accepted October 5, 2014

Assist. Prof. Evrim Yenilmez, Department of Pharmaceutical Technology, Faculty of Pharmacy, Anadolu University, 26470, Eskişehir, Turkey

Pharmazie 70: 67–73 (2015)

doi: 10.1691/ph.2015.4126

In the present study chitosan based gel formulations containing Egg Yolk Oil (EYO) and Epidermal Growth Factor (EGF) were formulated successfully aiming at enhanced topical treatment of dermal burns the combination of traditional approaches with modern drug delivery systems. Physicochemical properties of the formulations were analyzed and efficacy of the formulations prepared were evaluated *versus* a commercial product; Silverdin® (1% silver sulfadiazine) *in vivo* on Wistar rats. Burns were generated on the back of the rats and at predetermined time intervals tissue samples were collected and evaluated histologically. The analyses showed that chitosan based gel formulations containing Egg Yolk Oil (E1) and chitosan based gel formulations containing EYO and EGF (M1) formulations seem to be better alternatives for Silverdin® with a significant difference ($p < 0.05$) considering healing ranks of tissue samples.

1. Introduction

Burned skin requires particular care like being subject to slings and arrows, which can span from denaturation of skin's proteins to coagulative necrosis depending on the burn depth degree (Vujanovic and Vujanovic 2013). In burn treatment whether and to what degree the patient is enabled to enjoy a normal quality of life becomes more and more essential in how the outcome of the treatment is evaluated (Haslik et al. 2007). There are many approaches in burn wound healing both biologic and non-biologic originated (Selig et al. 2012). Most preferred approaches are the delivery of epidermal autografts (Cirodde et al. 2011; Wang et al. 2014), allografts (Cleland et al. 2014; Groeber et al. 2011), xenografts (Hermans 2014) and acellular biosynthetic, full-synthetic and non-biologic wound dressings (Verbelen et al. 2014; Frew et al. 2013). However, in the process of designing products to facilitate the regeneration of skin, several engineering principles are critical (Orgill and Gobble 2014). The primary aim of treatment of burns is to prevent infection, then to promote proliferation of epithelial cells (Wang et al. 2012). Therefore materials that approximate the water vapor transmission rate of intact stratum corneum are desirable and materials also must be biocompatible: nontoxic, noninflammatory, nonimmunogenic and not contain microbiological residues. Critical mechanical properties like strength, modulus of elasticity and drapeability also must be considered (Orgill and Gobble 2014).

The application of natural polymers with different mechanical, physical and biological properties as wound dressings has been widely studied based on the many advantages of these macromolecular agents to simulate the extracellular matrix regeneration after injury (Dantas et al. 2011; Moura et al. 2014). One of the most preferred naturally based polymers for wound healing applications is chitosan (Moura et al. 2014; Mi et al. 2003; Aoyagi et al. 2007; Ji et al. 2012). Chitosan, $\alpha(1-4)-2$ -

amino-2-deoxy β -D-glucan, is a deacetylated form of chitin, an abundant polysaccharide present in crustacean shells (Hamidi et al. 2008). Chitosan has prerequisite distinctive properties such as biocompatibility, biodegradability with non-irritant and non-toxic character which make it an attractive candidate for pharmaceutical and biomedical applications (Dantas et al. 2011; Tsao et al. 2011; Başaran and Yazan 2012). Good hemostatic properties and intrinsic antibacterial characters as well as unique tissue-adhesive properties due to its polycationic nature, makes the wound dressing one of the most promising medical applications for chitosan (Aoyagi et al. 2007; Hoemann et al. 2005, Jayakumar et al. 2011, Lin et al. 2013). It was reported that simulation of the migration of polymorphonuclear as well as mononuclear cells and acceleration of the re-epithelization and normal skin regeneration is the mechanism of action of chitosan in tissue engineering (Fouda et al. 2009).

Local treatment revealed the use of many traditional approaches like the use of herbal mixtures, oils, honey, egg yolk and egg yolk oil (EYO) (Vujanovic and Vujanovic 2013; Kopp et al. 2003; Albertyn et al. 2006; Rastegar et al. 2011; Sadeghi Bazargani et al. 2013). Among these approaches the efficacy of EYO was scientifically documented (Rastegar et al. 2011; Mahmoudi et al. 2013).

Epidermal growth factor (EGF) is a mitogenic peptide that is secreted into the lumen of the duodenum by Brunner's glands. EGF is implicated in the regulation of a wide variety of physiological processes, including growth, cell proliferation, regeneration, differentiation, and wound repair (Yildirimer et al. 2012; Arda-Pirincci and Bolkent 2014; Jin et al. 2013). EGF stimulates messenger RNA, DNA, and protein synthesis in many cell types and has also been also shown to stimulate keratinocyte division *in vitro* and epidermal regeneration *in vivo* (Jahovic et al. 2004).

In the present study chitosan based gel formulations containing EYO and EGF were formulated for the enhanced topical

Table 1: Changes in pH values of the gel formulations prepared during the storage period of 6 months (mean ± SE; RH = relative humidity)

Storage Condition	Storage Day	Formulations					
		F1	F2	F3	F4	E1	M1
		pH Values					
	0	5.53 ± 0.05	5.46 ± 0.01	5.41 ± 0.01	5.32 ± 0.05	5.25 ± 0.01	5.28 ± 0.01
25 ± 1 °C	30	5.55 ± 0.01	5.44 ± 0.02	5.43 ± 0.02	5.38 ± 0.02	5.25 ± 0.01	5.27 ± 0.01
	90	5.56 ± 0.01	5.46 ± 0.01	5.45 ± 0.05	5.33 ± 0.02	5.26 ± 0.01	5.28 ± 0.00
	180	5.28 ± 0.01	4.76 ± 0.01	4.28 ± 0.01	3.95 ± 0.00	–	–
4 ± 1 °C	30	5.53 ± 0.01	5.46 ± 0.00	5.41 ± 0.01	5.32 ± 0.00	5.29 ± 0.01	5.21 ± 0.01
	90	5.53 ± 0.03	5.46 ± 0.00	5.41 ± 0.00	5.32 ± 0.01	5.27 ± 0.01	5.24 ± 0.01
	180	5.41 ± 0.01	4.56 ± 0.00	4.76 ± 0.01	4.84 ± 0.01	–	–
40 ± 1 °C	30	5.52 ± 0.02	5.45 ± 0.01	5.41 ± 0.02	5.36 ± 0.02	5.30 ± 0.01	5.25 ± 0.01
	90	5.50 ± 0.01	5.44 ± 0.02	5.41 ± 0.02	5.38 ± 0.01	5.36 ± 0.01	5.27 ± 0.00
	180	5.41 ± 0.01	4.56 ± 0.03	4.76 ± 0.01	4.84 ± 0.01	–	–
40 ± 1 °C 60% RH	30	5.49 ± 0.01	5.47 ± 0.01	5.43 ± 0.01	5.33 ± 0.05	5.24 ± 0.01	5.31 ± 0.00
	90	5.52 ± 0.05	5.48 ± 0.05	5.44 ± 0.01	5.38 ± 0.01	5.20 ± 0.01	5.23 ± 0.00
	180	5.51 ± 0.03	5.56 ± 0.03	5.76 ± 0.01	4.98 ± 0.01	–	–

treatment of dermal burns. Physicochemical properties of the formulations were analyzed and efficacy of the formulations prepared were evaluated *versus* the commercial product Silverdin® (1% silver sulfadiazine) with *in vivo* studies.

2. Investigations and results

2.1. In vitro analyses

Chitosan gel formulations (F1, F2, F3 and F4) were prepared successfully and the formulations were kept at 4 different conditions (25 ± 1 °C, 4 ± 1 °C, 40 ± 1 °C and 40 ± 1 °C + 60% RH) for better evaluation of the stability of the chitosan gel during the storage period of 6 months. Stability of the gel formulations were evaluated due to the changes in pH values and the results showed that differences in pH values of the formulations (Table 1). Among the 4 formulations prepared, initial pH value of F1 formulation second to be unchanged (Table 1). Therefore gel composition of F1 was selected for further *in vivo* studies. EYO was added to F1 in a final concentration of 100 µg·mL⁻¹ named as “E1” formulation and combination of two active materials EYO and EGF solution were also added to the selected F1 formulation up to the final concentration of 100 µg·mL⁻¹ and 10 µg·mL⁻¹ respectively named as “M1” formulation. E1 and M1 formulations were kept at different temperatures (25 ± 1 °C, 4 ± 1 °C, 40 ± 1 °C and 40 ± 1 °C + 60% RH) for the period of 3 months.

Changes in pH values were monitored (Table 1) and the rheological analyses were conducted on E1 and M1 formulations during the storage period of 3 months (Table 2).

2.2. Wound healing

Burn was created by using hot stamp (150 mm diameter, 30 g) at 85 °C for 20 s and the wound healing efficacy of the formulations were assessed by measuring the diameter of the wound by a digital caliper. Progressive changes in burn areas were observed at the 1st, 7th 14th and 21st days of treatment. Wound contraction analyses results shown in Fig. 1.

For all the formulations applied, no significant wound contraction was observed at the 1st and 7th days of treatment however, EYO, E1 and M1 showed significant wound contraction data in comparison with Silverdin®, as well as placebo chitosan gel group and control group (no treatment applied) especially after

Table 2: Rheological analyses of the E1 and M1 formulations during the storage period of 3 months (RH = relative humidity)

Storage Condition	Storage Day	Formulations	
		E1	M1
		mPa	
	0	8296	7912
25 ± 1 °C	30	8296	7906
	60	8376	7915
	90	8388	7915
4 ± 1 °C	30	8311	7918
	60	8324	7955
	90	8332	7987
40 ± 1 °C	30	8267	7921
	60	8234	7903
	90	8236	7906
40 ± 1 °C 60% RH	30	8279	8101
	60	8267	7995
	90	8273	7906

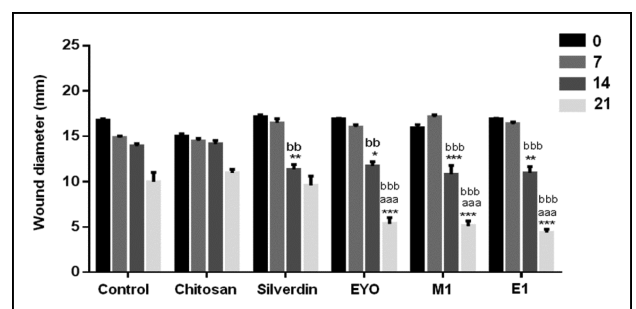


Fig. 1: Wound contraction analyses of the formulations applied [Control: No treatment applied, Chitosan: Placebo chitosan gel, Silverdin®: Commercial product of 1% Silver Sulfadiazine, EYO: Egg yolk oil, M1: Formulation containing EYO and EGF, E1: Formulation containing EYO; *p < 0.05, **p < 0.01, ***p < 0.001: significant difference from the control; aaap < 0.001: significant difference from the Silverdin®, bbp < 0.01, bbpp < 0.001: significant difference from the Chitosan gel. The statistical analyses were performed by two-way ANOVA, followed by Tukey’s multiple comparison tests].

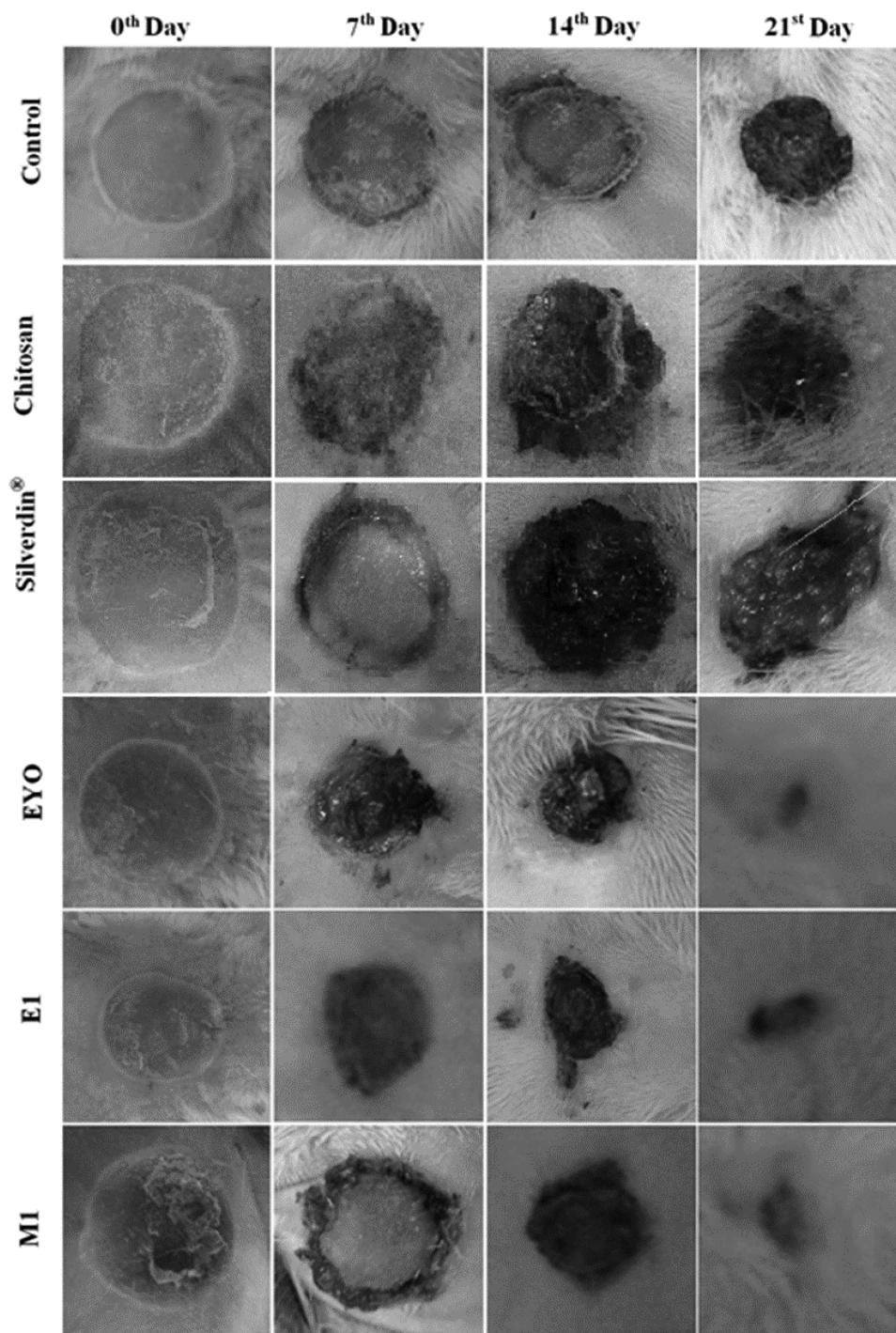


Fig. 2: Digital images of the wounded sites during the 21 day of treatment [Control: No treatment applied, Chitosan: Placebo chitosan gel, Silverdin®: Commercial product of 1% Silver Sulfadiazine, EYO: Egg yolk oil, M1: Chitosan formulation containing EYO and EGF, E1: Chitosan formulation containing EYO].

14 days. Dramatic changes in wound contraction were recorded at the 21st day in favor of EYO, E1 and M1 formulations (Fig. 1). Digital images of the burn wounds were taken at 1st, 7th, 14th and 21st days (Fig. 2). And healing effect of EYO, E1 and M1 formulations were very apparent especially at the 21st day of treatment in comparison with both placebo chitosan gel formulation and Silverdin® (Fig. 2).

2.3. Histological examination

Histological examinations showed that, in the micrographs of the control group (no treatment applied) severe damages in the excised wound sites were detected after 7 days. Separation

between epidermis and dermis was very obvious and integrity of the skin was impaired due to the loss of papillary. Inflammation was very dense and under the burned area (Fig. 3a). Minimal formation of granulation tissue as well as re-epithelialization and formation of collagen fibres were observed after 14 days (Fig. 3b). And at the 21st day, re-epithelialization was not completed and the granulation tissue and collagen fibres were detected (Fig. 3c).

For placebo chitosan gel after 7 days of treatment, impaired histological structure of the skin and dense inflammation cells were observed (Fig. 3d). At the 14th day, impaired structure was not healed totally however minimal formation of granulation tissue and re-epithelialization were observed (Fig. 3e)




Fig. 3: Histological analyses of burned skin samples [Control: No treatment applied, Chitosan: Placebo chitosan gel, Silverdin[®]: Commercial product of 1% Silver Sulfadiazine, EYO: Egg yolk oil, M1: Chitosan formulation containing EYO and EGF, E1: Chitosan formulation containing EYO; samples were stained with Haematoxylen and Eosin].

and after 21 days, enhanced collagen formation and slight re-epithelialization was seen (Fig. 3f).

Impaired tissue layers and inflammation cells due to the burn damage can easily be distinguished at the 7th day of treatment with E1 formulation (Chitosan gel containing EYO) (Fig. 3g). After 14 days, formation of granulation tissue and collagen fibres were very obvious. Incomplete re-epithelialization was also detected (Fig. 3h) however at the 21st day, surprisingly epithelialization was nearly completed and formation of new vein as well as the formation of collagen fibres were detected between the layers (Fig. 3i).

In the EYO group, impaired tissue layers and inflammation cells due to the burn damage were detected at the 7th day (Fig. 3j) and after 14 days, formation of granulation tissue and collagen fibres were very obvious. Incomplete re-epithelialization was also detected (Fig. 3k). Surprisingly at the 21st day, epithelialization was nearly completed and new vein formation with the formation of collagen fibres were detected between the layers (Fig. 3l).

After treatment with M1 formulation, impaired tissue and loss of papillary as well as dense inflammation cells were present in the excised wound site sample (Fig. 3m). At the 14th day, formation of granulation tissue was not completed however re-epithelialization was seen (Fig. 3n). After 21 days of the

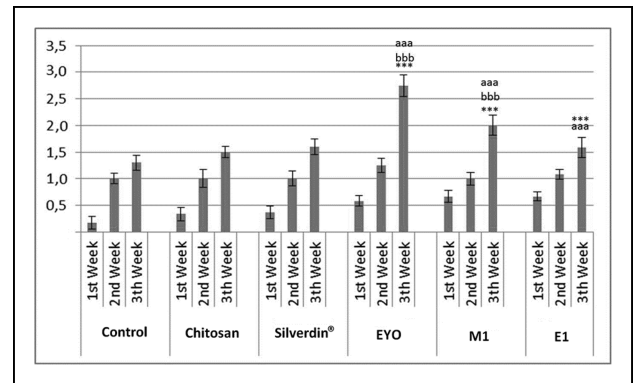


Fig. 4: Statistical analysis of wound healing [Control: No treatment applied, Chitosan: Placebo chitosan gel, Silverdin[®]: Commercial product of 1% Silver Sulfadiazine, EYO: Egg yolk oil, M1: Formulation containing EYO and EGF, E1: Formulation containing EYO; *** $p < 0.001$: Significant difference from control, bbbb $p < 0.001$: Significant difference from chitosan gel, aaaa $p < 0.001$: Significant difference from Silverdin[®]].

treatment, formation of epidermis was nearly completed and granulation tissue was remarkable (Fig. 3o).

In the Silverdin[®] group, after treatment for 7 days, highly damaged and intensely inflamed tissue was observed (Fig. 3p). After 14 days, the damage was still obvious however formation of granulation tissue and incomplete re-epithelialization was seen (Fig. 3r). And at the 21st day, formation of the granulation tissue and increased collagen fibre formation was evident as well as incomplete epithelialization (Fig. 3s).

2.4. Wound healing score

Comparison of histological scores between different groups was carried out by Kruskal-Wallis Variance Analysis and Mann-Whitney U Test with a Bonferroni Correction as mentioned before and the data are shown in Fig. 4.

3. Discussion

Gel formulations were evaluated depending on their pH and rheological changes during the storage period of 6 months. Placebo formulations (F1, F2, F3 and F4) gained pH values from 5.32 ± 0.05 to 5.53 ± 0.05 at the day of formulation (Table 1). Current literature indicates that the skin surface pH is mostly acidic between 5.4 and 5.9, therefore no pH adjustment was required for the formulations prepared (Ansari 2009). Small changes in pH values were detected during the storage period of 6 months for F1 formulation compared to other formulations prepared therefore F1 was selected as a key formulation for further studies. EYO and EGF was incorporated into F1 formulations with the concentrations of $100 \mu\text{g}\cdot\text{mL}^{-1}$ (E1) and $10 \mu\text{g}\cdot\text{mL}^{-1}$ (combination with $100 \mu\text{g}\cdot\text{mL}^{-1}$ EGF; M1) (Alemdaroglu et al. 2006) respectively. pH data of the E1 and M1 formulations were also monitored and during the storage period no significant changes were detected for both formulations without being affected from storage conditions (Table 1).

Rheological analyses also showed the stability of the E1 and M1 formulations with no significant changes in the rheological values by remaining unaffected from storage conditions during the storage period of 3 months (Table 2).

Burn patients need special and immediate care due to the severity, pain and discomfort of the situation therefore many attempts were developed as prehospital care like the use of herbal mixtures, oils, honey, EYO for the treatment of dermal burns Kopp et al. 2003; Albertyn et al. 2006; Rastegar et al. 2011; Sadeghi Bazargani et al. 2013) and among these approaches efficacy of

EYO was scientifically proven on third degree of burns of wistar rats (Sadeghi Bazargani et al. 2013).

EYO is a mixture of cholesterol, lipoproteins and proteins (eg. 68% low-density lipoproteins, 16% high-density lipoproteins, 10% livetins, 4% phosvitins) and fatty acids that makes EYO important for medical, pharmaceutical and cosmetic industries Rastegar et al. 2011; Alemдарođlu et al. 2006, Priya et al. 2002). Healing ability of EYO was attributed to the reduction of catabolism as well as increased matrix synthesis and promotion of re-epithelialisation due to the valuable materials most probably fatty acids inside Rastegar et al. 2011; Mahmoudi et al. 2013; Sadeghi Bazargani et al. 2013). Also unsaturated free fatty acids, especially linoleic and oleic acid, have shown a positive role in wound healing, due to their ability to modulate the inflammation and to enhance reparative response *in vivo* by releasing various cytokines (Mahmoudi et al. 2013; Pereira et al. 2008; Bonferoni et al. 2014).

Pereira et al. (2008), studied the effect of fatty acids oleic and linoleic acids on the process of wound healing in rats and study was concluded as oleic and linoleic acids have increased the number of neutrophils that migrated to the wound healing area resulting in enhanced healing process (Anton et al. 2003).

It was also reported as the topical application of fatty acids also improves hydration, elasticity and prevents skin breakdown which is prerequisite for rehabilitation of burned victims (Pereira et al. 2008; Hoeksema et al. 2013).

In our study the healing ability of EYO was evaluated by both wound contraction data and histological sample evaluation on the degree of burn on female Wistar rats.

Wound healing is a complex process including inflammation, re-epithelialisation, formation of granulation tissue, and fibrinogenesis, neovascularization followed by wound contraction and resurfacing steps (Priya et al. 2002; Upadhyay et al. 2009). Inflammation induces proliferation in wound healing, but due to the risk of tissue damage duration must be controlled (Upadhyay et al. 2009).

Digital images showed that, reduction of the inflammation was very obvious starting from 7th day with EYO and E1 formulations, but inflammation was still present for the untreated control group even at 14th day of treatment. Healing process was facilitated without edema formation for all the treated groups compared to the untreated control group (Fig. 2).

Histological analyses demonstrated that, formation of granulation tissue and collagen fibres were very obvious as well as uncompleted epithelialisation for EYO group at the 14th day and epithelialisation and collagen fibres formation was nearly completed with neovascularization at the 21st day of treatment (Fig. 3). Wound contraction data also support the data of histological evaluation of EYO showing that perception of burn wound healing efficacy of traditional approach is supported by the scientific data.

Comparison of E1 and M1 formulations showed completed granulation tissue with re-epithelialisation starting from day 14 and formation of epidermis and completed granulation tissue were detected at the 21st day of treatment. It was reported in many studies that chitosan itself has wound healing effects while was confirmed in our study (after 21 days). Incorporating EYO and EGF into chitosan gel formulations showed a synergistic effect with rapid healing process for the formulations of E1 and M1 (Fig. 3) (Ueno et al. 2001; Kweon et al. 2003).

Many attempts were developed for the formulation of silver derivatives in burn treatment considering antibacterial efficacy, and among that derivatives silver sulfadiazine was reported as the gold standard in topical burn treatment (Ueno et al. 2001). Therefore a commercial product of silver sulfadiazine (Silverdin[®], DEVA Turkey) was used as a reference in our study.

It was reported that silver sulfadiazine delays the wound-healing process Atiyeh et al. 2007 and also in our study epithelialisation could not be completed even at the 21st day of treatment the (Fig. 3).

Histological scoring also supported the data by showing significant differences ($p < 0.001$) in skin regeneration for EYO, E1 and M1 formulations at the 21st day of treatment (Fig. 4). It can be concluded that EYO, E1 and M1 formulations had a major impact on tissue regeneration in burn wound healing process.

4. Experimental

4.1. Materials

Glacial acetic acid and human epidermal growth factor (EGF) was purchased from Sigma- Aldrich[®], (St. Louis, USA). Chitosan (Highly viscous; 2-amino-2-deoxy-(1→4)- β -D-glucopyranan) was kindly provided by Fluka (Steinheim, Germany). Silverdin[®] (1% silver sulfadiazine, Deva, Turkey) was provided from a local pharmacy in Eskişehir. All other chemicals and solvents were of analytical grade.

4.2. Preparation of the chitosan gel formulations

During the preformulation studies, gel formulations were prepared with 4 different chitosan concentrations (0.5% [F1]; 1.0% [F2]; 1.5% [F3] and 2% [F4]; w/v). Briefly, chitosan was dissolved in acetic acid solution (0.5%, v/v) under a magnetic stirrer at 250 rpm for 4 h. Formulations were kept at room temperature for an overnight in well closed vials for the removal of air bubbles. Formulations prepared were kept at 4 different conditions ($25 \pm 1^\circ\text{C}$, $4 \pm 1^\circ\text{C}$, $40 \pm 1^\circ\text{C}$ and $40 \pm 1^\circ\text{C} + 60\%$ Relative Humidity (RH)) for better evaluation of the stability of the chitosan gel during the storage period of 6 months.

EYO was obtained by a traditional method. Fresh egg yolks were heated up to $200 \pm 5^\circ\text{C}$ in a frying pan over the fire after 5 min until the oil, began to exude out of residue. The charred residue of the yolks was removed and discarded and only the pure egg oil remained in the cooking vessel. At last residue was filtered and removed from the oil and the oil was stored in well closed containers until being used (Gray 1821). EYO and EGF solution were added to the selected formulation up to the final concentration of $100 \mu\text{g}\cdot\text{mL}^{-1}$ and $10 \mu\text{g}\cdot\text{mL}^{-1}$ (Alemдарođlu et al. 2006) respectively.

4.3. pH Analyses

pH Values of the formulations prepared were recorded by a WTW Profi Lab (pH 597, Weilheim, Germany) at $25 \pm 1^\circ\text{C}$ for the formulations kept at different temperatures during the storage period of 6 months. All analyses were repeated in triplicate.

4.4. Rheological analyses

For better evaluation of the stability and spreadability capacity of the gel formulations prepared rheological behaviours of the formulations were determined by a cone plate rheometer (Brookfield RVDV-III+CP, Middleboro, USA). Briefly, about 0.5 g of the tested formula was applied to the plate and the measurements were carried out at 250 rpm at $25 \pm 1^\circ\text{C}$. Results were recorded only when the torque was within the acceptable range (10-100%).

4.5. Burn wound model

Female Wistar rats (200-250 g) were used for *in vivo* studies. Animals were obtained from the Anadolu University Experimental Animals Research Centre. *In vivo* study protocol was established with the guidance of Guide for the Care and Use of Laboratory Animals (NIH publication No: 85-23, revised in 1985) and the study protocol was approved by the Local Ethical Committee of Anadolu University, Eskişehir, TURKEY (Protocol No: 2011-12/12-11). All animals were housed in separate cages with standard pellet diet and water *ad libitum*. Rats were randomly divided into six experimental groups (n=22 each group). The rats were anesthetized by i.p. injection of xylazine hydrochloride ($10 \text{ mg}\cdot\text{kg}^{-1}$ Rompun[®], Bayer AG, Leverkusen, Germany) and ketamine hydrochloride ($25 \text{ mg}\cdot\text{kg}^{-1}$ Ketalar[®], Parker Davis, Eczacıbası, Istanbul, Turkey). Dorsal side was shaved with electric clipper followed by razor for the prevention of the differentiation in the degree of burn due to the presence of hair. Degree of burn was created by using metal stamp (150 mm diameter, 30 g weight) which was heated up to $80 \pm 1^\circ\text{C}$. Hot stamp was applied at the shaved area for 20 s without making any pressure. The formulations tested were applied topically two times a day during 21 day of treatment. Contraction of the diameters of the wounded sites were detected by a digital caliper at the 1st, 7th, 14th and 21st days. Burn wound

healing was assessed by the evaluation of changes in wound diameter as well as the histological examinations of the tissue samples of the burned sites (Priya et al. 2002).

4.6. Histological examination

For the histological examinations five animals were euthanized in each group at the 7th, 14th and 21st days of treatment and the whole skin of wounded sites was cut off and stored in formalin (10%, v/v) until being examined.

Routine histologic methods were processed for the evaluation of the tissue samples (Cuttle et al. 2006). 5 µm cut paraffin sections were stained with haematoxylin and eosin, then samples were examined with an Olympus BX-50 microscope (Hamburg, Germany). Digital images were captured from each selected slide with Olympus Digital DP-70 camera (Hamburg, Germany).

The specimens were histologically assessed considering progression of inflammation, granulation tissue formation, collagen organisation and new epithelium formation in the wound defect. Scores were given by histologists according to a system reported previously to evaluate maturity of wound repair (Hebda et al. 2003).

4.7. Statistical analysis

Statistical analyses of histological data were carried out using SPSS statistical software, version 16.0. for Windows (SPSS Inc., Chicago, IL, USA). All data were tested for normal distribution (Shapiro-Wilks) (Zaiontz 2014) for defining whether the results should be analyzed parametrically or non-parametrically. $p < 0.05$ was regarded as statistically significant for all statistical analysis. Comparison of histological scoring between different groups was carried out by Kruskal-Wallis Variance Analysis and Mann-Whitney U test with a Bonferroni correction.

Wound contraction data were evaluated by the statistical analyses of two-way ANOVA, followed by Tukey's multiple comparison tests using GraphPad Prism Version 5.0. Results were expressed in Mean ± SEM. Differences were considered significant when $p \leq 0.05$.

Acknowledgements: We show our appreciation to the Department of Histology-Embryology, Osmangazi University School of Medicine. We also thank Dr. Erhan Şahin for evaluation statistical analysis and Huri Çınar for technical assistance. This study was financed by Anadolu University Scientific Research Project Foundation (Project No:090343). The authors report no conflicts of interest. The authors alone are responsible for the content and writing of this article.

References

Albertyn R, Bickler SW, Rode H (2006) Paediatric burn injuries in sub saharan africa - an overview. *Burns* 32: 605–612.

Alemдарođlu C, Deđim Z, Çelebi N, Zor F, Öztürk S, Erdođan D (2006) An investigation on burn wound healing in rats with chitosan gel formulation containing epidermal growth factor. *Burns* 32: 319–327.

Ansari SA (2009) Skin pH and skin flora. In: Barel AO, Paye M, Maibach HI (eds.) *Handbook of cosmetic science and technology*, 3rd ed., New York: Informa Healthcare USA, p. 221–232.

Anton M, Martinet V, Dalgalarroondo M, Beaumal V, David-Briand E, Rabesona H (2003) Chemical and structural characterisation of low-density lipoproteins purified from hen egg yolk. *Food Chem* 83: 175–183.

Aoyagi S, Onishi H, Machida Y (2007) Novel chitosan wound dressing loaded with minocycline for the treatment of severe burn wounds. *Int J Pharm* 330: 138–145.

Arda-Pirincci P, Bolkent S (2014) The role of epidermal growth factor in prevention of oxidative injury and apoptosis induced by intestinal ischemia/reperfusion in rats. *Acta Histochem* 116: 167–175.

Atiyeh BS, Costagliola M, Hayek SN, Dibo SA (2007) Effect of silver on burn wound infection control and healing: review of the literature. *Burns* 33: 139–148.

Başaran E, Yazan Y (2012) Ocular application of chitosan. *Expert Opin Drug Deliv* 9: 701–712.

Bonferoni MC, Sandri G, Dellera E, Rossi S, Ferrari F, Mori M, Caramella C (2014) Ionic polymeric micelles based on chitosan and fatty acids and intended for wound healing. Comparison of linoleic and oleic acid. *Eur J Pharm Biopharm* 87: 101–106.

Cirodde A, Leclerc T, Jault P, Duhamel P, Lataillade JJ, Bargues L (2011) Cultured epithelial autografts in massive burns: a single-center retrospective study with 63 patients. *Burns* 37: 964–972.

Cleland H, Wasiak J, Dobson H, Paul M, Pratt G, Paul E, Herson M, Akbarzadeh S (2014) Clinical application and viability of cryopreserved

cadaveric skin allografts in severe burn: a retrospective analysis. *Burns* 40: 61–66.

Cuttle L, Kempf M, Phillips GE, Mill J, Hayes MT, Fraser JF, Wang XQ, Kimble RM (2006) A porcine deep dermal partial thickness burn model with hypertrophic scarring. *Burns* 32: 806–820.

Dantas MD, Cavalcante DR, Araújo FE, Barretto SR, Aciole GT, Pinheiro AL, Ribeiro MA, Lima-Verde IB, Melo CM, Cardoso JC, Albuquerque Júnior RL (2011) Improvement of dermal burn healing by combining sodium alginate/chitosan-based films and low level laser therapy. *J Photochem Photobiol B* 105: 51–59.

Frew Q, Philp B, Shelley O, Myers S, Navsaria H, Dziejewski P (2013) The use of Biobrane® as a delivery method for cultured epithelial autograft in burn patients. *Burns* 39: 876–80.

Fouda MMG, Wittke R, Knittel D, Schollmeyer E (2009) Use of chitosan/polyamine biopolymers based cotton as a model system to prepare antimicrobial wound dressing. *Int J Diabetes Mellit* 1: 61–64.

Gray FS (1821) *Simple substances - animal oils. A supplement to the pharmacopoeia: being a treatise on pharmacology in general*, Thomas and George Underwood, London, p. 227.

Groeber F, Holeiter M, Hampel M, Hinderer S, Schenke-Layland K (2011) Skin tissue engineering - *in vivo* and *in vitro* applications. *Adv Drug Deliv Rev* 63: 352–366.

Hamidi M, Azadi A, Rafiei P (2008) Hydrogel nanoparticles in drug delivery. *Adv Drug Deliv Rev* 60: 1638–1649.

Haslik W, Kamolz LP, Nathschlager G, Anel H, Meissl G, Frey M (2007) First experiences with the collagen-elastin matrix matriderm as a dermal substitute in severe burn injuries of the hand. *Burns* 33: 364–368.

Hebda PA, Whaley D, Kim HG, Wells A (2003) Absence of inhibition of cutaneous wound healing in mice by oral doxycycline. *Wound Repair Regen* 11: 373–379.

Hermans MH (2014) Porcine xenografts vs. (cryopreserved) allografts in the management of partial thickness burns: is there a clinical difference? *Burns* 40: 408–415.

Hoeksema H, De Vos M, Verbelen J, Pirayesh A, Monstrey S (2013) Scar management by means of occlusion and hydration: a comparative study of silicones versus a hydrating gel-cream. *Burns* 39: 1437–1448.

Hoemann CD, Sun J, Legare A, McKee MD, Buschmann MD (2005) Tissue engineering of cartilage using an injectable and adhesive chitosan-based cell-delivery vehicle. *Osteoarthritis Cartilage* 13: 318–329.

Jahovic N, Güzel E, Arbak S, Yeğen BC (2004) The healing-promoting effect of saliva on skin burn is mediated by epidermal growth factor (EGF): role of the neutrophils. *Burns* 30: 531–538.

Jayakumar R, Prabakaran M, Sudheesh Kumar PT, Nair SV, Tamura H (2011) Biomaterials based on chitin and chitosan in wound dressing applications. *Biotechnol Adv* 29: 322–337.

Ji DY, Kuo TF, Wu HD, Yang JC, Lee SY (2012) A novel injectable chitosan/polyglutamate polyelectrolyte complex hydrogel with hydroxyapatite for soft-tissue augmentation. *Carbohydr Polym* 89: 1123–1130.

Jin G, Prabhakaran MP, Kai D, Ramakrishna S (2013) Controlled release of multiple epidermal induction factors through core-shell nanofibers for skin regeneration. *Eur J Pharm Biopharm* 85: 689–698.

Kopp J, Wang GY, Horch RE, Pallua N, Ge SD (2003) Ancient traditional chinese medicine in burn treatment: a historical review. *Burns* 29: 473–478.

Kweon DK, Song SB, Park YY (2003) Preparation of water-soluble chitosan/heparin complex and its application as wound healing accelerator. *Biomaterials* 24: 1595–1601.

Lin WC, Lien CC, Yeh HJ, Yu CM, Hsu SH (2013) Bacterial cellulose and bacterial cellulose-chitosan membranes for wound dressing applications. *Carbohydr Polym* 94: 603–611.

Mahmoudi M, Ebrahimzadeh MA, Pourmorad F, Rezaie N, Mahmoudi MA (2013) Anti-inflammatory and analgesic effects of egg yolk: a comparison between organic and machine made. *Eur Rev Med Pharmacol Sci* 17: 472–476.

Mi FL, Wu YB, Shyu SS, Chao AC, Lai JY, Su CC (2003) Asymmetric chitosan membranes prepared by dry/wet phase separation: a new type of wound dressing for controlled antibacterial release. *J Membr Sci* 212: 237–254.

Moura LI, Dias AM, Leal EC, Carvalho L, de Sousa HC, Carvalho E (2014) Chitosan-based dressings loaded with neurotensin - an efficient strategy to improve early diabetic wound healing. *Acta Biomater* 10: 843–857.

Orgill DP, Gobble R (2014) Skin regeneration and bioengineering. In: Orlando G, Lerut JP, Soker S, Stratta RJ (eds.) *Regenerative medicine application in organ transplantation*, 1st ed., Academic Press Elsevier Inc USA, p. 761–770.

- Pereira LM, Hatanaka E, Martins EF, Oliveira F, Liberti EA, Farsky SH, Curi R, Pithon-Curi TC (2008) Effect of oleic and linoleic acids on the inflammatory phase of wound healing in rats. *Cell Biochem Funct* 26: 197–204.
- Priya KS, Gnanamani A, Radhakrishnan N, Babu M (2002) Healing potential of *datura alba* on burn wounds in albino rats. *J Ethnopharmacol* 83: 193–199.
- Rastegar F, Azarpira N, Amiri M, Azarpira A (2011) The effect of egg yolk oil in the healing of third degree burn wound in rats. *Iran Red Crescent Med J* 13: 739–743.
- Sadeghi Bazargani H, Fouladi N, Alimohammadi H, Sadeghieh Ahari S, Agamohammadi M, Mohamadi R (2013) Prehospital treatment of burns: a qualitative study of experiences, perceptions and reactions of victims. *Burns* 39: 860–865.
- Selig HF, Lumenta DB, Giretzlehner M, Jeschke MG, Upton D, Kamolz LP (2012) The properties of an “ideal” burn wound dressing - what do we need in daily clinical practice? Results of a worldwide online survey among burn care specialists. *Burns* 38: 960–966.
- Tsao CT, Chang CH, Lin YY, Wu MF, Wang JL, Young TH, Han JL, Hsieh KH (2011) Evaluation of chitosan/ γ -poly(glutamic acid) polyelectrolyte complex for wound dressing materials. *Carbohydr Polym* 84: 812–819.
- Ueno H, Mori T, Fujinaga T (2001) Topical formulations and wound healing applications of chitosan. *Adv Drug Deliv Rev* 52: 105–115.
- Upadhyay NK, Kumar R, Mandotra SK, Meena RN, Siddiqui MS, Sawhney RC, Gupta A (2009) Safety and healing efficacy of sea buckthorn (*Hippophae rhamnoides L.*) seed oil on burn wounds in rats. *Food Chem Toxicol* 47: 1146–1153.
- Verbelen J, Hoeksema H, Heyneman A, Pirayesh A, Monstrey S (2014) Aquacel® Ag dressing versus Acticoat™ dressing in partial thickness burns: a prospective, randomized, controlled study in 100 patients. Part 1: burn wound healing. *Burns* 40: 416–427.
- Vujanovic S, Vujanovic J (2013) Bioresources in the pharmacotherapy and healing of burns: a mini review. *Burns* 39: 1031–1038.
- Wang T, Zhu XK, Xue XT, Wu DY (2012) Hydrogel sheets of chitosan, honey and gelatin as burn wound dressings. *Carbohydr Polym* 88: 75–83.
- Wang X, Hu X, You C, Han C (2014) Delivery of epithelial autografts and cutaneous wound healing in burn patients. *Burns* 40:166–168.
- Yildirim L, Thanh NT, Seifalian AM (2012) Skin regeneration scaffolds: a multimodal bottom-up approach. *Trends Biotechnol* 30: 638–648.
- Zaiontz C., (2015) Real statistics using excel: shapiro-wilk original test. Last accessed:08.04.2014 www.real-statistics.com/tests-normality-and-symmetry/statistical-tests-normality-symmetry/shapiro-wilk-test.