

## Original Research

# Aldosterone is a possible new stimulating factor for promoting vascular calcification

Xusheng Zhang<sup>1,2,3</sup>, Xiaou Zhou<sup>4</sup>, Zhanjun Huang<sup>3</sup>, Xiaorong Fan<sup>3</sup>, Xiaoqing Tan<sup>3</sup>, Chengzhi Lu<sup>1,2,\*</sup>, Jianshe Yang<sup>3,5,\*</sup>

<sup>1</sup>Department of Cardiology, The First Central Clinical College of Tianjin Medical University, 300070 Tianjin, China,

<sup>2</sup>Department of Cardiology, Tianjin First Central Hospital, 300070 Tianjin, China, <sup>3</sup>Department of Cardiology, Longgang People's Hospital of Shenzhen, 518172 Shenzhen, Guangdong, China, <sup>4</sup>Department of Cardiology, Dongguan Kanghua Hospital, 523080 Dongguan, Guangdong, China, <sup>5</sup>Department of Nuclear Medicine, Shanghai Tenth People's Hospital, Tongji University, 200072 Shanghai, China

## TABLE OF CONTENTS

1. Abstract
2. Introduction
3. Methods
  - 3.1 Animal model preparation
  - 3.2 Experiments
  - 3.3 Data analysis
4. Results
  - 4.1 Noninvasive blood pressure, weight loss, and cardiac weight index of rats
  - 4.2 Von Kossa staining in the aorta
  - 4.3 The calcium content and the activity of ALP in the aorta tissue
  - 4.4 Masson's trichrome staining
  - 4.5 The content of the C-reactive protein, IL-6, TNF- $\alpha$  and MCP-1 in serum
  - 4.6 The content of Urotensin II and aldosterone in the aorta tissue
  - 4.7 The change of the immunoreactivity
5. Discussion
6. Conclusions
7. Author contributions
8. Ethics approval and consent to participate
9. Acknowledgment
10. Funding
11. Conflict of interest
12. Availability of data and materials
13. References

## 1. Abstract

**Background:** Aldosterone is an important hormone in the renin-angiotensin-aldosterone system (RAAS), and playing a pivotal role in the development of hypertension, heart failure, and other cardiovascular diseases. **Material and method:** In this study, the role of the aldosterone in vascular calcification was underwent in rat model compared with other drugs. Vascular calcification, calcium concentration, activity of alkaline phosphatase (ALP), aldosterone, Urotensin II, mineralocorticoid receptor (MR) and Osteopontin (OPN) were detected or confirmed by the von

Kossa staining, colorimetric assays, immunohistochemistry and radioimmunoassay, separately. **Result:** Results revealed that the aldosterone was significantly increased compared calcification + aldosterone group with calcification group, whereas it was notably decreased in calcification + Spironolactone group in the aortic wall. Compared with control group and aldosterone group, calcium content in vascular tissues was increased in calcification group and calcification + aldosterone group. As the immunoreactivity of the MR, OPN, Urotensin II, IL-6, monocyte chemoattractant protein-1, and deposition of collagen in calcifica-

tion group and aldosterone group, they all were increased slightly, but were significantly increased in calcification + aldosterone group. **Conclusion:** It is implied that aldosterone may be involved in the development of vascular calcification, however, the mechanism needs to be further studied.

## 2. Introduction

Vascular calcification is a complication in hypertension, diabetes mellitus, chronic renal insufficiency, and considered as a risk factor for cardiovascular event [1–3]. Two major types of vascular calcification are distinguished by their location and association with atherosclerotic plaque formation. First, atherosclerotic calcification, is located in the intimal layer and is associated with atherosclerosis. Atherosclerotic calcification involves cellular necrosis, inflammation, and lipid deposition. As lesions progress, osteogenesis, including osteoblast induction and lamellar bone formation, becomes increasingly evident. Second type is Monckeberg sclerosis, in which amorphous mineral forms circumferentially along or within one or more elastic lamellae of the medial layer. This second type also known as medial artery calcification, it is more prevalent in patients with diabetes and chronic kidney disease (CKD). Calciphylaxis is defined as a chronic progressive syndrome of arteriolar media calcification, thrombotic ischemia, and necrotic ulceration. The cumulative incidence of calciphylaxis among hemodialysis patients in the Europe and America has been reported to be within 1%, and the corresponding prevalence was estimated to be 4.1–4.4% [2]. The aforementioned pathological mechanisms often overlap with each other. Atherosclerotic calcification often accompanies with medial artery calcification in clinical trials. Vascular calcification is an active consequence of aging, which may increase vascular stiff, lessen vascular compliance, and cause myocardial ischemia and plaque rupture [1–3].

Amount of evidence pointed out a tightly regulated process was associated with the competition of various factors, having the capability to promote calcification and inhibitors of mineralization. However, the precise molecular mechanisms on facilitating ectopic mineral deposition remain unclear [1–5]. It has been reported that cardiovascular calcification recapitulates the processes of orthotopic, skeletal, bone formation, accompanying by calcium deposition, upregulation of the activity of alkaline phosphatase (ALP), and change of cell phenotype [2]. aldosterone partly regulates  $\text{Na}^+$  and  $\text{K}^+$  homeostasis by modulating  $\text{Na}^+$  resorption in kidney. However, the renin–angiotensin–aldosterone system (RAAS) has additional physiological effects in increasing vascular wall stiff, causing cardiomyocyte hypertrophy, and modulating cell proliferation [6–8]. Additionally, aldosterone plays a key role in the pathophysiology of hypertension, chronic heart failure [9], myocar-

dial infarction remodeling [6–8]. The mineralocorticoid receptor (MR) activated by aldosterone can increase the synthesis of collagen [10], induce inflammation [11, 12], modulate oxidative stress [13–15], promote cell migration [16], and induce apoptosis [17, 18]. Aldosterone can also increase calcification in vascular smooth muscle cells [19, 20]. We therefore hypothesized that aldosterone could increase vascular calcification, and spriolactone can alleviate vascular calcification. Osteopontin (OPN) is a multifunctional aspartic acid, N-linked glycosylated protein that highly expressed in chronic inflammatory and autoimmune diseases [21]. OPN appears to modulate inflammatory, proliferation [22], migration [23, 24], and accumulation of smooth muscle and endothelial cells, all these were involved in the repair and remodeling processes of the vasculature [25]. However, OPN, as a potent inhibitor of hydroxyapatite, regulates pathologic calcification by binding to crystal surfaces, thereby blocking further addition of mineral ions to growth of crystal sites, and recruits additional macrophages to ectopic calcification sites to facilitate clearance of ectopic calcification [26–28]. We also hypothesized that exogenous and endogenous factors could increase vascular calcification by promoting the expression of collagen, Urotensin II, and its receptor in the aorta wall, thereby up-regulating the expression of the inflammatory factors. Besides, we tried to reveal the relationship among OPN, vascular calcification, and vascular fibrosis in this study.

## 3. Methods

### 3.1 Animal model preparation

Alone or with combination, vitamin D3, warfarin, nicotine, and calcium chloride can induce artery calcification in rats and mice, which is an often used method for preparing animal models of vascular calcification. The operation is relatively simple, fast, with high survival rate and low cost [29]. The model preparation was briefly presented below.

Sprague-Dawley rats was induced to arterial calcification by Vitamin D3 plus nicotine (VDN). Also, 40 samples of 7-week-old male SD rat (because the male rats were rarely disturbed by the estrogenic hormone, then possibly impacted the aldosterone) were randomly divided into 5 groups and with 8 samples in each group: control group, aldosterone group [aldosterone (20  $\mu\text{g}/\text{d}$ ) with hypodermic injection for 6 weeks, once in one day], calcification group [Vitamin D3 (300,000 U/kg) with IM and Nicotine (25 mg/kg) intragastric administration twice in the first day, and then fed for 6 weeks], calcification + aldosterone group [Vitamin D3 (300,000 U/kg) with IM and Nicotine (25 mg/kg) intragastric administration twice in the first day, and then aldosterone (20  $\mu\text{g}/\text{d}$ ) with hypodermic injection for 6 weeks, once in one day], calcification + spriolactone group [Vitamin D3 (300,000 U/kg) with IM and Nicotine

(25 mg/kg) intragastric administration twice in the first day, and then spriolactone (40 mg/kg) with intragastric administration for 6 weeks, once in one day]. The experimental animal (rat) has obtained consent from the Institutional Review Board of Tianjin Medical University (TMU-2020-LLSC-0106).

### 3.2 Experiments

**Blood pressure measurement:** Tail pressure method (Tail-cuff method) was used to acquire the blood pressure value noninvasively. Blood pressure values were obtained by placing the sensor in the tail of the mouse and monitoring the blood pressure signal through inflation and ventilation for the tail artery pressure and pressure release.

After model rats were anesthetized with 2% pentobarbital sodium (40 mg/kg), plasma, serum, and aorta (the whole length of thoracic and abdominal aorta) were collected for detection, detailed information are described as below.

After fixation, the abdominal cavity and thoracic cavity of rats were cut open with scissors, and their heart was exposed. Venous blood of rats was extracted with a 10 mL syringe, about 4 mL was put into a 5 mL plastic tube containing heparin, ethylenediaminetetraacetic acid (EDTA), and aprotin, which was thoroughly mixed, and centrifuged at 4 °C for 10 min at 3000 rpm. The plasma was separated and put into an Eppendorf (EP) tube (No. 0030121023, Hamburg, Germany), sealed with a sealing membrane, and stored at -80 °C. Venous blood was extracted with a 10 mL syringe and placed into a 5 mL plastic tube containing coagulant, which was thoroughly mixed and centrifuged at 4 °C for 10 min at 500 rpm. The serum was separated and placed into an EP tube, sealed with a sealing membrane, and stored at -80 °C. The process of extracting venous blood was repeated for multiple times.

Carefully peeled the aorta to the full length of the abdominal aorta, placed it in ice saline, and washed it, meanwhile, carefully peeled the surrounding connective tissue with small tweezers, used the initial section of the thoracic aorta (histological examination), placed it in 4% paraformaldehyde solution, stored it for about 12–24 h, then rinsed it with running water for about 12 h, and thereafter dehydrated and embed it. Took about 100 mg aorta tissue, divided each 50 mg inserted in 1.5 mL EP (via measuring aldosterone and vasopressin receptor 2 (V2R)), marked with oily pen mark, and refrigerated at -80 °C. Abdominal aortic tissue (about 50 mg) was taken and placed in an EP tube (1.5 mL) for determining activity of ALP and calcium content of vascular tissue, which marked with oily pen, and refrigerated at -80 °C.

**Measurement of the extent of calcification:** The von Kossa staining for calcification showed that a positive staining, as black areas in the main, large, and nodular structures, was found in the vascular media.

**Measurement of calcium content:** The calcium content in vascular tissues was measured using a simple and rapid colorimetric method based on methylthymol blue, performed by Nanjing Jiancheng Bioengineering Institute (Nanjing, China).

**Measurement of the activity of ALP:** The activity of ALP was evaluated by using Alkaline Phosphatase Assay Kit (Nanjing Jiancheng Bioengineering Institute, Nanjing, China). Briefly, the nitrophenol phosphate (pNPP) is a commonly used alkaline phosphatase color rendering substrate that can be catalyzed by ALP to generate nitrophenol (para-nitrophenol, p-nitrophenol) as a yellow product and absorbance can be detected at 400–415 nm. The darker the product yellow represents higher ALP activity, and vice versa, lower enzyme activity. Then, ALP levels can be quantified quantitatively by colorimetric analysis.

**Immunohistochemistry:** The mineralocorticoid receptor immunoreactivity, the immunoreactivity of OPN, the receptor immunoreactivity of the Urotensin II, interleukin-6 (IL-6), and monocyte chemoattractant protein-1 (MCP-1) in cardiovascular tissues were detected by using immunohistochemical assay.

**Masson's Trichrome staining:** The deposition of collagen in cardiovascular tissues was measured by Masson's trichrome staining. Briefly, by use of the three stains, Masson's Trichrome staining technique is used for the detection of collagen fibers in tissues such as the skin, heart, muscles. The samples are formalin-fixed, paraffin-embedded sections, or frozen sections. Weigert's hematoxylin, an iron hematoxylin dye is used to stain the nuclei. This dye is resistant to decolorization by acidic staining solutions. Biebrich-Scarlet Acid Fuchsin solution (No. S125, Bay Shore, NY, USA) stains all the acidic tissues such as the cytoplasm, muscle, and collagen. Phosphomolybdic or phosphotungstic acid is used as a decolorizing agent, making the Biebrich Scarlet-acid fuchsin to diffuse out of the collagen fibers, this leaves the muscle cells staining red. Aniline blue stains the collagen along which 1% acetic acid is added to show a difference in the tissue sections. The collagen fibers stain blue and the nuclei stains black, with a red background. The detailed procedures are: Deparaffinize and rehydrate using 100% alcohol, 95% alcohol, and 70% alcohol sequentially; Wash in distilled water; For tissues fixed with Formalin, re-fix in Bouin Solution for 1 hour at 56 °C, this improves the quality of the stain; Rinse with running tap water for 5–10 minutes to remove yellow color; Stain with Weigert's iron hematoxylin solution (No. 115973, Sigma-Aldrich, Darmstadt, Germany) for 10 minutes; Rinse the stain with running tap water for 10 minutes; Wash in distilled water; Stain with the Biebrich-Scarlet Acid Fuchsin solution for 10–15 minutes; Wash in distilled water; Differentiate in the phosphomolybdic-phosphotungstic acid solution (No. SSC-PPA125, TX, USA) for 10–15 minutes or until the collagen loses its red color; Transfer the stained sec-

tion to aniline blue solution (No. B8653, Sigma-Aldrich, Darmstadt, Germany) and stain for 5–10 minutes; Rinse the stained section briefly in distilled water and differentiate with 1% acetic acid solution (No. 45754, Sigma-Aldrich, Darmstadt, Germany) for 2–5 minutes; Quickly dehydrate through 95% ethyl alcohol after wash in distilled water; Clear in xylene; Mount with a mounting medium.

**Radioimmunoassay:** The contents of Aldosterone in plasma and vascular tissue, C-reactive protein, IL-6, tumor necrosis factor- $\alpha$  (TNF- $\alpha$ ), MCP-1 in serum were determined by Bio-Plex 200 Systems with Bio-Plex Pro™ Mouse Cytokine Assay kits (No. M60009RDPD, Bio-Rad Laboratories, Inc., CA, USA), as well as the content of Urotensin II in plasma and vascular tissues were determined by radioimmunoassay via Beijing Sino-UK Institute of Biological Technology (Beijing, China). The main process consists of first incubating Urotensin II and biotin-labeled antibodies. After washing, the avidin-labeled HRP was added. After further incubation and washing, unbound enzyme conjugates were removed and then the substrate was added to act simultaneously with the enzyme conjugates. The depth of color is proportional to the concentration of Urotensin II in the samples.

**Enzyme immunoassay:** The content of Osteopontin (OPN) in plasma was measured by enzyme immunoassay, conducted by Beijing Sino-UK Institute of Biological Technology (Beijing, China).

In this study, 8 fields were randomly selected from each group of slices, and image-pro Plus 6.0 software (version 6.0, Media Cybernetics, Inc., MD 20852, USA) was applied to calculate the percentage of positive staining area in the total area of slices. Multiple independent samples were used for nonparametric testing of the percentage of positive staining area between groups.

### 3.3 Data analysis

$\chi^2$  tests were used for categorical variables and one-way ANOVA for continuous variables. Statistical significance was defined at a level of less than 0.05. Analyses were carried out using IBM SPSS software (version 21.0, IBM Corp., Chicago, IL, USA).

## 4. Results

### 4.1 Noninvasive blood pressure, weight loss, and cardiac weight index of rats

After 6 weeks of hypodermic injection of aldosterone, the noninvasive blood pressure and cardiac weight index of rats were increased, and we observed the weight loss, which proved aldosterone's effect. Besides, the non-invasive blood pressure, weight loss, and cardiac weight index for calcification group were shown in Fig. 1.

### 4.2 Von Kossa staining in the aorta

Von Kossa staining for calcification showed that a positive staining, noted black areas in the main, large, and nodular structures, was found in the vascular media. In comparison with calcification group, which was significantly increased in calcification + aldosterone group, whereas it was significantly decreased in calcification + spriolactone group, as illustrated in Fig. 2.

### 4.3 The calcium content and the activity of ALP in the aorta tissue

Compared with control group, the calcium content in vascular tissues was increased by 63.45% ( $p < 0.01$ ) in calcification group, and 121.72% ( $p < 0.01$ ) in calcification + aldosterone group; in comparison with aldosterone group, the calcium content in vascular tissues was increased by 27.55% ( $p < 0.05$ ) in calcification group, and 73.02% ( $p < 0.01$ ) in calcification + aldosterone group; compared with calcification group, the calcium content in vascular tissues was increased by 35.65% ( $p < 0.01$ ) in calcification + aldosterone group, whereas that was decreased by 41.31% ( $p < 0.01$ ) in calcification + spriolactone group; compared with calcification + aldosterone group, the calcium content in vascular tissues was decreased by 56.73% ( $p < 0.01$ ) in calcification + spriolactone group, as displayed in Fig. 3A.

As for ALP activity in vascular tissues, compared with control group, which was increased by 49.79% ( $p < 0.01$ ) in calcification group, and 85.76% ( $p < 0.01$ ) in calcification + aldosterone group; compared with aldosterone group, which was increased by 62.79% ( $p < 0.01$ ) in calcification group, and 101.88% ( $p < 0.01$ ) in calcification + aldosterone group; compared with calcification group, which was increased by 24.01% ( $p < 0.01$ ) in calcification + aldosterone group, while it was decreased by 26.26% ( $p < 0.01$ ) in calcification + spriolactone group; when compared with calcification + aldosterone group, which was decreased by 40.54% ( $p < 0.01$ ) in calcification + aldosterone group, as depicted in Fig. 3B.

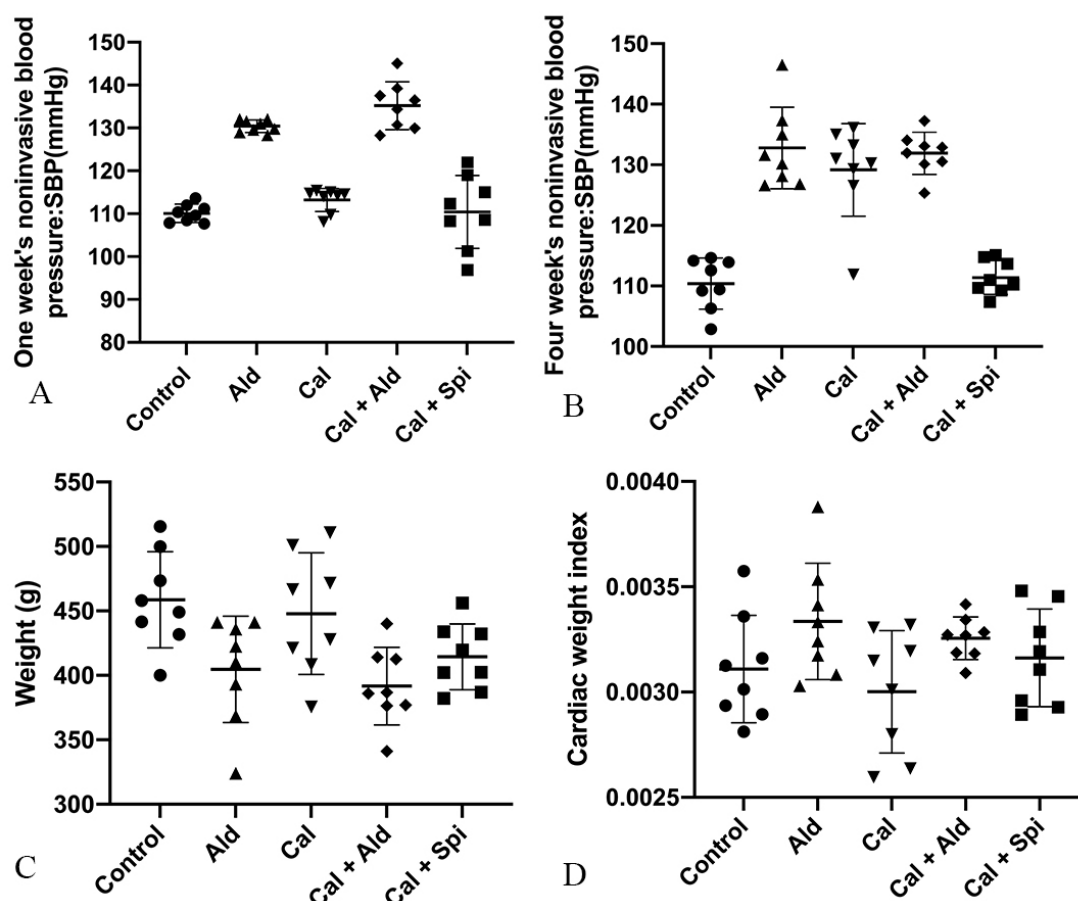
### 4.4 Masson's trichrome staining

Compared with control group, the deposition of collagen in calcification group and aldosterone group was increased, but which was significantly increased in calcification + aldosterone group, and was slightly increased in calcification + spriolactone group (Fig. 4).

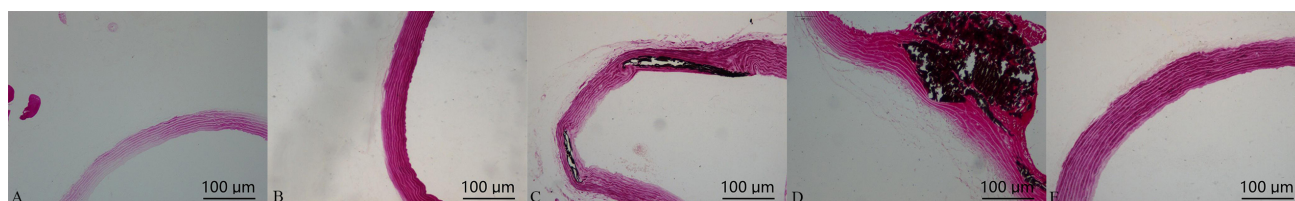
### 4.5 The content of the C-reactive protein, IL-6, TNF- $\alpha$ and MCP-1 in serum

Compared with control group, the content of the C-reactive protein was increased by 30.35% ( $p < 0.01$ ) in aldosterone group, 31.01% ( $p < 0.01$ ) in calcification group, and 53.67% ( $p < 0.01$ ) in calcification + aldosterone group; compared with aldosterone group, the content of the C-reactive protein was increased by 17.89% ( $p < 0.05$ ) in calcification + aldosterone group, while that was decreased by 15.19% ( $p < 0.05$ ) in calcification + spriolactone group;





**Fig. 1. Physiology index of experimental rats among the different groups.** (A) Noninvasive blood pressure of rats after 1 week. (B) Noninvasive blood pressure of rats after 4 weeks. (C) Weight of rats. (D) Rats's cardiac weight index.



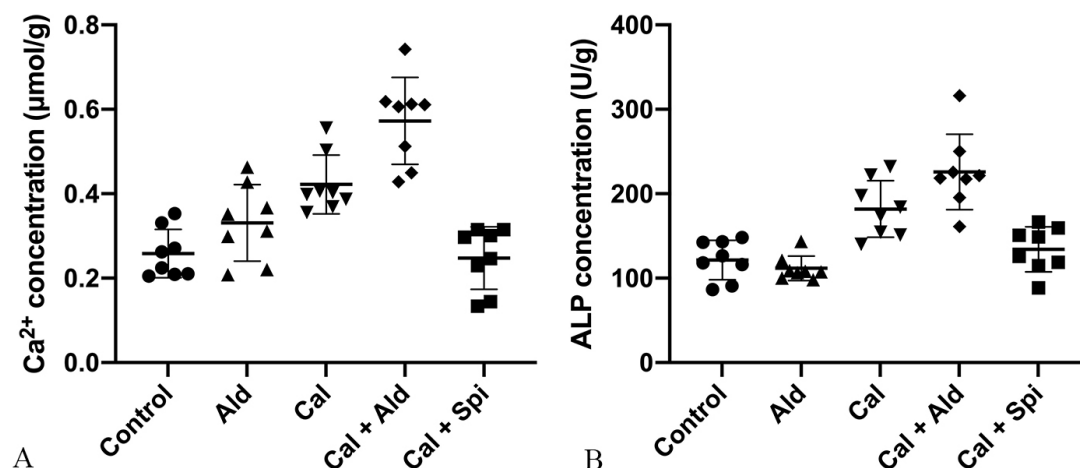
**Fig. 2. Von Kossa staining in the aorta: positive staining was shown with black areas (10 × 10).** (A) Control group. (B) Aldosterone group. (C) Calcification group. (D) Calcification + aldosterone group. (E) Calcification + spriolactone group. (A) 1.35%, (B) 1.61%, (C) 42.00%, (D) 79.50%, (E) 27.30%,  $\chi^2 = 36.34$ ,  $\nu = 4$ ,  $p = 0.0001$ .

compared with calcification group, the content of the C-reactive protein was increased by 17.30% ( $p < 0.01$ ) in calcification + aldosterone group, whereas that was decreased by 15.61% ( $p < 0.05$ ) in calcification + spriolactone group; compared with calcification + spriolactone group, the content of the C-reactive protein was increased by 39.00% ( $p < 0.01$ ) in calcification + aldosterone group (Fig. 5A).

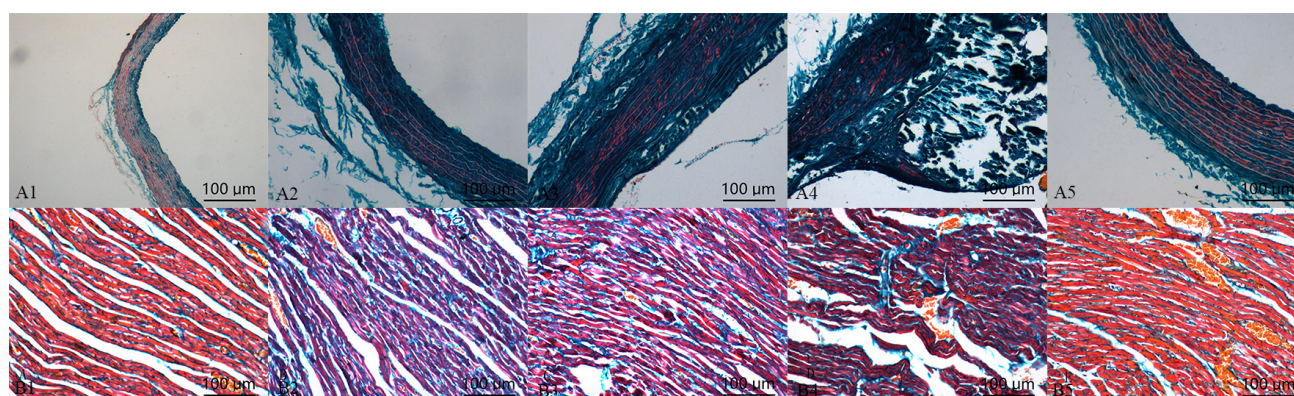
Compared with control group, the content of the IL-6 was increased by 20.55% ( $p < 0.01$ ) in aldosterone group, 20.22% ( $p < 0.01$ ) in calcification group, and 27.38% ( $p < 0.01$ ) in calcification + aldosterone group; compared with aldosterone group, the content of the IL-6 was slightly increased by 5.66% ( $p < 0.01$ ) in calcifica-

tion + aldosterone group, whereas that was decreased by 16.50% ( $p < 0.01$ ) in calcification + spriolactone group; compared with calcification group, the content of the IL-6 was slightly increased by 5.95% ( $p < 0.05$ ) in calcification + aldosterone group, while that was decreased by 16.28% ( $p < 0.01$ ) in calcification + spriolactone group; compared with calcification + spriolactone group, the content of the IL-6 was increased by 26.55% ( $p < 0.01$ ) in calcification + aldosterone group (Fig. 5B).

Compared with control group, the content of the TNF- $\alpha$  was increased by 27.80% ( $p < 0.01$ ) in aldosterone group, 20.95% ( $p < 0.01$ ) in calcification group, and 32.99% ( $p < 0.01$ ) in calcification + aldosterone group;



**Fig. 3. The calcium content and the activity of ALP in the aorta tissue.** (A) Calcium content in the aorta (Mean  $\pm$  SEM,  $n = 8$ ). (B) Activity of ALP in the aorta (Mean  $\pm$  SEM,  $n = 8$ ).



**Fig. 4. Masson's trichrome staining in the aorta (A) and myocardium (B): positive staining was illustrated with blue areas (10  $\times$  20).** (A1, B1) Control group. (A2, B2) Aldosterone group. (A3, B3) Calcification group. (A4, B4) Calcification + aldosterone group. (A5, B5) Calcification + spriolactone group. (A1) 29.62%, (A2) 59.87%, (A3) 76.25%, (A4) 84.37%, (A5) 43.87%,  $\chi^2 = 37.21$ ,  $\nu = 4$ ;  $p = 0.0001$ . (B1) 19.00%, (B2) 49.62%, (B3) 42.25%, (B4) 51.00%, (B5) 21.87%,  $\chi^2 = 34.31$ ,  $\nu = 4$ ;  $p = 0.0001$ .

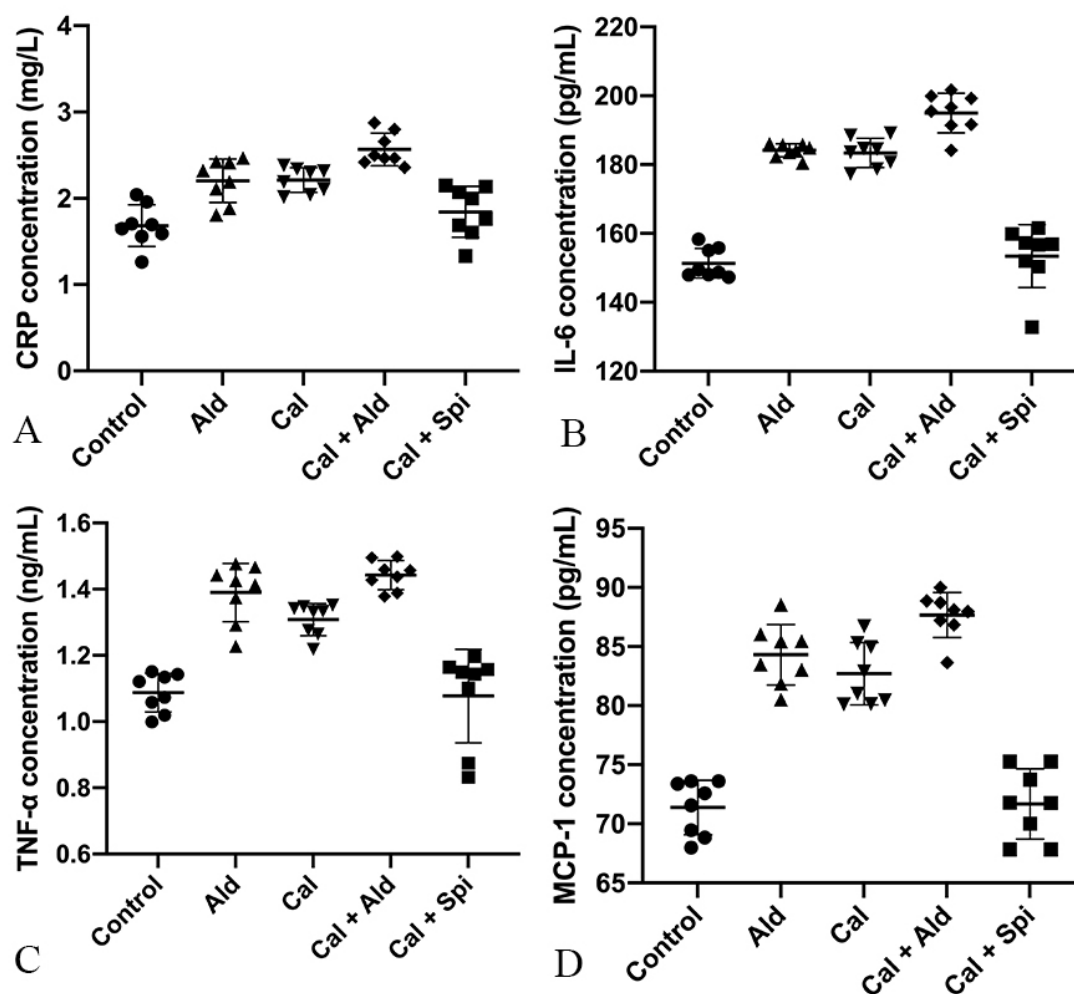
compared with aldosterone group, the content of TNF- $\alpha$  was slightly increased without observing significant differences ( $p > 0.05$ ) in calcification + aldosterone group, while that was decreased by 22.12% ( $p < 0.01$ ) in calcification + spriolactone group; compared with calcification group, the content of the TNF- $\alpha$  was slightly increased by 9.96% ( $p < 0.05$ ) in calcification + aldosterone group, whereas that was decreased by 17.70% ( $p < 0.01$ ) in calcification + spriolactone group; compared with calcification + spriolactone group, the content of the TNF- $\alpha$  was increased by 33.61% ( $p < 0.01$ ) in calcification + aldosterone group (Fig. 5C).

Compared with control group, the content of the MCP-1 was increased by 18.37% ( $p < 0.01$ ) in aldosterone group, 17.79% ( $p < 0.01$ ) in calcification group, and 23.47% ( $p < 0.01$ ) in calcification + aldosterone group; compared with aldosterone group, the content of the MCP-1 was increased by 4.31% ( $p < 0.05$ ) in calcification + aldosterone group, while that was decreased by 14.16% ( $p < 0.01$ ) in calcification + spriolactone group; compared with

calcification group, the content of the MCP-1 was increased by 4.82% ( $p < 0.05$ ) in calcification + aldosterone group, whereas that was decreased by 13.74% ( $p < 0.01$ ) in calcification + spriolactone group; compared with calcification + spriolactone group, the content of the MCP-1 was increased by 21.51% ( $p < 0.01$ ) in calcification + aldosterone group (Fig. 5D).

#### 4.6 The content of Urotensin II and aldosterone in the aorta tissue

Compared with control group, the content of the aortic Urotensin II was significantly increased by 121.15% ( $p < 0.01$ ) in aldosterone group, 57.71% ( $p < 0.01$ ) in calcification group, 107.22% ( $p < 0.01$ ) in calcification + aldosterone group, and 60.92% ( $p < 0.05$ ) in calcification + spriolactone group; compared with aldosterone group, the content of the aortic Urotensin II was decreased by 25.66% ( $p < 0.05$ ) in calcification group, and 24.15% ( $p < 0.05$ ) in calcification + spriolactone group; compared with calcifica-



**Fig. 5.** Content of the C-reactive protein, IL-6, TNF- $\alpha$  and MCP-1 in serum. (A) C-reactive protein (Mean  $\pm$  SEM,  $n = 8$ ). (B) Interleukin-6 (Mean  $\pm$  SEM,  $n = 8$ ). (C) Tumor necrosis factor- $\alpha$  (Mean  $\pm$  SEM,  $n = 8$ ). (D) Monocyte chemoattractant protein-1 (Mean  $\pm$  SEM,  $n = 8$ ).

tion group, the content of aortic Urotensin II was increased by 31.40% ( $p < 0.05$ ) in calcification + aldosterone group; compared with calcification + aldosterone group, the content of the aortic Urotensin II was decreased by 22.35% ( $p < 0.05$ ) in calcification + spriolactone group. There were no significant differences in plasma aldosterone contents among the 5 groups as well, as shown in Fig. 6A.

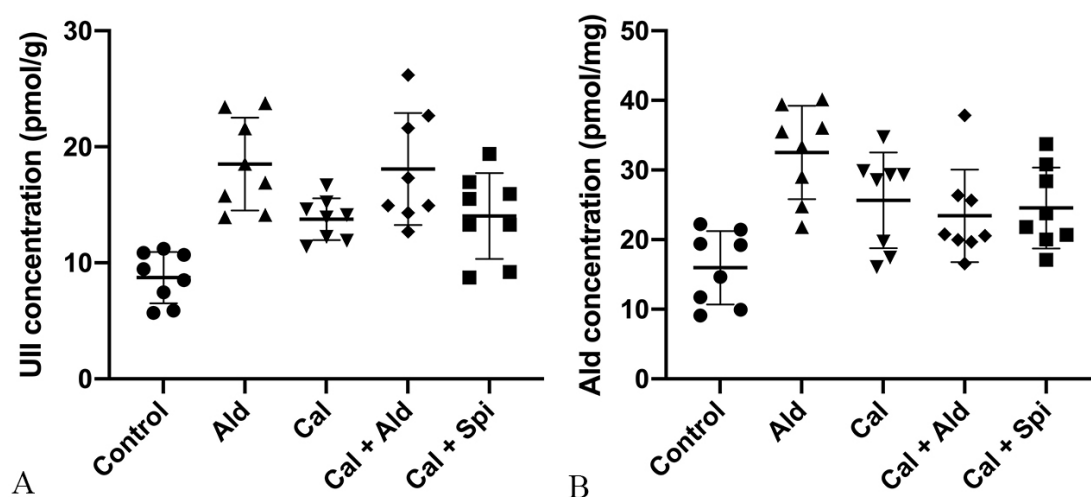
Compared with control group, the content of the aortic aldosterone was increased by 103.76% ( $p < 0.01$ ) in aldosterone group, 60.59% ( $p < 0.05$ ) in calcification group, 46.74% ( $p < 0.05$ ) in calcification + aldosterone group, and 53.76% ( $p < 0.05$ ) in calcification + spriolactone group; compared with aldosterone group, the content of the aortic aldosterone was decreased by 21.19% ( $p < 0.05$ ) in calcification group, 27.98% ( $p < 0.05$ ) in calcification + aldosterone group, and 24.54% ( $p < 0.05$ ) in calcification + spriolactone group; there were no significant differences among calcification group, calcification + aldosterone group, and calcification + spriolactone group (Fig. 6B).

#### 4.7 The change of the immunoreactivity

Compared with control group, the mineralocorticoid receptor immunoreactivity, the immunoreactivity of OPN, the receptor immunoreactivity of the Urotensin II, IL-6, MCP-1 in calcification group and aldosterone group were increased, those also were significantly increased in calcification + aldosterone, and slightly increased in calcification + spriolactone group (Fig. 7).

## 5. Discussion

Vascular calcification is a basic pathology of atherosclerosis, hypertension, diabetes, chronic kidney disease, and aging. Accumulating evidence have mentioned a tightly regulated process, associating with a competition between various factors in promoting calcification and inhibitors of mineralization, but the cellular mechanisms remain unclear [1–5]. Aldosterone causes retention of sodium water and can promote collagen deposition and fibrosis,



**Fig. 6. Content of Urotensin II and aldosterone in the aorta tissue.** (A) Urotensin II (Mean  $\pm$  SEM,  $n = 8$ ). (B) Aldosterone in the aorta (Mean  $\pm$  SEM,  $n = 8$ ).

leading to fibrosis and structural remodeling of the heart. In this study, we used Vitamin D3 plus nicotine (VDN) to create vascular calcification model rat, and we found that aldosterone was involved in vascular calcification.

Firstly, we found that exogenous aldosterone could increase vascular calcification in rats. The expression of aldosterone and MR were increased in calcific rats' aorta. The MR was increased significantly, the activity of ALP was up-regulated, and mineral deposition was increased treated with aldosterone in calcific rats. The expression of collagen deposition, Urocortin II and its receptor, and inflammatory factor and its receptor were increased in calcific rats' aorta. Besides, it was released that the aldosterone can promote the expression of all the factors to increase vascular calcification.

Vascular calcification is a complicated dynamic process, involving several regulation factors, such as up-regulated activity of ALP, expressive type transformation of vascular smooth muscle cell, and crystal deposition [1–5]. Vitamin D3 with its receptors could increase vascular calcification in vitro by promoting the expression of matrix vesicle, elastin, and collagen [3]. The up-regulation of the activity of ALP is an early biochemical marker for vascular calcification. The ALP modulates vascular calcification by decreasing the levels of inorganic pyrophosphate; pyrophosphate is a substrate for ALP and a potent inhibitor for vascular calcification [3]. We found that ALP and the content of aldosterone were increased in calcific rats' aorta, and exogenous aldosterone could increase the effects; however, that was lightened by spironolactone, demonstrating that endogenous and exogenous aldosterone could increase vascular calcification in rats, and the effect can be lightened by spironolactone. We found that there were no significant differences in plasma aldosterone contents among the 5 groups, thus, the effect of the aldosterone might be involved in the development of vascular calcification, in a

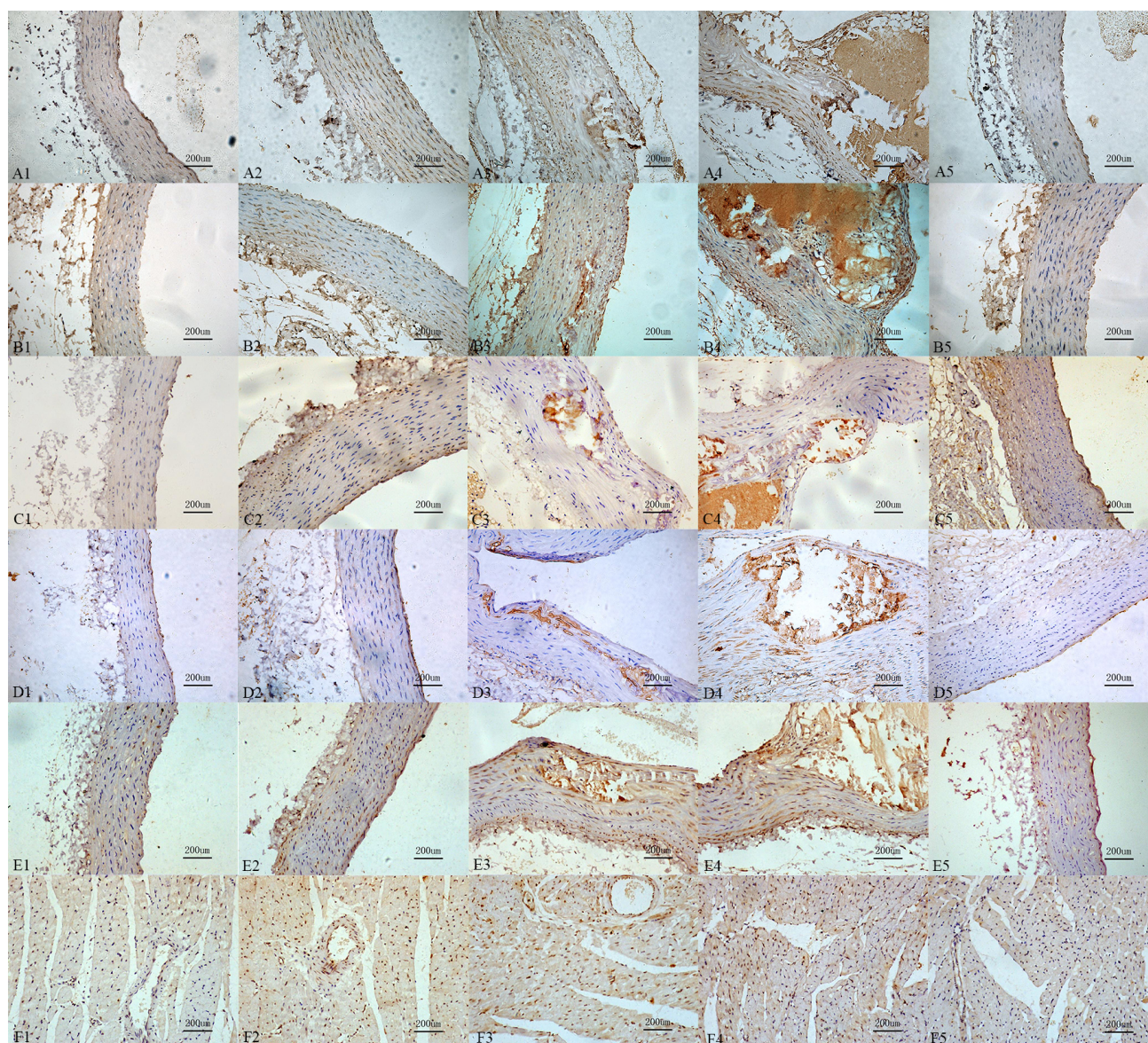
paracrine and/or autocrine manner. Besides, the calcified rats' aorta is calcification or segmental, therefore, the expression of aldosterone in calcification + aldosterone group of aorta was not increased, compared with the aldosterone group [1–5].

We confirmed that collagen [30] and an inflammatory factor [31, 32] are involved in vascular calcification, and demonstrated that exogenous aldosterone could increase their expressions to aggravate calcification. Inflammatory stimulation could increase formation of calcium nodes through AKT and Wnt signaling pathways [33, 34]. In addition, it was revealed that collagen is hypertrophy in calcific nodules, and also collagen may be associated with the baseball Brackets for vascular calcification, in favor of the expression of the factors, promoting calcification. In addition, it was revealed that collagen is hypertrophic in calcified nodules. The factors promoting vascular calcification coordinated and interacted with each other, and eventually the occurrence and development of vascular calcification were noted.

Urotensin II is a vasoconstrictive peptide that exerts its activity by binding to GPR14-the specific receptor of Urotensin II [35]. Previous research showed that it could increase the inflammatory factor to promote cardiac fibrosis, and demonstrated that Urotensin II is involved in vascular calcification by stimulating the inflammatory factor and collagen through the protein kinase C, mitogen-activated protein kinase, calcineurin, Rho kinase, and/or Ca2t signal transduction pathway [36]. Besides, aldosterone can significantly enhance its effects.

Ectopic calcification is exacerbated in OPN deficient mice, and this process is mitigated by adding exogenous OPN, that is phosphorylated and contains the arginine-glycine-aspartate (RGD) sequence [37]. Detailed analyses of OPN inhibition of hydroxyapatite and calcium oxalate (nephrolithiasis) indicated that phosphorylation of OPN de-





**Fig. 7. Immunoreactivity change for the different receptors and proteins.** Interleukin-6 (A1: 9.87%, A2: 37.16%, A3: 66.38%, A4: 75.75%, A5: 17.87%,  $\chi^2 = 37.49$ ,  $\nu = 4$ ,  $p = 0.0001$ ); Monocyte chemoattractant protein-1 (B1: 9.12%, B2: 30.50%, B3: 58.00%, B4: 78.37%, B5: 17.00%,  $\chi^2 = 35.64$ ,  $\nu = 4$ ,  $p = 0.005$ ); Urotensin II (C1: 7.62%, C2: 28.00%, C3: 31.00%, C4: 42.00%, C5: 27.87%,  $\chi^2 = 32.392$ ,  $\nu = 4$ ,  $p = 0.0001$ ); Osteopontin (D1: 4.37%, D2: 11.25%, D3: 31.62%, D4: 63.63%, D5: 15.00%,  $\chi^2 = 36.80$ ,  $\nu = 4$ ,  $p = 0.0001$ ); Mineralocorticoid (E1: 13.62%, E2: 27.62%, E3: 45.37%, E4: 61.00%, E5: 33.47%,  $\chi^2 = 37.51$ ,  $\nu = 4$ ,  $p = 0.0001$ ) in the aorta; Mineralocorticoid receptor immunoreactivity in the myocardium (F1: 14.62%, F2: 29.50%, F3: 32.25%, F4: 33.62%, F5: 15.00%,  $\chi^2 = 33.20$ ,  $\nu = 4$ ,  $p = 0.001$ ). All the tissue positive staining was marked with brown yellow areas ( $10 \times 20$ ), and sub-grouped by 1: control group, 2: aldosterone group, 3: calcification group, 4: calcification + aldosterone group, 5: calcification + spriolactone group.

finds its inhibitory potential. However, OPN is a factor, promoting fibrosis [38, 39]. Due to the collagen is hypertrophy in calcific nodules, so we conjectured that OPN may be an inhibitor for mineralization, which is phosphorylated and contains the RGD sequence.

Calcium and phosphorus metabolism disorders, activation of phosphate signaling channels [40–42]; BMP (bone morphogenetic protein)/Smads, bone protection element (OPG), nuclear factor  $\kappa$ B receptor activated receptor protein (RANK) regulation [43–47], Wnt/ $\beta$ -catenin signal-

ing pathway [48–50], through activation of matrix metalloproteinases 2 and 9 factors, such as matrix metalloproteinases [50], play a substantial role in the whole process of calcification. Stimulated by calcifying factors, VSMCS transform into osteoblasts/cartilages, release stromal vesicles [51], and nucleate calcium phosphate crystals in the form of hydroxyapatite. The drive of oxidative stress and inflammatory response [52], and the downregulation of microRNA caused by various factors [45, 53] can all promote vascular calcification.



In conclusion, aldosterone and mineralocorticoid receptor are significantly increased in calcified vessels, suggesting that aldosterone may be involved in the development of vascular calcification, in a paracrine and/or autocrine manner, and this effect is mediated by the mineralocorticoid receptor. The aldosterone regulates vascular calcification by promoting the expression of collagen, Urotensin II and its receptor in the aorta wall, upregulating the expression of the inflammatory factor and the corresponding receptor in the aorta wall. In addition, OPN is a contentious factor for inhibiting vascular calcification, as well as promoting vascular fibrosis in a paracrine and/or autocrine manner.

## 6. Conclusions

Aldosterone may be involved in the development of vascular calcification, and the regulation of it has a promising effect in inhibiting the vascular calcification. However, gene or protein expressions of IL6, MCP1, OPN during this pathology process should be further explored, and the signaling mechanisms needs to be further studied.

## 7. Author contributions

XZ (Xusheng Zhang), ZH, XF and XT carried out the studies, participated in collecting data, and drafted the manuscript. XZ (Xusheng Zhang) performed the statistical analysis and participated in its design. CL, XZ (Xusheng Zhang) and JY participated in acquisition, analysis, or interpretation of data and draft the manuscript. XZ (Xiaoou Zhou) carried out the experiment and drafted the manuscript during the study. All authors read and approved the final manuscript.

## 8. Ethics approval and consent to participate

The study protocol was approved by the Ethics Committees of the Tianjin Medical University (TMU-2020-LLSC-0106).

## 9. Acknowledgment

Not applicable.

## 10. Funding

This work was supported by research grants from the National Natural Science Foundation of China (grant number 81970303).

## 11. Conflict of interest

The authors declare no conflict of interest.

## 12. Availability of data and materials

The datasets used and/or analyzed during the current study are available from the corresponding author on reasonable request.

## 13. References

- [1] Sage AP, Tintut Y, Demer LL. Regulatory mechanisms in vascular calcification. *Nature Reviews Cardiology*. 2010; 7: 528–536.
- [2] Pugliese G, Iacobini C, Blasetti Fantauzzi C, Menini S. The dark and bright side of atherosclerotic calcification. *Atherosclerosis*. 2015; 238: 220–230.
- [3] Toutouzas K, Benetos G, Karanasos A, Chatzizisis YS, Giannopoulos AA, Tousoulis D. Vulnerable plaque imaging: updates on new pathobiological mechanisms. *European Heart Journal*. 2015; 36: 3147–3154.
- [4] Leopold JA. Vascular calcification: Mechanisms of vascular smooth muscle cell calcification. *Trends in Cardiovascular Medicine*. 2015; 25: 267–274.
- [5] Hou QC, Wang JW, Yuan G, Wang YP, Xu KQ, Zhang L, et al. AGEs promote calcification of HASMCs by mediating Pi3k/AKT-GSK3 $\beta$  signaling. *Frontiers in Bioscience-Landmark*. 2021; 26: 125–134.
- [6] Quaglini D, Boraldi F, Lofaro FD. The biology of vascular calcification. *International Review of Cell and Molecular Biology*. 2020; 25: 261–353.
- [7] Brown J, de Boer IH, Robinson-Cohen C, Siscovick DS, Kestenbaum B, Allison M, et al. Aldosterone, parathyroid hormone, and the use of renin-angiotensin-aldosterone system inhibitors: the multi-ethnic study of atherosclerosis. *The Journal of Clinical Endocrinology and Metabolism*. 2015; 100: 490–499.
- [8] Rossi GP, Caroccia B, Seccia TM. Role of estrogen receptors in modulating aldosterone biosynthesis and blood pressure. *Steroids*. 2019; 152: 108486.
- [9] Pantelidis P, Sideris M, Viigimaa M, Avranas K, Deligkaris P, Zografou I, et al. The Mechanisms of Actions of Aldosterone and its Antagonists in Cardiovascular Disease. *Current Pharmaceutical Design*. 2019; 24: 5491–5499.
- [10] Tsai C, Yang S, Chu H, Ueng K. Cross-talk between mineralocorticoid receptor/angiotensin II type 1 receptor and mitogen-activated protein kinase pathways underlies aldosterone-induced atrial fibrotic responses in HL-1 cardiomyocytes. *International Journal of Cardiology*. 2013; 169: 17–28.
- [11] Brown NJ. Contribution of aldosterone to cardiovascular and renal inflammation and fibrosis. *Nature Reviews Nephrology*. 2013; 9: 459–469.
- [12] Patel V, Joharapurkar A, Jain M. Role of mineralocorticoid receptor antagonists in kidney diseases. *Drug Development Research*. 2021; 82: 341–363.
- [13] Ruhs S, Strätz N, Schlör K, Meinel S, Mildenerger S, Rabe S, et al. Modulation of transcriptional mineralocorticoid receptor activity by nitrosative stress. *Free Radical Biology and Medicine*. 2012; 53: 1088–1100.
- [14] Gorini S, Kim SK, Infante M, Mammi C, La Vignera S, Fabbri A, et al. Role of Aldosterone and Mineralocorticoid Receptor in Cardiovascular Aging. *Frontiers in Endocrinology*. 2019; 10: 584.
- [15] Harvey AP, Montezano AC, Hood KY, Lopes RA, Rios F, Ceravolo G, et al. Vascular dysfunction and fibrosis in stroke-prone spontaneously hypertensive rats: the aldosterone-mineralocorticoid receptor-Nox1 axis. *Life Sciences*. 2017; 179: 110–119.
- [16] Vecchiola A, Fuentes CA, Solar I, Lagos CF, Opazo MC,

- Muñoz-Durango N, *et al.* Eplerenone implantation improved adipose dysfunction averting RAAS activation and cell division. *Frontiers in Endocrinology*. 2020; 11: 223.
- [17] Ren R, Oakley RH, Cruz-Topete D, Cidlowski JA. Dual role for glucocorticoids in cardiomyocyte hypertrophy and apoptosis. *Endocrinology*. 2012; 153: 5346–5360.
- [18] Lu M, Wang P, Zhou S, Flickinger B, Malhotra D, Ge Y, *et al.* Ecdysone Elicits Chronic Renal Impairment via Mineralocorticoid-Like Pathogenic Activities. *Cellular Physiology and Biochemistry*. 2018; 49: 1633–1645.
- [19] Gao J, He W, Xie C, Gao M, Feng L, Liu Z, *et al.* Aldosterone enhances high phosphate-induced vascular calcification through inhibition of AMPK-mediated autophagy. *Journal of Cellular and Molecular Medicine*. 2020; 24: 13648–13659.
- [20] Hao J, Zhang L, Cong G, Ren L, Hao L. MicroRNA-34b/c inhibits aldosterone-induced vascular smooth muscle cell calcification via a SATB2/Runx2 pathway. *Cell and Tissue Research*. 2016; 366: 733–746.
- [21] Zou C, Pei S, Yan W, Lu Q, Zhong X, Chen Q, *et al.* Cerebrospinal fluid Osteopontin and inflammation-associated cytokines in patients with anti-N-methyl-D-aspartate receptor encephalitis. *Frontiers in Neurology*. 2020; 11: 519692.
- [22] Lok ZSY, Lyle AN. Osteopontin in Vascular Disease. *Arteriosclerosis, Thrombosis, and Vascular Biology*. 2019; 39: 613–622.
- [23] Castello LM, Raineri D, Salmi L, Clemente N, Vaschetto R, Quaglia M, *et al.* Osteopontin at the Crossroads of Inflammation and Tumor Progression. *Mediators of Inflammation*. 2017; 2017: 4049098.
- [24] Zhao H, Chen Q, Alam A, Cui J, Suen KC, Soo AP, *et al.* The role of osteopontin in the progression of solid organ tumour. *Cell Death & Disease*. 2018; 9: 356.
- [25] Wang Y, Han D, Wang H, Liu M, Zhang X, Wang H. Downregulation of osteopontin is associated with fluoxetine amelioration of monocrotaline-induced pulmonary inflammation and vascular remodelling. *Clinical and Experimental Pharmacology and Physiology*. 2011; 38: 365–372.
- [26] Hunter GK. Role of osteopontin in modulation of hydroxyapatite formation. *Calcified Tissue International*. 2013; 93: 348–354.
- [27] Giachelli CM, Speer MY, Li X, Rajachar RM, Yang H. Regulation of vascular calcification: roles of phosphate and osteopontin. *Circulation Research*. 2005; 96: 717–722.
- [28] Ge Q, Ruan C, Ma Y, Tang X, Wu Q, Wang J, *et al.* Osteopontin regulates macrophage activation and osteoclast formation in hypertensive patients with vascular calcification. *Scientific Reports*. 2017; 7: 40253.
- [29] Herrmann J, Babic M, Tölle M, van der Giet M, Schuchardt M. Research models for studying vascular calcification. *International Journal of Molecular Sciences*. 2020; 21: 2204.
- [30] Jover E, Silvente A, Marin F, Martinez-Gonzalez J, Orriols M, Martinez CM, *et al.* Inhibition of enzymes involved in collagen cross-linking reduces vascular smooth muscle cell calcification. *The Federation of American Societies for Experimental Biology Journal*. 2018; 32: 4459–4469.
- [31] Viegas C, Araújo N, Marreiros C, Simes D. The interplay between mineral metabolism, vascular calcification and inflammation in Chronic Kidney Disease (CKD): challenging old concepts with new facts. *Aging*. 2019; 11: 4274–4299.
- [32] Qin Z, Liao R, Xiong Y, Jiang L, Li J, Wang L, *et al.* A narrative review of exosomes in vascular calcification. *Annals of Translational Medicine*. 2021; 9: 579–579.
- [33] Liu M, Li F, Huang Y, Zhou T, Chen S, Li G, *et al.* Caffeic acid phenethyl ester ameliorates calcification by inhibiting activation of the AKT/NF- $\kappa$ B/NLRP3 inflammasome pathway in human Aortic valve interstitial cells. *Frontiers in Pharmacology*. 2020; 11: 826.
- [34] Rashdan NA, Sim AM, Cui L, Phadwal K, Roberts FL, Carter R, *et al.* Osteocalcin Regulates Arterial Calcification via Altered Wnt Signaling and Glucose Metabolism. *Journal of Bone and Mineral Research*. 2020; 35: 357–367.
- [35] Ames RS, Sarau HM, Chambers JK, Willette RN, Aiyar NV, Romanic AM, *et al.* Human urotensin-II is a potent vasoconstrictor and agonist for the orphan receptor GPR14. *Nature*. 1999; 401: 282–286.
- [36] Lee JH, Park BK, Oh K, Yi KY, Lim CJ, Seo HW, *et al.* A urotensin II receptor antagonist, KR36676, decreases vascular remodeling and inflammation in experimental pulmonary hypertension. *International Immunopharmacology*. 2016; 40: 196–202.
- [37] Ohri R, Tung E, Rajachar R, Giachelli CM. Mitigation of ectopic calcification in osteopontin-deficient mice by exogenous osteopontin. *Calcified Tissue International*. 2005; 76: 307–315.
- [38] Schulien I, Hockenjos B, Schmitt-Graeff A, Perdekamp MG, Follo M, Thimme R, *et al.* The transcription factor c-Jun/AP-1 promotes liver fibrosis during non-alcoholic steatohepatitis by regulating Osteopontin expression. *Cell Death & Differentiation*. 2019; 26: 1688–1699.
- [39] Lin R, Wu S, Zhu D, Qin M, Liu X. Osteopontin induces atrial fibrosis by activating Akt/GSK-3 $\beta$ /catenin pathway and suppressing autophagy. *Life Sciences*. 2020; 245: 117328.
- [40] Leem J, Lee IK. Mechanisms of Vascular Calcification: the Pivotal Role of Pyruvate Dehydrogenase Kinase 4. *Endocrinology and Metabolism*. 2016; 31: 52–61.
- [41] Villa-Bellosta R, Egido J. Phosphate, pyrophosphate, and vascular calcification: a question of balance. *European Heart Journal*. 2017; 38: 1801–1804.
- [42] Gao Z, Li X, Miao J, Lun L. Impacts of parathyroidectomy on calcium and phosphorus metabolism disorder, arterial calcification and arterial stiffness in haemodialysis patients. *Asian Journal of Surgery*. 2019; 42: 6–10.
- [43] Bae SJ, Kim HJ, Won HY, Min YK, Hwang ES. Acceleration of osteoblast differentiation by a novel osteogenic compound, DMP-PYT, through activation of both the BMP and Wnt pathways. *Scientific Reports*. 2017; 7: 8455.
- [44] Harper E, Forde H, Davenport C, Rochford KD, Smith D, Cummins PM. Vascular calcification in type-2 diabetes and cardiovascular disease: Integrative roles for OPG, RANKL and TRAIL. *Vascular Pharmacology*. 2016; 82: 30–40.
- [45] Wang S, Wang C, Chen H. MicroRNAs are critical in regulating smooth muscle cell mineralization and apoptosis during vascular calcification. *Journal of Cellular and Molecular Medicine*. 2020; 24: 13564–13572.
- [46] Kiechl S, Werner P, Knoflach M, Furtner M, Willeit J, Schett G. The osteoprotegerin/RANK/RANKL system: a bone key to vascular disease. *Expert Review of Cardiovascular Therapy*. 2006; 4: 801–811.
- [47] Rochette L, Meloux A, Rigal E, Zeller M, Malka G, Cottin Y, *et al.* The Role of Osteoprotegerin in Vascular Calcification and Bone Metabolism: the Basis for Developing New Therapeutics. *Calcified Tissue International*. 2019; 105: 239–251.
- [48] Cheng S, Ramachandran B, Behrmann A, Shao J, Mead M, Smith C, *et al.* Vascular smooth muscle LRP6 limits arteriosclerotic calcification in diabetic LDLR $^{-/-}$  mice by restraining non-canonical Wnt signals. *Circulation Research*. 2015; 117: 142–156.
- [49] Weerackoon N, Gunawardhana KL, Mani A. Wnt signaling cascades and their role in coronary artery health and disease. *Cellular Signalling*. 2021; 2: 52–62.
- [50] Aloui S, Zidi W, Ouali S, Guizani I, Hadj-Taieb S, Mourali MS, *et al.* Association of matrix metalloproteinase 3 and endogenous inhibitors with inflammatory markers in mitral valve disease and

- calcification. *Molecular Biology Reports*. 2018; 45: 2135–2143.
- [51] Disthabanchong S, Srisuwarn P. Mechanisms of Vascular Calcification in Kidney Disease. *Advances in Chronic Kidney Disease*. 2019; 26: 417–426.
- [52] Zhong S, Li L, Shen X, Li Q, Xu W, Wang X, *et al*. An update on lipid oxidation and inflammation in cardiovascular diseases. *Free Radical Biology and Medicine*. 2019; 144: 266–278.
- [53] Han Y, Zhang J, Huang S, Cheng N, Zhang C, Li Y, *et al*. MicroRNA-223-3p inhibits vascular calcification and the osteogenic switch of vascular smooth muscle cells. *Journal of Biological Chemistry*. 2021; 296: 100483.

**Abbreviations:** VDN, Vitamin D3 plus nicotine; IL-6, interleukin-6; ALP, alkaline phosphatase; CKD, chronic kidney disease; RAAS, renin-angiotensin-aldosterone system; MR, mineralocorticoid receptor; OPN, Osteopontin; TNF- $\alpha$ , tumor necrosis factor- $\alpha$ .

**Keywords:** Aldosterone; Vascular calcification; Inflammatory factor; Collagen; Osteopontin; Urotensin II

# Send correspondence to:

Chengzhi Lu, Department of Cardiology, The First Central Clinical College of Tianjin Medical University, 300070 Tianjin, China, Department of Cardiology, Tianjin First Central Hospital, 300070 Tianjin, China, E-mail: [5020200072@nankai.edu.cn](mailto:5020200072@nankai.edu.cn)

Jianshe Yang, Department of Cardiology, Longgang People's Hospital of Shenzhen, 518172 Shenzhen, Guangdong, China, Department of Nuclear Medicine, Shanghai Tenth People's Hospital, Tongji University, 200072 Shanghai, China, E-mail: [yangjs@impcas.ac.cn](mailto:yangjs@impcas.ac.cn)