

MMP-9 expression is associated with leukocytic but not endothelial markers in brain arteriovenous malformations

Yongmei Chen¹, Yongfeng Fan¹, K. Y. Trudy Poon¹, Achal S. Achrol¹, Michael T. Lawton², Yiqian Zhu¹, Charles E McCulloch⁴, Tomoki Hashimoto¹, Chanhung Lee¹, Nicholas M. Barbaro², Andrew W. Bollen⁵, Guo-Yuan Yang^{1,2}, and William L. Young^{1,2,3}

¹ Center for Cerebrovascular Research, Department of Anesthesia and Perioperative Care, Departments of ² Neurological Surgery, ³ Neurology, ⁴ Epidemiology and Biostatistics, and ⁵ Pathology, University of California, San Francisco, CA 94110

TABLE OF CONTENTS

1. Abstract
2. Introduction
3. Materials and methods
 - 3.1. Study subjects
 - 3.2. Enzyme-linked immunoadsorbent assays
 - 3.3. Gelatin zymography
 - 3.4. Western blot analysis
 - 3.5. Immunohistochemistry
 - 3.6. Statistical analysis
4. Results
 - 4.1. Clinical characteristics
 - 4.2. MPO and MMP-9 co-localized in BAVM tissue
 - 4.3. MMP-9 expression correlated with MPO, IL-6, but not with eNOS or CD31
 - 4.4. MMP-9 expression was associated with 125-kDa MMP-9 level
 - 4.5. Assessment of confounding factors on MMP-9 expression
 - 4.6. BAVM tissue displayed higher levels of inflammatory markers
5. Discussion
6. Acknowledgment
7. References

1. ABSTRACT

Brain arteriovenous malformations (BAVM) have high matrix metalloproteinase-9 (MMP-9) expression, the source of which is unclear. We hypothesized MMP-9 production might be due to inflammation in BAVM. Compared to control brain tissues (n=5), BAVM tissue (n=139) had a higher expression (by ELISA) of myeloperoxidase (MPO) (193±189 vs. 6±3, ng/mg, P<.001), MMP-9 (28±32 vs. 0.7±0.6, ng/mg, P<.001), and IL-6 (102±218 vs. 0.1±0.1, pg/mg, P<.001), but not eNOS (114±87 vs. 65±9, pg/mg, P=.09). MMP-9 expression in BAVM highly correlated with myeloperoxidase (R²=.76, P<.001), as well as with IL-6 (R²=.32, P<.001). In contrast, MMP-9 in BAVM poorly correlated with the endothelial marker, eNOS (R²=.03, P=.05), and CD31 (R²=.004, P=.57). Compared to non-embolized patients (n=46), patients with pre-operative embolization (n=93) had higher levels of myeloperoxidase (236±205 vs. 106±108, ng/mg, P<.001) and MMP-9 (33±35 vs. 16±20, ng/mg, P<.001), however the correlation between MMP-9 and myeloperoxidase was equally strong for both groups (R²=.69, n=93, P<.001, for both). MMP-9 expression correlated with the lipocalin-MMP-9 complex, suggesting neutrophils as the MMP-9 source. MPO co-localized with majority of MMP-9 signal by immunohistochemistry. Our data suggest that inflammation is a prominent feature of BAVM lesional phenotype, and neutrophils appear to be a major source of MMP-9 in these lesions.

2. INTRODUCTION

Brain arteriovenous malformations (BAVM) most commonly present with intracranial hemorrhage (ICH). The nature of the vascular instability that results in vessel rupture is unknown. Vascular inflammation is central to the pathogenesis of several diseases including intracranial aortic aneurysm expansion (1), and abdominal aortic aneurysm formation (2, 3). We have previously described an association between promoter single nucleotide polymorphisms (SNPs) in inflammatory cytokine genes and BAVM ICH risk; a TNF- α SNP was associated with increased risk of new ICH in the natural course of BAVM (4), and an IL-6 SNP was associated with a hemorrhagic clinical presentation (5). Further, the highest risk IL-6 genotype (GG) was associated with the highest IL-6 expression levels in BAVM lesional tissue (6).

MMPs are a family of neutral proteases that play important roles in maintaining and remodeling the extracellular matrix (7). MMPs, including MMP-9, are major components of neutrophilic tertiary granules, and are also expressed by other types of leukocytes including monocytes, and lymphocytes. During inflammation, MMP-9 expression and activity are stimulated by cytokines such as IL-8, IL-1 β , and IL-6. MMP-9 can degrade key components of the cerebrovascular matrix including laminin, denatured collagen, and tight junction proteins such as ZO-1 leading to BBB leakage, and brain hemorrhage (8, 9).

We have shown that MMP-9 level was higher in BAVM lesional tissue compared to control brain tissue removed during microsurgical resection (10). What is not known is the cellular source for the elevated MMP-9 level in BAVM tissue. Therefore, we undertook a study to investigate the cellular source of MMP-9 production in a large cohort of patients with resected brain tissue. The primary analysis was localization of MMP-9 expression by immunohistochemistry in BAVM tissue. The relation between MMP-9 level and leukocyte specific marker, MPO, was further determined quantitatively by ELISA. In addition, we also examined the expression of inflammatory and vascular markers in BAVM tissue compared to control brain tissue.

3. MATERIALS AND METHODS

3.1. Study subjects

All studies were IRB approved and patients gave informed consent. Beginning in 2000, all patients with BAVM evaluated at the University of California San Francisco (UCSF) were enrolled in an ongoing prospective registry that includes clinical attributes and surgical tissue samples, as previously described (11). Data on patient demographics, radiographic features of the BAVM, initial clinical presentation at diagnosis, treatment history, follow-up, and outcome (including hemorrhages occurring after initial diagnosis) were collected. BAVM characteristics such as size, location, and venous drainage pattern were documented based on standardized guidelines (12). Control cerebral cortex was obtained from patients undergoing surgical treatment of epilepsy as previously described (13, 14). Samples were taken from structurally normal temporal lobe remote from the epileptogenic focus.

3.2. Enzyme-linked immunoadsorbent assays (ELISA)

MPO levels were measured by ELISA according to the protocols provided by the manufacturer (Calbiochem, San Diego, CA). Protein levels of interleukin-6 (IL-6), endothelial nitric oxide synthase (eNOS), and MMP-9 in tissue specimens were measured using specific ELISA kits (R&D systems Inc., Minneapolis, MN). MPO is a hemoprotein present at high levels in neutrophils and, to a lesser extent, in monocytes, and was assessed as a marker for neutrophils (15). The eNOS isoform of NOS is considered an endothelial cell marker (16), and assessed as an index for endothelial cell mass in BAVM tissue.

3.3. Gelatin zymography

Gelatin zymography was performed as described (17,18). Briefly, protein samples of 40 µg was separated in a 10% zymogram gel (Invitrogen, Carlsbad, CA). Following electrophoresis, gels were washed, and incubated in developing buffer overnight at 37°C. Protein bands in zymography were quantified by scanning densitometry using a KODAK image analysis software (Eastman Kodak Company). In preliminary experiments, controls with increasing amounts of protein verified that quantitative band intensities fell within a linear range.

3.4. Western blot analysis

As a quality control measure, we also examined CD31 expression as an alternative assay of endothelial cell

mass in a subset of cases (18). An equal amount of protein was electrophoresed on 7% sodium dodecyl sulfate polyacrylamide gels. Subsequently, proteins were transferred onto polyvinylidene difluoride membranes. The membranes were then probed with a primary antibody CD31 (Santa Cruz Biotechnology, Inc., Santa Cruz, CA) for 1 hour, followed by incubation with horseradish-peroxidase (HRP)-conjugated sheep anti-mouse IgG (Bio-Rad Laboratories) secondary antibody. Protein expression was detected with an enhanced chemiluminescence detection system (ECL+Plus, Amersham Pharmacia Biotech Inc). In preliminary experiments, controls with increasing amounts of protein verified that quantitative band intensities fell within a linear range.

3.5. Immunohistochemistry

Brain sections at 10 µm were deparaffinized and rehydrated. After blocking, sections were incubated with primary antibodies diluted in PBS with 0.1% Triton X-100 at the following concentrations: mouse monoclonal anti-human-MPO, 1:2000 (Serotec, Raleigh, NC), mouse monoclonal anti-human-CD68, 1:1000 (Serotec, Raleigh, NC), mouse monoclonal anti-human-CD31 1:100 (Santa Cruz Biotechnology, Inc.), mouse monoclonal anti-NeuN, 1:1000 (Chemicon, Temecula, CA), mouse monoclonal anti-GFAP, 1:2000 (Chemicon), mouse monoclonal anti-human α -smooth muscle actin, 5g/ml, (Chemicon), and rabbit polyclonal anti-human-MMP-9, 1:800 (Chemicon). After incubating at 4°C overnight, and washing in PBS, the sections were incubated with biotinylated goat anti-mouse (Vector Laboratories, Burlingame, CA) diluted 1:5000 for 1 hour at room temperature. The sections were treated with the ABC streptavidin detection system for 1 hour after washing with PBS. The resulting horseradish peroxidase signal was detected using 3,3'-diaminobenzidine. For dual fluorescent staining, after incubating at 4°C overnight with primary antibodies, sections were incubated with Alexa Fluor 594-conjugated goat anti-mouse or Alexa Fluor 488-conjugated goat anti-rabbit IgG (Molecular probes, Eugene, OR) at 1:500 dilution for 1 hour at room temperature. The sections were then mounted and photographed with fluorescent microscope. Negative controls were performed by omitting the primary antibodies during the immunostaining.

3.6. Statistical analysis

Descriptive statistics (mean \pm SD) of protein expression data were reported in raw values. Because the distribution of the raw values was heavily skewed, analyses of variance (ANOVA) to compare control and BAVM groups were performed on log-transformed values. Relative expression was examined by normalizing the BAVM and control group raw expression values to the mean values of the control group in order to express "fold difference compared to control" for IL-6, MPO, MMP-9, and eNOS. Correlations among measured protein expression data were examined using linear regression. Linear regression and analysis of covariance (ANCOVA) were employed to assess possible confounding effects of demographic and clinical factors on proteins of interest.

Two major confounding factors for data interpretation were prior embolization, and prior

MMP-9 is associated with MPO in BAVM

Table 1. Demographic information for the study cohort

		BAVM (%)	Control (%)
Age (Year)	Mean (SD)	36.1 (16.2)	31.4 (7.4)
Years from Embolization to Harvest	Mean (SD)	0.1 (0.4)	--
	N	93	
Years from Hemorrhage to Harvest	Mean (SD)	1.0 (4.2)	--
	N	73	
Years from GK surgery to Harvest	Mean (SD)	3.8 (2.5)	--
	N	9	
Sex	Male	76 (54.7%)	2 (40%)
	Female	63 (45.3%)	3 (60%)
	Total	139 (100%)	5 (100%)
Race/Ethnicity	White	73 (52.5%)	3 (60%)
	Black	7 (5.0%)	0 (0%)
	Hispanic	35 (25.2%)	2 (40%)
	Asian/PI	15 (10.8%)	0 (0%)
	Other/missing	9 (6.5%)	0 (0%)
	Total	139 (100%)	5 (100%)
BAVM Size	<3cm	73 (52.9%)	--
	3-6cm	63 (45.7%)	--
	>6cm	2 (1.4%)	--
	Total	138 (100%)	--
BAVM venous drainage	Superficial	82 (59.9%)	--
	Deep	16 (11.7%)	--
	Both	39 (28.5%)	--
	Total	137 (100%)	--
Eloquence	No	64 (47.1%)	--
	Yes	72 (52.9%)	--
	Total	136 (100%)	--
Spetzler-Martin Score	1	21 (15.4%)	--
	2	50 (36.8%)	--
	3	48 (35.3%)	--
	4	15 (11%)	--
	5	2 (1.5%)	--
	Total	136 (100%)	--
Initial Presentation	Unruptured	71 (51.1%)	--
	Ruptured	68 (48.9%)	--
	Total	139 (100%)	--

hemorrhage. These factors were further explored in the analysis. We examined the effect of time between prior hemorrhage and tissue harvest, and the time between pre-surgical embolization and harvest, treating the variables as both continuous and categorical. Prior hemorrhage included patients who presented initially with an unruptured lesion, and then went to have a bleed during the interval before surgical resection. Therefore, any clinical episode of hemorrhage, either incident or subsequent to presentation, was termed "prior hemorrhage". Statistical analyses were performed using SPSS.

4. RESULTS

4.1. Clinical characteristics

The cohort consisted of 144 patients with complete information on the proteins of interest (MPO, MMP-9, IL-6, and eNOS); of which, 139 were BAVM cases and the remaining 5 were control cases (epilepsy). Demographic and clinical characteristics shown in Table 1 were comparable to previous reports (5, 10).

4.2. MPO and MMP-9 co-localized in BAVM tissue

Figure 1A shows that BAVM tissue were positive for inflammatory markers: CD45, CD68, and MPO. Dual fluorescent staining shows that MPO co-localized with majority of MMP-9 signal. Some MMP-9 signal also co-

localized with endothelial marker CD31, as well as a macrophage marker (Figure 1B). As shown in Figure 1C, little MMP-9 signal overlapped with specific markers for neurons, astrocytes, and vascular smooth cells.

4.3. MMP-9 expression correlated with MPO, IL-6, but not with eNOS or CD31

Figure 2A shows that MMP-9 expression strongly correlated with MPO level ($R^2 = .76$, $n=144$, $P < .001$). MMP-9 expression was also associated with proinflammatory cytokine IL-6 expression (Figure 2B, $R^2 = .32$, $n=144$, $P < .001$). IL-6 expression, in turn, correlated with MPO level ($R^2 = .29$, $n=144$, $P < .001$). MMP-9 level was not highly correlated with eNOS expression (Figure 2C, $R^2 = .03$, $n=144$, $P = .05$). CD31 expression was determined as an alternative assay of endothelial cell mass. In a subset of cases available for western blot analysis ($n=76$), the mean values of CD31 and MMP-9 were 0.6 ± 0.4 OD units and 29 ± 33 ng/mg respectively, and did not correlate with each other ($R^2 = .004$, $n=76$, $P = .57$).

4.4. MMP-9 expression was associated with 125-kDa MMP-9 level

When complexed with neutrophil gelatinase-associated lipocalin (NGAL), MMP-9 is protected from degradation, thereby resulting in enhanced MMP-9 enzymatic activity (19). MMP levels contained in BAVM samples were assayed using substrate gel electrophoresis with gelatin as a substrate. Recombinant human MMP-9 and MMP-2 were used as standards to identify molecular weight sizes. As shown in Figure 3A, three major MMP bands were readily identified at apparent molecular masses of 125-kDa, 86-kDa, and 68-kDa, which corresponded respectively to the complex of MMP-9/neutrophil gelatinase-associated lipocalin (NGAL), MMP-9, MMP-2. As shown in Figure 3B, MMP-9 expression determined by ELISA was highly correlated with MMP-9/NGAL level ($R^2 = .70$, $y = 1.3 + .9x$, $P < .001$).

4.5. Assessment of confounding factors on MMP-9 expression

A series of univariate ANOVA tests revealed no effects of demographic (age, race-ethnicity, and gender) or clinical (venous drainage, eloquence, BAVM size and location) factors on MMP-9 and MPO levels.

Nine BAVM patients had a history of gamma knife therapy; 93 BAVM patients had pre-operative polyvinyl alcohol embolization. Seventy-eight patients had a history of "prior hemorrhage": 68 BAVM patients had initial presentation with hemorrhage and 10 patients had initial clinical presentation without hemorrhage, but had a new hemorrhage prior to tissue harvest. Using univariate ANCOVA, only MPO, prior embolization, and time from prior hemorrhage to tissue harvest displayed effect on MMP-9 expression ($P < .001$, $P = .023$, $P = .030$ respectively). Also, the time from prior hemorrhage to tissue harvest showed signs of negative correlation with MMP-9 expression ($R = -.265$, $P < .05$). An ANCOVA was then performed using significant predictors obtained from the univariate analyses. There was an interaction effect ($P = .02$) between prior embolization and MPO on MMP-9 expression.

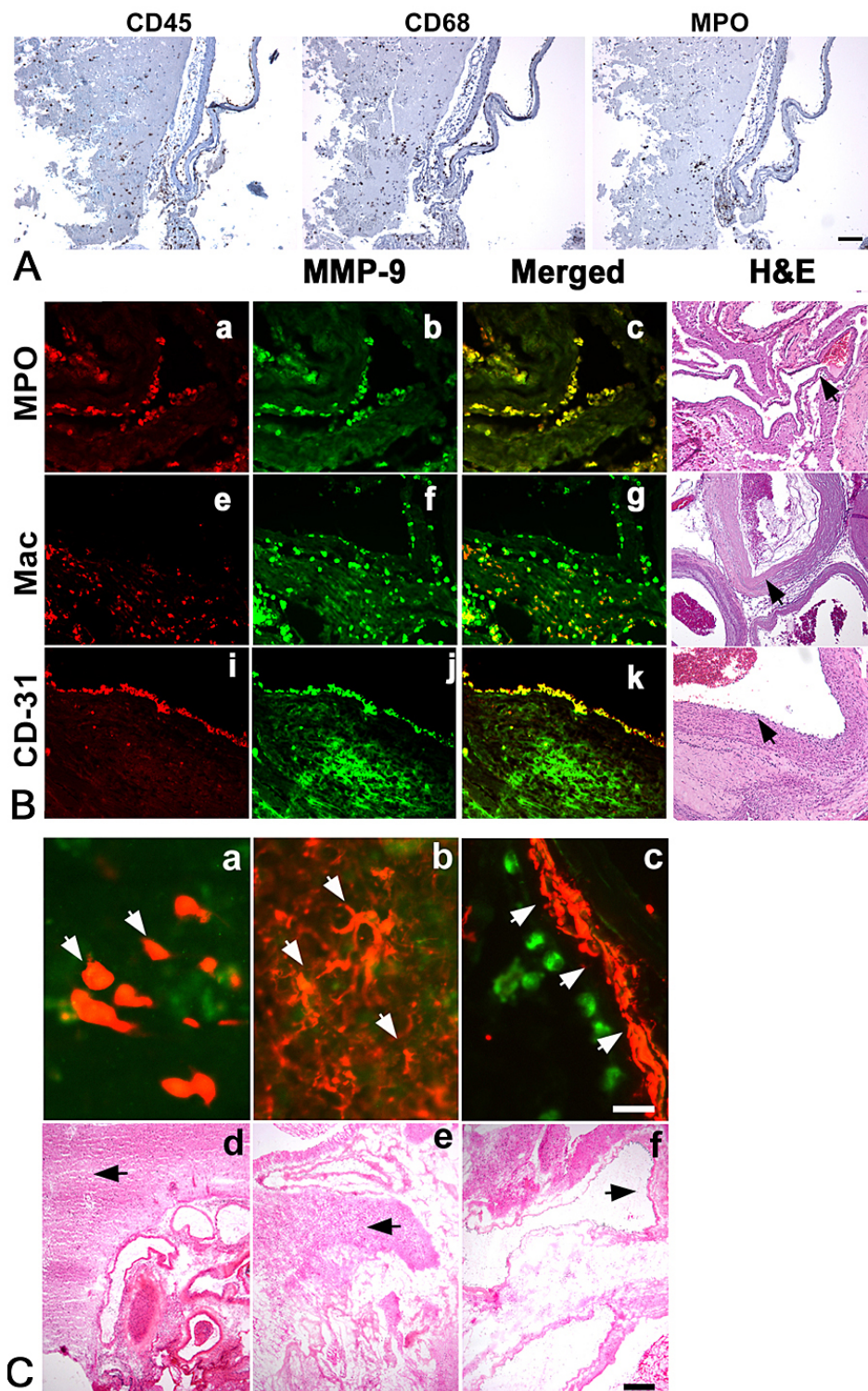


Figure 1. Immunohistochemical staining. A. BAVM tissues were stained with inflammatory cell markers: leukocyte (CD45), macrophage (CD68), and neutrophil (MPO). Size bar: 100 μ m. (B) For cellular localization of MMP-9, BAVM tissues were double-stained with MMP-9 antibody (b, f, j), and specific cell markers: neutrophil (MPO, a), macrophage (Mac, e), and endothelial cell (CD31, i). (C) MMP-9 (a, b, c) double staining was also performed on BAVM tissues with specific cell markers: neuron (NeuN, a), astrocyte (GFAP, b), and vascular smooth muscle (SMA, c). Corresponding adjacent sections were stained with H&E to show histology from where IHC image was taken (arrowheads in d, h, l, panels for B; arrowheads in d, e, f panels for C). Size bars for immunofluorescent and H&E staining were 20 μ m, 100 μ m respectively.

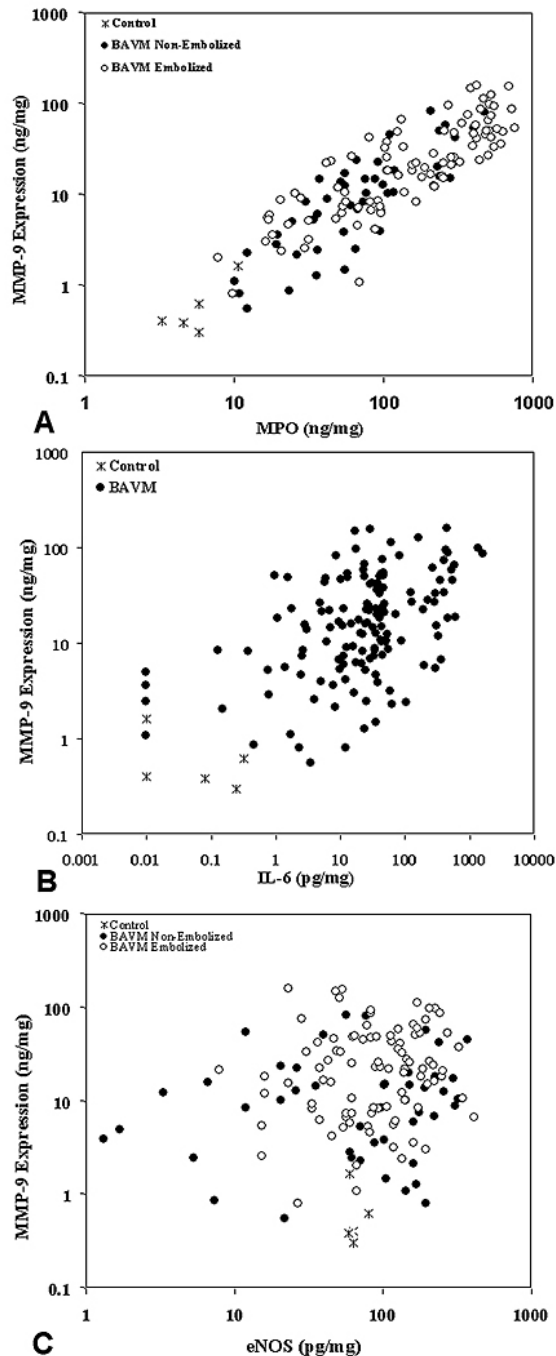


Figure 2. A. MMP-9 expression highly correlated with MPO levels. $R^2 = .76$, $y = -.77 + .94 \times x$, $n = 144$, $P < .001$. (B) Correlation of MMP-9 with proinflammatory cytokine IL-6. $R^2 = .32$, $y = .72 + .32 \times x$, $n = 144$, $P < .001$. (C) Correlation of MMP-9 with eNOS. $R^2 = .03$, $y = .70 + .22 \times x$, $n = 144$, $P = .05$

Because of potential complex interactions between the multiple confounding variables in a relatively small dataset, we performed exploratory analyses for the relative importance of hemorrhagic presentation by focusing on the

non-embolyzed group. Figure 4 shows the linear correlation of MPO and MMP-9 levels in non-embolyzed BAVM tissue, grouped by hemorrhagic presentation ($R^2 = .75$, $P < .001$) versus unruptured presentation ($R^2 = .81$, $P < .001$); both groups displayed a similar association between MPO and MMP-9. Adjusting for MPO (ANCOVA), the average MMP-9 level was higher ($P = .04$) in patients with hemorrhagic presentation ($n = 30$; mean \pm SEM $1.0 \pm .1$) compared to unruptured patients ($n = 16$; mean \pm SEM $.69 \pm .1$). The results were nearly identical when prior hemorrhage was used as the grouping variable instead of hemorrhagic presentation.

4.6. BAVM tissue displayed higher levels of inflammatory markers

Compared to control tissue ($n = 5$), BAVM tissue ($n = 139$) had higher average protein levels of MPO (193 ± 189 vs. 6 ± 3 , ng/mg, $P < .001$), MMP-9 (28 ± 32 vs. 0.7 ± 0.6 , ng/mg, $P < .001$), and IL-6 (102 ± 218 vs. 0.1 ± 0.1 , pg/mg, $P < .001$). Figure 5 shows relative expression data for BAVM tissue after normalizing to control values. MMP-9, MPO and IL-6 expression was one to two orders of magnitude higher in BAVM tissue than in control tissue. In contrast, eNOS expression was not significantly elevated in BAVM tissue as compared to controls (114 ± 87 vs. 65 ± 9 , pg/mg, $P = .09$).

5. DISCUSSION

In this study, we demonstrated that MMP-9 signal co-localized with inflammatory marker MPO in BAVM tissue, and MMP-9 expression correlated with MPO and IL-6 levels, but not eNOS or CD31 expression. These findings suggest, for the first time, that inflammatory cells represent an important and probably a major source of increased MMP-9 level in BAVM tissue.

Within the CNS, MMP-9 could be produced by various types of cells including endothelial cells, vascular smooth muscle cell, neurons, astrocytes, and inflammatory cells. Our immunostaining showed that the majority of MMP-9 signal co-localized with inflammatory cells. The staining also showed the colocalization of MMP-9 with CD31, indicating part of the expressed MMP-9 derives from endothelial cells. Further, neurons, astrocytes, and vascular smooth muscle cells showed very little MMP-9 signal, suggesting these cells are not major contributors in MMP-9 production.

While immunostaining demonstrates the location of MMP-9, it cannot reliably determine amounts of MMP-9 from various cell types. Our ELISA data show that there was a linear correlation between MMP-9 and MPO, indicating that leukocytes could be a major source of MMP-9 level in BAVM tissue. Our current study did not address which subsets of inflammatory cells play a major role in BAVM inflammation. Recruited macrophages and CNS intrinsic microglia have many similar characteristics, and can be difficult to differentiate from one another. The tight correlation between MMP-9 and MPO, the association of MMP-9 with the complex of MMP-9/NGAL, and also the co-localization of MMP-9 and MPO, suggest that

MMP-9 is associated with MPO in BAVM

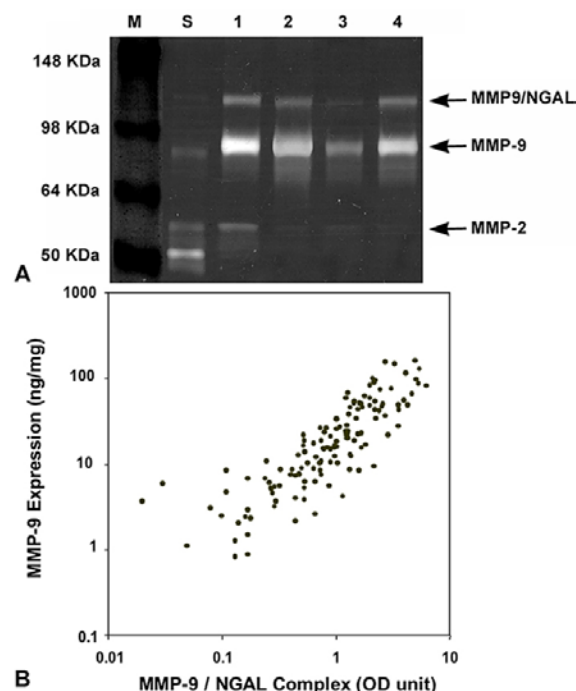


Figure 3. A. Representative gelatin zymogram showing MMP-9, neutrophil MMP-9/NGAL complex, and MMP-2 levels in BAVM tissue (lane 1 to lane 4). The molecular size markers (M) and human MMP standards (S) were run in parallel for comparison. B. Total MMP-9 expression correlated with the level of MMP-9/NGAL complex. LOG_{10} transformed value was used for the graph. $R^2 = .70$; $y = 1.3 + .9x$; $n = 133$, $P < .001$

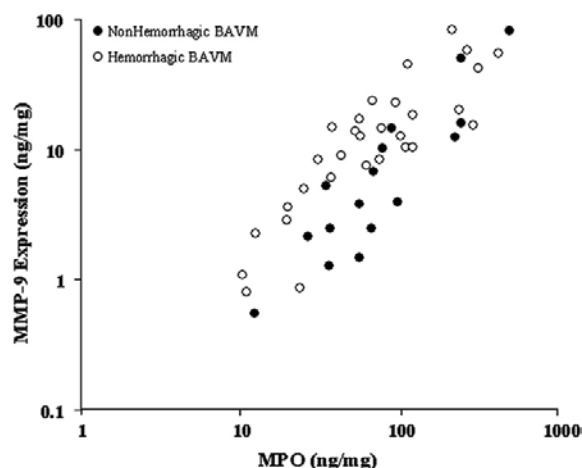


Figure 4. MMP-9 tightly correlated with MPO in non-embolized patients with and without hemorrhagic presentation. unraptured: $R^2 = .81$, $y = -1.6 + 1.3 \cdot x$, $n = 16$, $P < .001$; Hem: $R^2 = .75$, $y = -.81 + 1.0 \cdot x$, $n = 30$, $P < .001$

leukocytes highly contribute to the enhanced MMP-9 level in BAVM tissue.

Importantly, although pre-resection embolization and prior hemorrhage were associated with higher levels of MMP-9 and inflammatory markers, non-embolized and unruptured lesions displayed higher expression levels compared to control tissue. It appears that elevated expression of MMP-9 and inflammatory markers is an underlying characteristic of BAVM lesional phenotype and may indicate aspects of the underlying pathobiology of the disease. Because this is an observational study, however, our claims are appropriately modest and primarily limited to a previously underappreciated association of MMP-9, inflammation and leukocyte infiltration into BAVM tissue.

Patients who had pre-operative embolization had higher levels of MPO and MMP-9 in resected tissue than those who were non-embolized. However, both embolized and non-embolized cases showed a similarly strong correlation (Figure 2A). Therefore, the influence of pre-resection embolization is one of degree, and there is an underlying phenomenon that is operative, i.e., the effect we saw is not solely the result of acute inflammation from embolic material. There is a precedent for this observation in studies that have shown enhanced angiogenic activity in embolized cases, i.e., VEGF and HIF-1 α (20). In those studies, similar to our observations, embolization appeared to enhance an underlying angiogenic phenotype, rather than determine or explain it, i.e., there was a continuum of increased angiogenic factor expression for both embolized and non-embolized cases. Further, expression of MPO and MMP-9 is not likely to be an artifact of the trauma from surgical harvest because control brain tissue does not show similar elevations in MMP-9 and MPO levels.

Prior hemorrhage might be expected to transiently increase cytokine expression (21). Nonetheless, the relationships between MMP-9 and leukocytes were only partially explained by a history of prior hemorrhage because both ruptured and unruptured patients displayed increased marker expression. In the exploratory subset analysis in non-embolized patients, MMP-9 expression was higher in patients who presented with hemorrhage. However, un-ruptured patients also displayed a strong correlation between MPO and MMP-9 levels.

MMP-9 synthesis in leukocytes is stimulated by lipopolysaccharide, and cytokines (22-25). IL-6 has been shown to stimulate endothelial activation, vascular smooth muscle cell proliferation, and leukocyte recruitment. IL-6 is a key orchestrator of the inflammatory reaction, and may play an important role in bridging the inflammatory and angiogenic processes. Consistent with these notions, our data showed that MMP-9 expression correlated with IL-6 expression, which, in turn, correlated with MPO levels. It is likely that elevated IL-6 level within the BAVM nidus may stimulate release and activation of MMPs, which destabilize vascular wall, and further facilitate the transmigration of circulating leukocytes into the CNS (6). Furthermore, MMPs have been reported to facilitate the entry of systematic leukocytes into CNS, aggravating inflammatory reactions. Inhibitors of MMPs have been demonstrated to suppress the capacity of various leukocyte subsets to transmigrate into CNS (26-28).

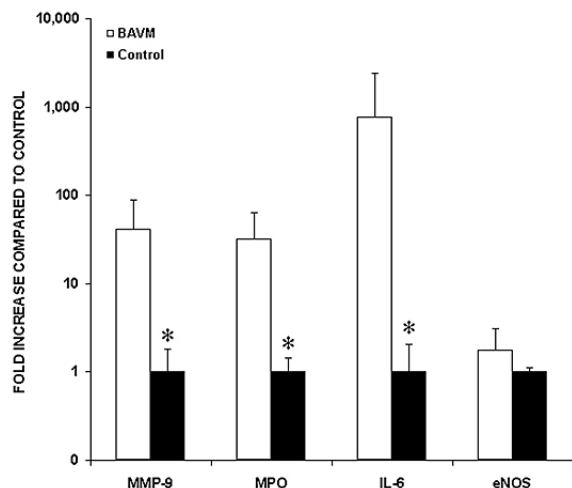


Figure 5. Levels of MMP-9, MPO, IL-6, eNOS in BAVM tissue and control tissue, as determined by ELISA. Compared to control brain tissues (n=5), BAVM tissue (n=139) has higher protein levels of MPO (193 ± 189 vs. 6 ± 3 , ng/mg, $P < .001$), MMP-9 (28 ± 32 vs. 0.7 ± 0.6 , ng/mg, $P < .001$), and IL-6 (102 ± 218 vs. 0.1 ± 0.1 , pg/mg, $P < .001$), but not eNOS (114 ± 87 vs. 65 ± 9 , pg/mg, $P = .09$). Data are graphed as % of control on log scale. *, $P < .001$

In our study, choice of control tissue for BAVM nidus has inherent limitations. We have described previously our use of brain taken from surgical epilepsy patients (10, 13), but others have proposed using superficial temporal arteries (29). Neither of these tissues is ideal, as neither contains intracranial blood vessels of the caliber found in BAVM nidus. It does appear, however, that the relative amount of vascular tissue is roughly the same in our control and BAVM samples, as evidenced by our eNOS measurements, similar to our previous report (18). Because the increase in MMP-9, MPO and IL-6 are so large (50 to 100 fold), it is unlikely that precise choice of normal comparator tissue would change the conclusions, as inflammation should be absent in both normal parenchyma and conductance vessels. Further, the primary purpose to include tissues from surgical epilepsy patients is to use as a quality control assay to rule out the possible effects of surgical trauma. Taken together with the association of polymorphisms in proinflammatory genes with BAVM hemorrhage (4, 5), our findings suggest inflammatory processes are involved in the pathophysiology of BAVM. Future experiments should focus on the contribution of baseline proteolytic activity and the propensity for BAVM rupture, and an explanation of the apparent continuum of different MPO and MMP-9 activities we observed. Also, further studies are needed to elucidate which subsets of leukocytes play a prominent role in BAVM inflammation and to determine the mechanism of their recruitment. Identification of inflammation as an operant process in lesional tissue can suggest lines of investigation to develop new treatment modalities.

6. ACKNOWLEDGEMENTS

Supported in part by PHS grants: P01 NS44155 (WLY, GYY, TH) and R01 NS27713 (WLY). The authors

thank Nancy J. Quinnine, RN, Christopher F. Dowd, MD; Van V. Halbach, MD; Randall T. Higashida, MD, S.C. Johnston, MD, PhD, and the other members of the UCSF BAVM Study Project (<http://avm.ucsf.edu>), Voltaire Gungab for assistance with manuscript preparation, and Mark Weinstein for immunocytochemistry assistance.

7. REFERENCES

1. Chyatte, D., G. Bruno, S. Desai & D. R. Todor: Inflammation and intracranial aneurysms. *Neurosurgery*, 45, 1137-46; discussion 1146-7. (1999)
2. Thompson, R. W.: Aneurysm treatments expand. *Nat Med*, 11, 1279-81 (2005)
3. Eliason, J. L., K. K. Hannawa, G. Ailawadi, I. Sinha, J. W. Ford, M. P. Deogracias, K. J. Roelofs, D. T. Woodrum, T. L. Ennis, P. K. Henke, J. C. Stanley, R. W. Thompson & G. R. Upchurch, Jr.: Neutrophil depletion inhibits experimental abdominal aortic aneurysm formation. *Circulation*, 112, 232-40 (2005)
4. Achrol, A. S., L. Pawlikowska, C. E. McCulloch, K. Y. T. Poon, C. Ha, J. G. Zaroff, S. C. Johnston, C. Lee, M. T. Lawton, S. Sidney, D. A. Marchuk, P.-Y. Kwok & W. L. Young: TNF α -238G>A promoter polymorphism is associated with increased risk of new hemorrhage in the natural course of patients with brain arteriovenous malformations (abstract). *Stroke*, 37, 638-639 (2006)
5. Pawlikowska, L., M. N. Tran, A. S. Achrol, C. E. McCulloch, C. Ha, D. L. Lind, T. Hashimoto, J. Zaroff, M. T. Lawton, D. A. Marchuk, P.-Y. Kwok & W. L. Young: Polymorphisms in genes involved in inflammatory and angiogenic pathways and the risk of hemorrhagic presentation of brain arteriovenous malformations. *Stroke*, 35, 2294-300 (2004)
6. Chen, Y., L. Pawlikowska, J. S. Yao, F. Shen, W. Zhai, A. S. Achrol, M. T. Lawton, P.-Y. Kwok, G.-Y. Yang & W. L. Young: Interleukin-6 involvement in brain arteriovenous malformations. *Ann Neurol*, 59, 72-80 (2006)
7. Nagase, H. & J. F. Woessner, Jr.: Matrix metalloproteinases. *J Biol Chem*, 274, 21491-4 (1999)
8. Rosenberg, G. A.: Matrix metalloproteinases in neuroinflammation. *Glia*, 39, 279-91 (2002)
9. Visse, R. & H. Nagase: Matrix metalloproteinases and tissue inhibitors of metalloproteinases: structure, function, and biochemistry. *Circ Res*, 92, 827-39 (2003)
10. Hashimoto, T., G. Wen, M. T. Lawton, N. J. Boudreau, A. W. Bollen, G. Y. Yang, N. M. Barbaro, R. T. Higashida, C. F. Dowd, V. V. Halbach & W. L. Young: Abnormal expression of matrix metalloproteinases and tissue inhibitors of metalloproteinases in brain arteriovenous malformations. *Stroke*, 34, 925-931 (2003)

11. Halim, A. X., V. Singh, S. C. Johnston, R. T. Higashida, C. F. Dowd, V. V. Halbach, M. T. Lawton, D. R. Gress, C. E. McCulloch & W. L. Young: Characteristics of brain arteriovenous malformations with coexisting aneurysms: a comparison of two referral centers. *Stroke*, 33, 675-9 (2002)
12. Joint Writing Group of the Technology Assessment Committee, A. S. o. I. a. T. N., Joint Section on Cerebrovascular Neurosurgery, a section of American Association of Neurological Surgeons and Congress of Neurological Surgeons, and Section of Stroke and the Section of Interventional Neurology of the American Academy of Neurology: Reporting terminology for brain arteriovenous malformation clinical and radiographic features for use in clinical trials. *Stroke*, 32, 1430-1442 (2001)
13. Hashimoto, T., Y. Wu, M. T. Lawton, G.-Y. Yang, N. M. Barbaro & W. L. Young: Co-expression of angiogenic factors in brain arteriovenous malformations. *Neurosurgery*, 56, 1058-65; discussion 1058-65 (2005)
14. Hashimoto, T., M. T. Lawton, G. Wen, G.-Y. Yang, T. Chaly T Jr, C. L. Stewart, H. K. Dressman, N. M. Barbaro, D. A. Marchuk & W. L. Young: Gene microarray analysis of human brain arteriovenous malformations. *Neurosurgery*, 54, 410-425 (2004)
15. Klebanoff, S. J.: Myeloperoxidase: friend and foe. *J Leukoc Biol*, 77, 598-625 (2005)
16. Cooke, J. P. & V. J. Dzau: Nitric oxide synthase: role in the genesis of vascular disease. *Annu Rev Med*, 48, 489-509 (1997)
17. Hashimoto, T., G.-Y. Yang & W. L. Young: Abnormal expression of MMP9 and TIMPs in brain arteriovenous malformations (abstract). *Anesthesiology*, 96, A721 (2002)
18. Hashimoto, T., C. W. Emala, S. Joshi, R. Mesa-Tejada, C. M. Quick, L. Feng, A. Libow, D. A. Marchuk & W. L. Young: Abnormal pattern of Tie-2 and vascular endothelial growth factor receptor expression in human cerebral arteriovenous malformations. *Neurosurgery*, 47, 910-8; discussion 918-9 (2000)
19. Yan, L., N. Borregaard, L. Kjeldsen & M. A. Moses: The high molecular weight urinary matrix metalloproteinase (MMP) activity is a complex of gelatinase B/MMP-9 and neutrophil gelatinase-associated lipocalin (NGAL). Modulation of MMP-9 activity by NGAL. *J Biol Chem*, 276, 37258-65 (2001)
20. Sure, U., E. Battenberg, A. Dempfle, W. Tirakotai, S. Bien & H. Bertalanffy: Hypoxia-inducible factor and vascular endothelial growth factor are expressed more frequently in embolized than in nonembolized cerebral arteriovenous malformations. *Neurosurgery*, 55, 663-9; discussion 669-70 (2004)
21. Power, C., S. Henry, M. R. Del Bigio, P. H. Larsen, D. Corbett, Y. Imai, V. W. Yong & J. Peeling: Intracerebral hemorrhage induces macrophage activation and matrix metalloproteinases. *Ann Neurol*, 53, 731-42 (2003)
22. Ferroni, P., S. Basili, F. Martini, C. M. Cardarello, F. Ceci, M. Di Franco, G. Bertazzoni, P. P. Gazzaniga & C. Alessandri: Serum metalloproteinase 9 levels in patients with coronary artery disease: a novel marker of inflammation. *J Investig Med*, 51, 295-300 (2003)
23. Dasu, M. R., R. E. Barrow, M. Spies & D. N. Herndon: Matrix metalloproteinase expression in cytokine stimulated human dermal fibroblasts. *Burns*, 29, 527-31 (2003)
24. Wize, J., I. Sopata, A. Smerdel & S. Maslinski: Ligation of selectin L and integrin CD11b/CD18 (Mac-1) induces release of gelatinase B (MMP-9) from human neutrophils. *Inflamm Res*, 47, 325-7 (1998)
25. Pugin, J., M. C. Widmer, S. Kossodo, C. M. Liang, H. L. n. Preas & A. F. Suffredini: Human neutrophils secrete gelatinase B *in vitro* and *in vivo* in response to endotoxin and proinflammatory mediators. *Am J Respir Cell Mol Biol*, 20, 458-64 (1999)
26. Uhm, J. H., N. P. Dooley, O. Stuve, G. S. Francis, P. Duquette, J. P. Antel & V. W. Yong: Migratory behavior of lymphocytes isolated from multiple sclerosis patients: effects of interferon beta-1b therapy. *Ann Neurol*, 46, 319-24 (1999)
27. Xia, M., D. Leppert, S. L. Hauser, S. P. Sreedharan, P. J. Nelson, A. M. Krensky & E. J. Goetzl: Stimulus specificity of matrix metalloproteinase dependence of human T cell migration through a model basement membrane. *J Immunol*, 156, 160-7 (1996)
28. Graesser, D., S. Mahooti & J. A. Madri: Distinct roles for matrix metalloproteinase-2 and alpha4 integrin in autoimmune T cell extravasation and residency in brain parenchyma during experimental autoimmune encephalomyelitis. *J Neuroimmunol*, 109, 121-31 (2000)
29. Shenkar, R., J. P. Elliott, K. Diener, J. Gault, L. J. Hu, R. J. Cohrs, T. Phang, L. Hunter, R. E. Breeze & I. A. Awad: Differential gene expression in human cerebrovascular malformations. *Neurosurgery*, 52, 465-78 (2003)

Key Words: Inflammation, Matrix metalloprotease-9, Myeloperoxidase, Vascular Malformations, Brain

Send correspondence to: Dr William L. Young, M.D. UCSF, 1001 Potrero Avenue, Rm. 3C-38, San Francisco, CA 94110, Tel: 415-206-8906, Fax: 415-206-8907, Email: ccr@anesthesia.ucsf.edu

<http://www.bioscience.org/current/vol11.htm>