

# Totally Endoscopic Multivessel Coronary Artery Bypass Surgery Using the da Vinci Surgical System: A Feasibility Study on Cadaveric Models

(#2003-12303 . . . August 8, 2003)

**Hubert Stein, BSc, BME,<sup>1</sup>** Romuald Cichon, MD,<sup>3</sup> Gerhard Wimmer-Greinecker, MD, PhD,<sup>4</sup> Michael Ikeda, MSc, ME,<sup>1</sup> Douglas Hutchison,<sup>1</sup> Volkmar Falk, MD, PhD<sup>2</sup>

<sup>1</sup>Department of Clinical Development Engineering, Intuitive Surgical Inc, Sunnyvale, California, USA;

<sup>2</sup>Department of Cardiac Surgery, Heartcenter Leipzig, University of Leipzig, Leipzig, Germany;

<sup>3</sup>Department of Cardiac Surgery, Heartcenter Dresden, University of Dresden, Dresden, Germany;

<sup>4</sup>Department of Thoracic and Cardiovascular Surgery, University Hospital, University of Frankfurt/Main, Frankfurt/Main, Germany



Mr. Stein



## ABSTRACT

**Background:** The aim of the study was to develop a totally endoscopic coronary artery bypass procedure for the treatment of multivessel disease (MVTECAB).

**Methods:** Procedure development was conducted on 6 human cadavers with the da Vinci Surgical System. For aortic clamping, a transthoracic aortic clamp was applied. The proximal anastomoses of vein grafts were created transthoracically with the Corlink automated anastomosis device. The target vessels on the heart were exposed with a modified endoscopically applicable Starfish vacuum device. In 1 cadaver, the endo-sling and endoscopic fan retractors were studied for exposure support.

**Results:** Harvesting of bilateral internal thoracic arteries was easily accomplished. Aortic clamping was easier from the right side. In the left-side approach, the proximal anastomoses were completed without leakage in all 3 cadavers. One incorrect deployment occurred, and the deployment needed to be redone. In the right-side approach, 1 proximal anastomosis was performed without leakage, and another needed to be repaired for incorrect deployment. The fan retractors either covered too much of the targeted area of the heart surface or did not provide good manipulation capabilities. The endo-sling enabled atraumatic exposure of the target vessels. The modified Starfish performed sufficiently for exposing target vessels. Problems were found with epicardial fat clogging the Starfish suction chamber and with bending of the suction tube neck, both of which resulted in a loss of tissue contact. Two of the cadavers approached from the left side were completely revascularized

with 3 grafts, and 4 anastomoses were performed on the third cadaver. Triple-vessel revascularization was performed in the cadavers approached from the right side.

**Conclusion:** This study demonstrates the feasibility of performing an MVTECAB on the arrested heart with the da Vinci Surgical System. Further procedure development is necessary to optimize the synergistic effects of the technologies used and to introduce this operation into clinical practice.

## INTRODUCTION

With the introduction of the da Vinci Surgical System (Intuitive Surgical, Sunnyvale, CA, USA) in cardiac surgery in 1998, various endoscopic cardiac procedures have been successfully performed. The da Vinci Surgical System is currently used for mitral valve repairs, atrial septal defect repairs, and totally endoscopic coronary artery bypass (TECAB) grafting, both on and off pump. Although the feasibility of single-vessel, closed-chest bypass grafting of the left internal thoracic artery (LITA) to the left anterior descending artery (LAD) has been demonstrated by a number of groups [Kappert 2000b, Mohr 2001, Dogan 2002], only a few cases of endoscopic double-vessel bypass grafting have been reported [Kappert 2000a, Dogan 2001, Dogan 2002]. The aim of this study was to develop a TECAB procedure for the treatment of multivessel disease (MVTECAB) by using multiple arterial and venous grafts in a human cadaver model.

## MATERIALS AND METHODS

The da Vinci Surgical System consists of a surgeon's console, a patient-side cart, instruments, and 3-dimensional (3-D) image-processing equipment. The surgeon operates while seated at the surgeon's console and viewing a 3-D image of the surgical field. The technology seamlessly translates the surgeon's movements into precise, real-time movements of different EndoWrist surgical instruments (Intuitive Surgical) inside the patient. A patient-side cart provides 2 robotic instrument arms and 1 camera arm that execute the surgeon's motions. This system provides the surgeon with the intuitive

*Received June 25, 2003; received in revised form July 19, 2003; accepted August 8, 2003.*

*Address correspondence and reprint requests to: Hubert Stein, Intuitive Surgical Inc, Department of Clinical Development Engineering, 950 Kifer Rd, Sunnyvale, CA 94086, USA; 1-408-523-2104; fax: 1-408-523-1390 (e-mail: [hubert.stein@intusurg.com](mailto:hubert.stein@intusurg.com)).*

Table 1. Port Locations and Cadaver Access\*

Cadaver No.	Approach	Port Locations					
		da Vinci Surgical System Instruments	Fan Retractors	Endo-Sling	Modified Endo-Starfish	Corlink AAD	Aortic Clamp
1	Left	3/5/7 ICS	N/A	N/A	Subxyphoid	Fifth ICS (CA)	Third ICS, left chest
2	Left	3/5/7 ICS	Fifth ICS, right chest	N/A	Fifth ICS, right chest	Fifth ICS (CA)	Third ICS, left chest
3	Left	3/5/6 ICS	N/A	N/A	Subxyphoid	Third ICS (right IA)	Third ICS, right chest
4	Right	3/5/7 ICS	N/A	N/A	Subxyphoid	Fourth ICS, right chest medial	Third ICS, right chest
5	Right	3/5/7 ICS	N/A	N/A	Fifth ICS, left chest	Fourth ICS, right chest medial	Third ICS, right chest
6	Left	3/5/7 ICS	Fifth ICS, right chest	Second ICS, left chest (out); third ICS, left chest (in)	N/A	N/A	N/A

\*AAD indicates automated anastomosis device; ICS, intercostal space; N/A, not applied; CA, camera arm; IA, instrument arm.

control, range of motion, fine tissue-manipulation capability, and 3-D visualization that are characteristic of open surgery, while simultaneously allowing the surgeon to work through the small ports of totally endoscopic surgery. A description of the system is provided in detail elsewhere [Falk 2000].

Six human cadavers (2 female and 4 male with no prior cardiac surgery) were used (Table 1). A TECAB operation with a minimum of 3 grafts was performed in 5 of the cadavers. One cadaver was used only for studying exposure devices. Both internal thoracic arteries were harvested endoscopically as previously described [Cichon 2000]. Saphenous veins were also used and harvested in a standard fashion. The aim of the study was to simulate the entire procedure, including all of the necessary steps that are crucial for a totally endoscopic approach.

### Robotic Surgical Instruments

For the left-side approach (Table 1), the instrument ports were placed in the third intercostal space (ICS) for the right instrument and the sixth, respectively seventh ICS for the left instrument arm. The endoscope was placed in the fifth ICS 3 cm medial of the anterior axillary line. The ports on 2 cadavers were placed in the right chest to evaluate the differences in access and performance. Instrument arms were placed in the third and seventh ICS, and the camera arm was introduced in the fifth ICS. All ports were placed 3 cm medial of the anterior axillary line (Table 1).

### Aortic Clamping

For aortic clamping, a transthoracic aortic clamp (Scanlan International, St. Paul, MN, USA) was used. The endoclamp was placed through a stab incision in the third ICS between the anterior and the midaxillary lines. In one cadaver approached from the left side and in the cadavers approached from the right side, the clamp was introduced through the right chest. After the pericardium was opened, one tine of the clamp was passed through the transverse sinus, and the aorta

was clamped (Figure 1). The clamp was introduced through the left chest in 2 cadavers. In these 2 cadavers, both the pulmonary artery and the aorta were clamped.

### Exposure of Target Vessels

The target vessels were exposed with a modified vacuum-suction device. A prototype was built by placing the suction chamber of a Starfish (Medtronic, Minneapolis, MN, USA) device on a hollow, stainless steel tube 30 cm in

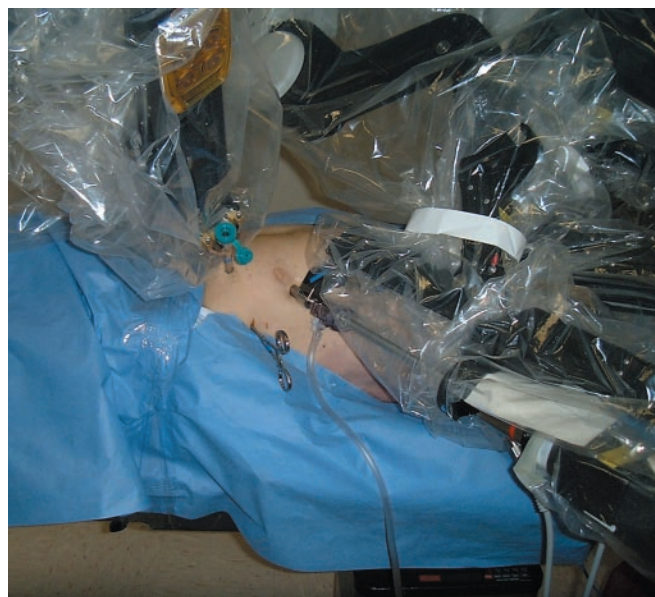

Figure 1. The da Vinci Surgical System port setup for right-side approach on cadaver no. 4 with the instrument arms in the third and seventh intercostal spaces (ICS), the camera arm in the fifth ICS, the ports 3 cm medial of the anterior axillary line, and the cross-clamp placed in the third ICS.

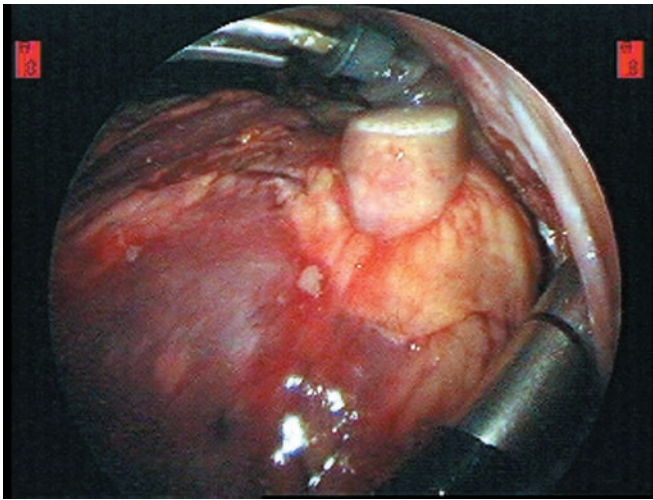


Figure 2. The modified Starfish attached to the apex and pushed superiorly to expose the posterior wall (posterior descending artery) in cadaver no. 3.

length. The 3 fingers of the Starfish device were collapsed and preloaded in reverse into a 15-mm sealed trocar. Once introduced through the port incision, the Starfish suction chamber unfolded in the chest cavity. The device was then placed on either the apex or the lateral wall of the heart. After the application of a vacuum of 400 mm Hg, the heart was manipulated inside the chest cavity to expose the target areas in front of the working ports. The device was fixed outside the body by a mechanical holding arm attached to the operating table rail. Figure 2 shows the modified Starfish attached to the apex and pushed superiorly to expose the posterior wall in cadaver no. 3. The 15-mm sealed trocar was initially placed subxyphoidally to the left of the sternum. If the targeted anastomosis site could not be reached, the port was moved to the right or left chest and into the fifth ICS 3 cm anterior of the anterior axillary line.

### **Endo-Sling**

As an alternative method for exposure, an “endo-sling” was used. A cotton compress  $4 \times 4$  cm was cut in half, and 2-0 sutures were attached at both ends. The endo-sling was then inserted through the right instrument port (third ICS, left chest) and slipped underneath the heart. The attached unarmed sutures were passed through the body wall (second ICS, left chest medial) by the use of an Endoclose device (US Surgical, Norwalk, CT, USA), which combines a cannula with a crochet hook and does not require an additional incision, thus avoiding loss of carbon dioxide. After the endo-sling was positioned, manipulation of the empty heart was easily accomplished from outside the chest by pulling on the attached sutures and manipulating the heart with the robotic instruments inside the thoracic cavity.

### **Fan Retractors**

The usefulness of endoscopic retractors was evaluated by testing a 10-mm fan retractor with an articulating fan and a

32 cm working length (Karl Storz, Tuttlingen, Germany), as well as a smaller, unarticulated 5-mm MICTEC fan retractor (Dufner Instrumente GmbH, Tuttlingen, Germany) with only 3 fan fingers and a working length of 34 cm. The fan retractors were placed through an additional 10-mm port in the fifth ICS (anterior axillary line in the right chest).

### **Proximal and Distal Anastomoses**

For the proximal anastomosis of vein grafts, the Corlink automated anastomosis device (AAD) (CardioVations, Somerville, NJ, USA) was used transthoracically. The AAD creates a sutureless proximal anastomosis, and details of the application of the AAD are described elsewhere [Calafiore 2001]. Because the AAD works only on the pressurized aorta, catheterization of the ascending aorta through the right carotid artery was performed. After balloon blocking, saline solution was infused into the ascending aorta to provide sufficient intraluminal counterpressure. For the application to be correct, the AAD needs to be deployed perpendicular to the ascending aorta. In the left-side approach, the AAD was inserted through the camera port in the fifth ICS, and the camera was moved to the third ICS for the duration of the deployment (Figure 3). Alternatively, the right robotic instrument arm was removed from its port, and the AAD was inserted there to provide a straight-shot angle. In the right-side approach, the AAD was introduced through a medial port in the fourth ICS 4 cm lateral to the sternum.

All distal anastomoses were done with a polypropylene 7-0 suture (Prolene; Ethicon, Somerville, NJ, USA) and a double-armed BV-1 Visiblack needle 7 cm in length (Johnson & Johnson, Brussels, Belgium).

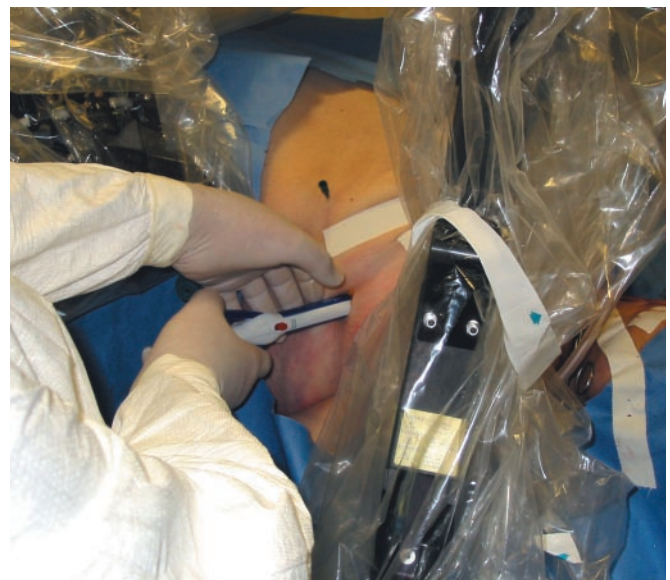


Figure 3. A perpendicular angle for the correct application and optimal deployment of the automated anastomosis device (AAD) was provided by removing the camera arm from its port and inserting the AAD instead (cadaver nos. 1 and 2). The camera arm was moved to the third intercostal space.



Table 2. Results of Multivessel Revascularization\*

Cadaver No.	Approach	Port Locations			LITA Harvest	RITA Harvest	Aortic Clamping	Proximal Anastomosis + Aorta Exposure	Target Vessel Exposure and Distal Anastomosis				
		Modified Endo-Starfish	Corlink AAD	Aortic Clamp					LAD	RCA	PDA/RPLA	LCx	OM
1	Left	Subxyphoid, left	Fifth ICS, left chest	Third ICS, left chest	++	+	–	++	++ B	–	+ B	+ B	N/A
2	Left	Fifth ICS, right chest	Fifth ICS, left chest	Third ICS, left chest	++	+	–	++	Distal ++ B	Distal + B	+ B	–	–
3	Left	Subxyphoid, left	Third ICS, left chest	Third ICS, right chest	++	+	++	+	++ B	Distal + B	++ B	N/A	+ B
4†	Right	Subxyphoid, left	Fourth ICS, right chest medial	Third ICS, right chest	+	++	++	+	Distal + B	Distal ++	+ B	++ B	–
5	Right	Fifth ICS, left chest	Fourth ICS, right chest medial	Third ICS, right chest	+	++	++	+	++ B	–	+ B	N/A	+ B
6	Left	N/A	N/A	N/A	N/A	N/A	N/A	N/A	N/A	++	++	+	+

\*Procedure and anastomosis results ideal (++), OK (+), or not ideal (–); B indicates anastomosis performed. AAD indicates automated anastomotic device; LITA, left internal thoracic artery; RITA, right internal thoracic artery; LAD, left anterior descending artery; RCA, right coronary artery; PDA, posterior descending artery; RPLA, right posterior lateral artery; LCx, left circumflex artery; OM, obtuse marginal artery; ICS, intercostal space; N/A, not applied.

†T graft.

## RESULTS

Harvesting the LITA and the right ITA (RITA) is already a standardized part of the current TECAB procedure with the da Vinci Surgical System. No problems were encountered. Access to the LITA is slightly better than to the RITA through a left-side approach. Conversely, access to the RITA is enhanced through the right-side approach. In cadaver no. 4, a T graft was constructed by anastomosing the proximal end of the free RITA to the side of the LITA to allow complete arterial revascularization. Two bulldog forceps were placed on the in situ LITA. Harvesting of the LITA was completed with the RITA T graft attached (Table 2).

### Aortic Clamp

Although aortic clamping is easier through a right-side approach, it was also possible to clamp the aorta from the left chest without interfering with the instrument port setup.

### Proximal Endoscopic Anastomosis with the Corlink AAD

For the left-side approach, the ascending aorta was exposed in all 3 cadavers without problems. In the first cadaver, the 4-mm AAD caused an incorrect deployment. In the second attempt, the proximal anastomosis was done in approximately 1 minute with a 2-mm AAD. This time included punching the hole and deploying the AAD. Loading the vein to the delivery system took approximately 5 minutes. The second cadaver was approached the same way. Deployment of the 2-mm AAD took 2 minutes without any leakage occurring. In the third cadaver, 2 proximal anastomoses (2-mm and 4-mm AAD) were performed next to each other on the ascending aorta in 8 minutes without any leakage. In the first cadaver approached from the right side, a proximal anastomosis with a 4-mm AAD was created in 7 minutes, including

vein loading, hole punching, and AAD deployment. Although the AAD appeared properly anchored in the ascending aorta, a small leak required repair with a 7-0 suture. In the second cadaver, a 2-mm AAD was deployed in 2 minutes without leakage (Table 2).

### Exposure of Target Vessels and Distal Anastomoses

**Left-Side Approach.** The posterior descending artery (PDA), the left circumflex artery (LCx), the right posterior lateral artery (RPLA), and the LAD were easily exposed in cadaver no. 1. It was not possible to obtain optimal exposure of the proximal and distal right coronary artery (RCA). A vein graft was placed on the PDA, a LITA was anastomosed to the LCx, and a RITA was anastomosed to the LAD. Anastomosis times were between 12 minutes and 23 minutes (Figure 4).

In cadaver no. 2, the distal LAD was exposed without any external manipulation of the heart. The modified Starfish was placed on the right posterior wall, and pushing laterally to the left gave sufficient exposure of the distal RCA and PDA for grafting (the RITA to the RCA, the LITA to the LAD, and a vein to the PDA). Anastomotic times were between 13 minutes and 20 minutes. The LCx and the obtuse marginal artery (OM) could not be reached from the right chest in this cadaver.

In cadaver no. 3, the distal RCA and PDA were easily exposed on the posterior wall by pushing the modified Starfish superiorly. The RITA was anastomosed to the RCA, and 1 vein graft was placed on the PDA. The LITA was grafted to the LAD, which was exposed without any external manipulation of the heart. The first proximal OM was grafted with a vein (Figure 5). Anastomotic times were 18 to 27 minutes.

**Right-side approach.** Exposure of the LCx, the PDA, and the distal LAD was obtained in cadaver no. 4 by rotating the heart around the long axis. A vein graft was anastomosed to the LCx, the LITA was anastomosed to the LAD, and the

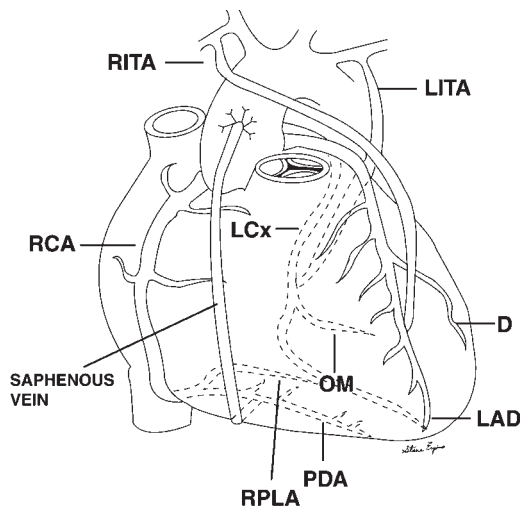


Figure 4. Revascularization in cadaver no. 1. Anastomoses of the saphenous vein to the posterior descending artery (PDA), the right internal thoracic artery (RITA) to the left anterior descending artery (LAD), and the left ITA (LITA) to the left circumflex artery (LCx). RCA indicates right coronary artery; D, diagonal artery; OM, obtuse marginal artery; RPLA, right posterior lateral artery.

T-grafted RITA was anastomosed to the PDA. All distal anastomoses required between 12 minutes and 20 minutes to complete (Figure 6).

In cadaver no. 5, the heart was pushed medially toward the mediastinum. The LAD, an OM, and the distal RPLA (but not the RCA) were exposed. Revascularization occurred as follows:

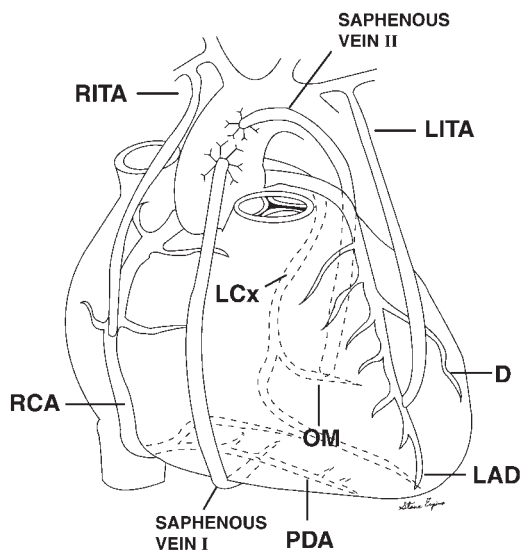


Figure 5. Revascularization in cadaver no. 3. Anastomoses of the right internal thoracic artery (RITA) to the right coronary artery (RCA), saphenous vein I to the posterior descending artery (PDA), the left ITA (LITA) to the left anterior descending artery (LAD), and saphenous vein II to the obtuse marginal artery (OM). D indicates diagonal artery; LCx, left circumflex artery.

the RITA to the LAD, the LITA to the OM, and a vein to the RPLA, with anastomotic times of 15 to 22 minutes.

### Fan Retractors

In cadaver nos. 2 and 6, the fan branches (10-mm Storz fan retractor) covered too much of the targeted surface area of the heart, and the articulation angle was too far away from the fan end points, making manipulation awkward. From the right chest, the fan retractor was helpful only for exposing the left lateral wall of the heart (diagonals, OM). The 5-mm MICTEC retractor did not provide enough strength/push to manipulate the heart, and the small cross-sectional area of the retractor fingers caused laceration of the epicardium.

### Endo-Sling

With the endo-sling, atraumatic exposure of the RCA, the proximal left coronary artery, the first and second OM branches, and the PDA was possible without exerting a strong pulling force. The targeted coronary vessels could be exposed securely to perform an anastomosis.

## DISCUSSION

This study of performing a MVTECAB with the da Vinci Surgical System shows promising first results. Bilateral ITA takedown was easily performed from both sides of every cadaver, with the LITA more easily harvested from the left side and the RITA more easily harvested from the right side.

The transthoracic aortic cross-clamp was placed fairly easily from the right chest. For cross-clamping from the left chest, the jaws were too short to cover the entire cross section

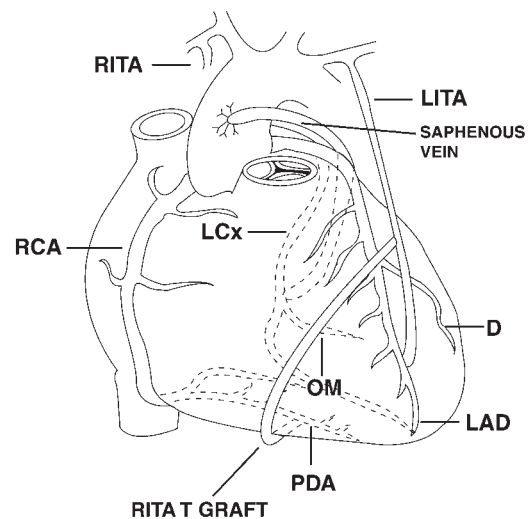


Figure 6. Revascularization in cadaver no. 4. Anastomoses of the saphenous vein to the left circumflex artery (LCx), the left internal thoracic artery (LITA) to the left anterior descending artery (LAD), and the T-grafted right ITA (RITA) to the posterior descending artery (PDA). Exposure of the distal right coronary artery (RCA) was good, but no graft was performed. D indicates diagonal artery; OM, obtuse marginal artery.

of both the aorta and the pulmonary artery. A redesign of the cross-clamp with longer jaws to cross over both vessels simultaneously may be necessary.

Insufficient intraluminal counterpressure in the aorta was responsible for the incorrect deployment of the AAD in cadaver no. 1. The visible leakage between the saphenous vein and the AAD in cadaver no. 4 was due to size mismatch between the graft and the device. Proper estimation of saphenous vein size is therefore absolutely necessary. For endoscopic applications, the shaft of the AAD needs to be lengthened to reach the ascending aorta in obese patients. The insertion limit for the AAD was reached on cadavers approached from the left side. The cross section of the Corlink AAD deployment handle is not perfectly round, leading to the loss of carbon dioxide when the device is introduced through a sealed cannula. The device therefore needs to be redesigned to fit through a standard 10- or 12-mm sealed cannula. Uncontrollable bleeding in the case of leakage may be prevented by placing a purse-string suture on the ascending aorta before the AAD is applied. Prior to the MVTECAB cadaver study, we had evaluated the Symmetry Bypass System Aortic Connector (St. Jude Medical, St. Paul, MN, USA), which works similarly to the Corlink AAD. Because this device in its current design lacks an aortic seal after punching, it is not applicable in an endoscopic environment.

The modified Starfish performed extremely well and proved sufficient for exposing most target vessels. Heart tissue handling was gentle, and stabilization was safe and secure for the duration of the anastomosis. Target-vessel exposure worked best from the subxyphoid port location (Table 2). In 2 cadavers (nos. 1 and 5), the RCA was not reachable, and the OM could not be exposed in cadaver nos. 2 and 4. These problems were due to a suboptimal introduction angle for the device. A design change with a ball-type joint incorporated into the Starfish neck would add more flexibility for reaching the RCA and OM and improving the exposure of the lateral wall from the subxyphoid port location. Problems were found with large epicardial fat pads clogging the suction chamber, thus preventing a perfectly sealed fit and causing the heart to slip. Bending the modified Starfish at a 90° angle (which occurs during the exposure of the lateral walls) results in a flattening of the suction tube orifice, which occasionally may result in loss of vacuum and thus tissue contact. A ball joint would improve this problem as well.

The fan retractors used were not sufficient for exposing the targeted heart areas and caused too much trauma during the manipulation of the epicardium. These fan retractors therefore cannot be recommended.

The endo-sling manipulation, on the other hand, was rather atraumatic. Further investigation of this method may eventually facilitate a totally endoscopic procedure. As for now, the modified Starfish seems more easily handled than the 2 unarmed sutures of the endo-sling.

Handling sutures in a totally endoscopic cardiac environment can still be a challenging task. Two recently developed technologies may provide a promising alternative for the creation of distal anastomoses without suturing. The nitinol U-Clip device (Coalescent Surgical, Sunnyvale, CA, USA) facili-

tates an anastomosis by eliminating suture management and knot tying. The device consists of a self-closing, shape-memory, nitinol clip attached to a curved/tapered suture needle. Pressure applied to a release mechanism separates the components and releases the clip, allowing it to return to its preferred closed-loop configuration and to hold tissue together similar to an interrupted suture. The device has been successfully applied in minimally invasive direct coronary artery bypass procedures [Niinami 2001] and some totally endoscopic single-vessel beating heart procedures [Cichon 2002]. The Ventrica MVP System (Magnetic Vascular Positioner; Ventrica, Fremont, CA, USA) creates a sutureless anastomosis with magnetic couplers to form an instantaneous self-aligning, self-sealing connection between the bypass graft and the coronary artery. Encouraging predischARGE angiographic patency rates have recently been reported [Klima 2002]. We are currently investigating a totally endoscopic approach for deploying the MVP System with the da Vinci Surgical System. First results look promising for totally endoscopic beating heart as well as totally endoscopic stopped-heart multivessel procedures (V.F. et al, unpublished data, 2002). It appears that the MVP system will extremely shorten the time necessary to create an anastomosis and will make the anastomosis procedure less demanding.

Sequential arterial bypasses of the LITA to the LAD and to the first diagonal branch as well as bilateral ITA takedown have been described for a series of 8 patients with double-vessel revascularization, and the operations were performed successfully with excellent functional results [Dogan 2002]. Expanding the potential benefits of a closed-chest procedure to the larger group of patients with multivessel disease requires further procedure development.

The various technologies used in this study have to be combined to allow an MVTECAB procedure. Some design iterations for the exposure and anastomotic devices are required to provide a reliable and safe platform for this approach. In addition, an assisting fourth robotic instrument arm may be helpful for retraction, countertraction, suture handling, and ITA holding. Ongoing clinical trials demonstrate the potential merits of this "autoassist" concept. In summary, endoscopic multivessel coronary artery bypass grafting is possible, and a cautious stepwise approach may allow the transfer of the experimental results into clinical practice.

## REFERENCES

- Calafiore AM, Bar-El Y, Vitolla G, et al. 2001. Early clinical experience with a new sutureless anastomotic device for proximal anastomosis of the saphenous vein to the aorta. *J Thorac Cardiovasc Surg* 121:854-8.
- Cichon R, Kappert U, Schneider J, et al. 2000. Robotic-enhanced arterial revascularization for multivessel coronary artery disease. *Ann Thorac Surg* 70:1060-2.
- Cichon R, Kapsalis A, Schneider J, et al. Totally endoscopic coronary artery anastomosis on a beating heart with application of the Coalescent Sutured-Clips™. *Pol Przegl Chir*. In press.
- Dogan S, Aybeck T, Andreßen E, et al. 2002. Total endoscopic coronary artery bypass grafting on cardiopulmonary bypass with robotically enhanced telemanipulation: report of forty-five cases. *J Thorac Cardiovasc Surg* 123:1125-31.

Dogan S, Aybeck T, Westphal K, Mierdl S, Moritz A, Wimmer-Greinecker G. 2001. Computer-enhanced totally endoscopic sequential arterial coronary bypass. *Ann Thorac Surg* 72:610-1.

Falk V, Diegeler A, Walther T, Autschbach R, Mohr FW. 2000. Developments in robotic cardiac surgery. *Curr Opin Cardiol* 15:378-87.

Kappert U, Cichon R, Schneider J, Schramm I, Schueler S. 2000. Closed chest bilateral mammary artery grafting in double-vessel coronary artery disease. *Ann Thorac Surg* 70:1699-701.

Kappert U, Schneider J, Cichon R, et al. 2000. Wrist-enhanced instrumentation: moving toward totally endoscopic coronary artery bypass grafting. *Ann Thorac Surg* 70:1105-8.

Klima U, Falk V, Marinka M, et al. Magnetic vascular coupling for distal anastomosis in coronary artery bypass grafting: a multicenter trial. *J Thorac Cardiovasc Surg*. In press.

Mohr FW, Falk V, Diegeler A, et al. 2001. Computer-enhanced "robotic" cardiac surgery: experience in 148 patients. *J Thorac Cardiovasc Surg* 121:842-53.

Niinami H, Takeuchi Y, Ichikawa S, et al. 2001. Coronary artery bypass-grafting using interrupted anastomosis with the U-clip [in Japanese]. *Kyobu Geka* 54:1003-6.

## REVIEW AND COMMENTARY

### 1. Editorial Board Member EI330 writes:

- This study needs institutional review board (IRB) approval, because cadavers were used for this study (mandatory).
- Please comment on the risk and benefit of right- and left-side approaches.
- Please comment on the possible differences between cadavers and operation on real patients. Do you think any modification of the surgery is required?

### Authors' reply by Hubert Stein:

- IRB approval was not required for our cadaver study.
- The risk is the same for right-side and left-side approaches. Care needs to be taken when placing the right instrument port in the right chest, because the diaphragm can run very superiorly, and one could puncture the liver. Therefore, endoscopic imaging for port placement is a must. The different approaches mainly affect the exposure to the target vessels. Access for the RCA is better from the right side, whereas the LAD and the Cx can be accessed more easily from the left side. Because the distance from the chest wall to the heart is longer on the right side than on the left side, the right-side approach offers more endoscopic work space and facilitates better anterior tissue exposure with the telemanipulatory instrumentation.
- In the cadaver model, you do not have the beating heart, which in a real patient can obscure access during a bilateral ITA mobilization. In addition, the vessels are not filled, making the identification of target areas on the heart more difficult. A real patient's body wall would provide a tight seal around the cannulae, avoiding the loss of carbon dioxide insufflation that can happen during experimental manipula-

tions with cadavers. All insertion and removal of additional material from the thoracic cavity in a real patient need to be done under a "sealed" condition to avoid the loss of carbon dioxide. Modifications requiring excellent endoscopic stabilization of all target areas are needed for a beating heart procedure. In a closed-chest, arrested-heart case, the procedure would be similar to the described approach.

### 2. Editorial Board Member AX44 writes:

This study addresses the question, "Is it realistically possible to do an endoscopic coronary artery bypass graft?" The authors expressed optimism. I am not as encouraged. The importance of this avenue of research cannot be overemphasized, but I think we are a long way from the goal, which the complexity of this paper makes very clear. A week does not go by that I am not asked if I can do this. We as a group have raised the expectations of the public to an unreasonable level that endoscopic cardiac surgery is just around the corner. This paper demonstrates that the corner is a long way down the road.

### Authors' reply by Hubert Stein:

We agree with the reviewer in this respect. Closed-chest, triple-vessel bypass grafting is not right around the corner. Nevertheless, double-vessel TECAB procedures on the arrested heart, as well as single-vessel TECAB on the beating heart, have been performed by different cardiac centers. This paper shows "work in progress" to achieve totally endoscopic myocardial multivessel revascularization and is by no means meant to provide a full concept of this procedure. As outlined in the text, all target vessels can be reached endoscopically, and bypass grafting can be performed, at least on the nonbeating heart in cadavers. No claim is made that this operation is ready for a clinical application. Such application will require the cooperation of surgeons and industry to develop the tools necessary to finally make this path a drivable roadway.

### 3. Editorial Board Member AR11 writes:

This is a well-written paper in a rapidly evolving area, even if it is only a "feasibility" paper. I would recommend that the authors discuss more fully the method used to test anastomoses (the "Materials and Methods" section alludes to the process of injecting the ascending aorta with saline but is insufficiently descriptive of its use in graft testing).

### Authors' reply by Hubert Stein:

All distal anastomoses were tested with pressurized saline injection and found to be competent without major leakage. This finding is in accord with most clinical reports on endoscopic telemanipulator-assisted bypass grafting in which distal anastomotic leakage was a rare finding. Concerning the proximal anastomosis of the vein graft to the aorta, we mention that it was technically difficult to perform the anastomosis. This difficulty was due to these devices having been designed to work best on a pressurized aorta, which was obviously difficult to achieve in a cadaveric model. If anything, these connectors should perform better in a live patient.

However, it is the belief of the authors that proximal anastomoses on the aorta should be avoided altogether in an endoscopic setting, because any bleeding from the aorta will be difficult to control. The best alternative would be completely

arterial revascularization using one or both ITA grafts and a radial artery T graft, which can be easily constructed endoscopically. This alternative would obviate complex proximal connectors and provide a better long-term outcome.