

# Transvaginal sonographic evaluation of endometrial polyps: a comparison with two dimensional and three dimensional contrast sonography

R. La Torre<sup>1</sup>, M.D.; C. De Felice, M.D.; C. De Angelis<sup>2</sup>, M.D.; F. Coacci, M.D.; M. Mastrone, M.D.; E. V. Cosmi, M.D., L.D.

*2<sup>nd</sup> Institute of Obstetrics and Gynecology, University of Rome "La Sapienza";  
1<sup>st</sup> Institute of Obstetrics and Gynecology, University of Rome "La Sapienza" (Italy)*

## Summary

Endometrial polyps are a frequent cause of menorrhagia and are often associated with infertility. Routine transvaginal (TV) ultrasound evaluation may detect intrauterine anomalies. Sonographic evaluation of the endometrium after uterine cavity distention, called hystero-sono-salpingography (HSSG), improves the resolutive effectiveness of TV sonography. Recently the development of three-dimensional (3D) scanning of the uterine cavity has provided accurate images.

The purpose of this study was to compare conventional 2D and 3D scanning of the uterine cavity with or without saline contrast medium in the detection and evaluation of focal endometrial polyps.

Twenty-three patients out of 642 women suggestive for intrauterine anomalies at routine TV sonogram were examined by 2D and 3D sonography before and after intrauterine saline contrast medium.

Sonographic appearance was verified by hysteroscopic and histologic evaluation.

Two-dimensional TV sonography diagnosed 23 polyps versus 16 confirmed at hysteroscopic and histologic examinations, revealing a specificity of 69.5%; 2D TV HSSG diagnosed 17 polyps, with a specificity of 94.1%; 3D TV sonography diagnosed 18 polyps, with a specificity of 88.8%; 3D HSSG diagnosed 16 polyps according to hysteroscopic and histologic findings, with a specificity of 100%.

HSSG has been demonstrated to be an effective and suitable method in the detection of intrauterine anomalies, particularly with 3D sonography.

*Key words:* 2D Ultrasound; 3D Ultrasound; Hysteroscopy; Endometrial Polyps; Hystero-sono-salpingography.

## Introduction

Endometrial polyps, even if not always clinically detected, account for 6.8% of all cases of menorrhagia in women aged between 20 and 40 years and have been frequently associated with infertility [1].

Transvaginal (TV) two-dimensional (2D) ultrasound evaluation may detect uterine endocavitary anomalies but does not always distinguish myomas from endometrial polyps [2]. Sonographic evaluation of the endometrium after uterine cavity distention, called hystero-sono-salpingography (HSSG), improves the resolutive effectiveness of TV sonography [3].

Recently the development of three-dimensional (3D) scanning of the uterine cavity has provided more accurate images [4]. For example the coronal view through the entire uterine cavity demonstrates the relationship between endometrium and myometrium at the fundus and produces good views of the cornual angles. The purpose of this study was to compare conventional 2D and 3D scanning of the uterine cavity with and without saline contrast medium in the detection and evaluation of focal endometrial polyps.

## Materials and Methods

Six hundred and forty-two women aged between 35 and 45 years underwent routine TV sonographic evaluation for menorrhagia or infertility at the 2nd Institute of Obstetrics and Gynecology, University of Rome "La Sapienza", from January 1996 to December 1998. All ultrasound examinations were performed between the 7<sup>th</sup> and the 14<sup>th</sup> day of the menstrual cycle by the same operator.

Twenty-three patients were enrolled in a prospective study because of hyperechogenic areas of the endometrial cavity suggestive of polypoid lesions. All the patients enrolled in the study were evaluated again with 2D and 3D sonography and with 2D and 3D hystero-sono-salpingography (HSSG).

The 2D TV sonography and Color Doppler study were carried out with an Aloka SSD-2000, 5 Mhz TV probe. The 3D TV sonography was carried out with a Combison 530 (Kretztechnik, Austria) equipped with a multifrequency TV 3D probe (5-7.5 Mhz).

The echo-pattern of the lesions was characterized by the uniformity of the echogenicity in comparison to the myometrium one. The uterine cavity was distended with contrast medium using the following technique: a 5 French catheter with a 5 ml retention balloon was introduced through the cervix after the cervix and upper vagina had been cleaned with a 10% povidone solution. A negative contrast medium, sterile saline solution, was then injected into the uterine cavity. Up to 20 ml were necessary to distend the endometrial cavity.

The distended endometrial cavity was scanned again with 2D

and 3D TV sonography. The images were then stored for 3D rendering. The images obtained with 3D sonography were compared with those obtained with 2D TV sonography.

All 23 patients underwent hysteroscopy. Hysteroscopic evaluations were completed with endocavitary biopsy directed to the lesion sonographically detected.

## Results

The sonographic and histological findings are summarized in Tables 1 and 2. No clinical complications were observed after sonographical procedures.

Two-dimensional TV sonography diagnosed 23 polyps versus 16 confirmed at hysteroscopic and histologic examinations, revealing a specificity of 69.5%; 2D TV HSSG diagnosed 17 polyps, with a specificity of 94.1; 3D TV sonography diagnosed 18 polyps (Fig. 1), with a specificity of 88.8%; 3D HSSG diagnosed 16 polyps according to hysteroscopic and histologic findings, with a specificity of 100%.

## Discussion

Fluid injection under 2D TV sonography confirmed the presence of endometrial polyps in 17 out of 23 patients. The 3D scanning confirmed the presence of endometrial polyps in 18 cases. After saline solution injection only 16 cases were suggestive of endometrial polyps according to the following hysteroscopic and histologic findings. The lesions detected at routine ultrasonography ranged in size from 2 to 18 mm. The lesions were classified according to their echogenicity in uniformly hyperechogenic, hypoechogenic and heterogeneous hyperechoic compared with myometrium echogenicity. One of the lesions diagnosed as a complicated polyp at ultrasound measured 17 mm in size and appeared like a focal and heterogeneous hyperechoic lesion. The microscopic finding showed an hemorrhagic polyp.

Table 1. — *Hysteroscopy vs sonographic diagnosis.*

	Hysteroscopy	2D TV Sonography		3D TV Sonography	
		without contrast	with contrast	without contrast	with contrast
Polyps	16	23	17	18	16
Normal endometrium	3	0	2	3	3
Endometrial hyperplasia	4	0	4	2	4

Table 2. — *Sonographic characteristics.*

	Benign endometrial polyps (no. 16)	Thickened endometrium (no. 4)	Normal endometrium (no. 3)
Mean size	10 mm	8 mm	2 mm
Echogenicity	Focal uniformly hyperechoic	Diffuse heterogeneous hyperechoic	Diffuse uniformly hyperechoic
Vascularity	Steam vessels	Peripheral endometrial vessels	Peripheral endometrial vessels

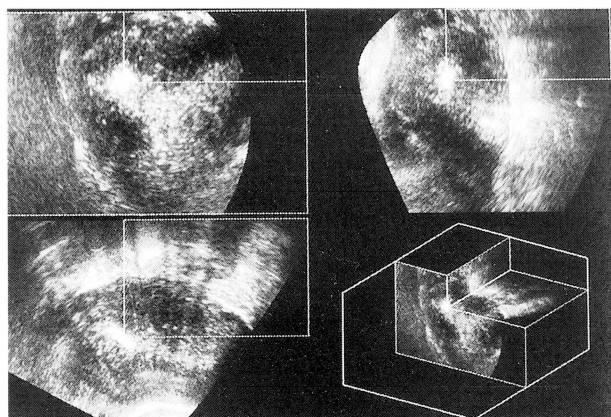


Figure 1. — Three orthogonal planes and 3D renderings of endometrium show the uterine cavity with an endometrial polyp located in the right horn.

## Conclusion

The techniques for uterine cavity assessment such as hysterosalpingography (HSG), magnetic resonance imaging (MRI) and hysteroscopy are more uncomfortable for the women in comparison to ultrasonography. HSG involves ovarian irradiation and has a low specificity for lesions smaller than 1 cm in diameter; MRI is too expensive and hysteroscopy is a quite invasive procedure even if new microtelescopes have been developed recently.

TV sonographic screening, particularly in the late proliferative phase, suggests the presence of polyps when a hyperechoic area is visualized within the endometrial stripe [3], but assessment of the uterine cavity can be particularly difficult if the endometrial lining is not well-defined. The use of Color Doppler provides the visualization of thick-walled blood vessels that helps in identifying polyps [5].

The sensitivity of TV ultrasound can be improved by using intrauterine contrast medium to distend the uterine cavity. This allows detailed examination of the endometrial lining and every distortion of the cavity can be assessed [3]. It is a simple, inexpensive and minimally invasive technique. The procedure is well tolerated and appears to be associated with low morbidity [3]. Recently 3D rendering of the uterine cavity has improved diagnostic accuracy [4, 6, 7] because it permits the observation of the entire uterine cavity [7]. One of the advantages of 3D technology is the capacity to visualize the three orthogonal planes at the same time. In this way polyps can be clearly observed [6]. The definition of the polyp is very high (Fig. 1), allowing one to know the exact size of the implantation base and its location, which leads to a greater use of hysteroscopic surgery.

Difficulties we encountered during the 3D imaging process depended on the quantity of the contrast medium which was used to distend the uterine cavity. In 8 of the 23 patients we were unable to perform any 3D rendering using only 20 ml of saline solution. In these cases the uterine cavity was too small and distorted and the inver-

sion of the intensity did not produce good surface rendering, so we added 10 ml of saline solution. Other difficulties we encountered during 3D rendering were connected to the possibility of motion formation during volume acquisition.

In our experience 2D and 3D contrast sonographic findings correlate highly with pathology detected at hysteroscopy. It has been suggested that 3D scanning can reduce the false positive rates of the conventional 2D one. According to our results 3D contrast ultrasound was able to provide accurate information not revealed by 2D contrast sonography. However, at present, the expense of 3D scanning restricts its use to very specialized centers.

Our study shows that 2D and 3D contrast sonography are effective and safe methods which allow us to perform uterine cavity screening to identify patients with pathology suitable for operative hysteroscopy.

We believe, however, that further studies would confirm the primary role of HSSG, particularly by 3D sonography, in intrauterine anomaly diagnosis.

## References

- [1] Hemricksen E.: "Cause of meno-metrorrhagia". *Am. J. Obstet. Gynecol.*, 1991, 41, 179.
- [2] Fedele L., Bianchi S., Dorta M., Brioschi D., Zanotti F., Vercellini P.: "Transvaginal ultrasonography versus hysteroscopy in the diagnosis of uterine submucous myomas". *Obstet. Gynecol.*, 1991, 77, 745.
- [3] Syrop C. H., Sahakian V.: "Transvaginal sonographic detection of endometrial polyps with fluid contrast augmentation". *Obstet. Gynecol.*, 1992, 79, 1041.
- [4] Ayda G., Kennedy S., Barlow D., Chamberlain P.: "Contrast sonography for uterine cavity assessment: a comparison of conventional two-dimensional with three-dimensional transvaginal ultrasound; a pilot study". *Fertil. Steril.*, 1996, 66, 848.
- [5] Aleem F., Predanic M., Calame R., Moukhtar M., Pennisi J.: "Transvaginal Color Doppler and Pulsed Doppler sonography of the endometrium: a possible role in reducing the number of dilatation and curettage procedures". *J. Ultrasound Med.*, 1995, 14, 139.
- [6] Kupfer M. C., Schiller V. L., Hansen G. C., Tessler F. N.: "Transvaginal sonographic evaluation of endometrial polyps". *J. Ultrasound Med.*, 1994, 13, 535.
- [7] Balen F. G., Allen C. H., Gardener J. E., Siddle N. C., Less W. R.: "3-Dimensional reconstruction of ultrasound images of the uterine cavity". *Brit. J. Rad.*, 1993, 66, 588.

Address reprint requests to:  
RENATO LA TORRE, M.D.  
2nd Institute of Obstetrics and Gynaecology,  
Policlinico Umberto I,  
University of Rome "La Sapienza"  
00161 Rome (Italy)

## Endometriosis 2000 7th Biennial World Congress

LONDON 14-17 May, 2000

at the QEII Conference Centre, under the auspices of the Royal College of Obstetricians & Gynaecologists

### Local Organising Committee

David Barlow, D. Keith Edmonds, Robert W. Shaw (Co-Chairman), Stephen K. Smith, Christopher J. G. Sutton, Allan Templeton, Eric J. Thomas (Co-Chairman) and Angela Barnard (National Endometriosis Society).

### Provisional Scientific Programme

The scientific programme is expected to comprise three plenary sessions, four symposia or free paper sessions, two poster sessions and two video sessions. In addition it is envisaged that three will be two symposia sponsored by industry. Neither the plenary sessions nor the symposia will be run in parallel with any other session. The theme of the Congress is endometriosis. Pre- and post-Congress meetings are planned. The International Scientific Committee will be soliciting abstracts for the free paper, poster and video sessions – please do not send your abstract now as full details will be published in the Second Announcement.

### Topics will include

Pain; Evidence-based medicine: Infertility & endometriosis; Damage (including adhesion formation); Frontiers in research; Recurrent and distant endometriosis; Current controversies in endometriosis; New therapeutic agents.

The official language of the Congress will be English and simultaneous translation of the proceedings will not be provided.

Deadline for submission of abstracts: 21 January, 2000. Last date for early registration: 17 March, 2000

Congress days: 14-17 May, 2000

---

### Congress Secretariat:

CAROLINE RONEY MEDICAL CONFERENCE ORGANISERS

Congress House, 65 West Drive, Cheam, Sutton, Surrey SM2 7NB, UK

Tel. ++44 (0) 181 661 0877 - Fax +44 (0) 181 661 9036 - E-mail: MedConfOrg@aol.com.