

The Use of Stentless Valves for Root Replacement During Repair of Ascending Aortic Aneurysms with Aortic Valve Regurgitation

(#2001-40913 ... August 23, 2001)

Belhhan Akpınar, MD,¹ Mustafa Güden, MD,¹ Saide Aytekin, MD,² İlhan Sanisoglu, MD,¹ Ertan Sagbas, MD,¹ Ugur Özbek, MD,³ Baris Çaynak, MD,¹ Z. Bayramoglu, MD¹

Kadir Has University Medical Faculty, Florence Nightingale Hospital, Istanbul, Turkey,
Departments of Cardiac Surgery,¹ Cardiology,² and Anesthesia.³



Dr. Akpınar

ABSTRACT

Background: Early and mid-term results of stentless valves for the treatment of ascending aortic aneurysm (AAA) were evaluated in a retrospective manner.

Material and Methods: During a four-year period, 26 patients with ascending aortic aneurysms and aortic valve insufficiency underwent a total root replacement procedure using a stentless "Freestyle" valve (Medtronic Inc., Minneapolis MN). Mean age was 71 ± 4 years (range 66 to 79 years). Eight patients were in NYHA Class 2, 13 in Class 3, and 5 in Class 4. Cardiopulmonary bypass (CPB) was begun with femoral artery-right atrium (two-stage) cannulation in all cases but four, in which the right axillary artery was used. Myocardial protection was established by retrograde, cold-blood cardioplegia and direct antegrade blood cardioplegia from the right coronary ostium. The left ventricle outflow tract was constructed by using 2-0 ticon sutures and incorporating a pericardial strip in between. Coronary buttons were sewn to the xenograft with 6-0 polypropylene sutures. Meanwhile, the patient was cooled down to 18 degrees nasopharyngeal temperature and the distal anastomosis with the proximal arch was performed with a Dacron graft under total circulatory arrest (TCA), using 4-0 polypropylene sutures. During rewarming, the connection between the Freestyle valve and the Dacron graft was performed.

Results: Ischemic time was 91 ± 11 minutes and TCA time was 9 ± 4 minutes. Operative mortality was zero, and there was one 30-day mortality (3.8%). At discharge, all 25 patients had a functional valve with low transvalvular gradients. Patients were followed for a mean period of 15 months, with one patient being lost to follow-up and one patient dying of non-cardiac causes. Follow-up was 97% complete, and echocardiographic control during the follow-up period

revealed competent valves with gradients comparable to those at discharge. Two patients were screened with electron beam tomography (EBT) three years after the operation and there was no sign of wall or leaflet calcification. At the end of the 15 months (mean) follow-up, the functional capacity of the patients had improved significantly ($p < 0.05$).

Conclusions: Our early results suggest that use of the Freestyle valve in conjunction with a Dacron tube graft can be a good alternative for patients over 65 years of age who present with ascending aortic aneurysm with aortic valve insufficiency.

BACKGROUND

Ascending aortic aneurysm (AAA) with aortic valve insufficiency is a frequently encountered pathology. Total root replacement with a conduit consisting of a mechanical valve and a Dacron tube as described by Bentall and DeBono is still accepted as the gold standard of treatment for these patients [Bentall 1968]. However, the necessity of anticoagulation therapy and the high risk for thromboembolic events and bleeding complications make this treatment far from ideal, especially in the elderly population [Akpınar 1999]. We describe a group of patients with AAA and aortic regurgitation who underwent total root replacement using a stentless "Freestyle" valve (Medtronic Inc., Minneapolis MN), with continuity to the proximal arch established by a Dacron tube graft interposition.

MATERIALS AND METHODS

Between January 1996 and September 2000, 26 patients with AAA and aortic valve insufficiency underwent total root replacement with the Freestyle valve. There were 19 male and 7 female patients having a mean age of 71 ± 4 years. The mean aneurysm diameter was 5.8 ± 0.6 cm. There was one patient with a chronic Stanford Type A dissection (Table 1 ☉).

Selection criteria for this method were: (1) age greater than 65 years; (2) contraindication to oral anticoagulants; (3) deliberate request for a biological valve by the patient. Two patients were below 65 years of age but they could not use oral anticoagulants due to previous gastrointestinal bleeding.

Submitted August 17, 2001; accepted August 23, 2001.

Address correspondence and reprint requests to: Belhhan Akpınar, MD, Associate Professor, Department of Cardiac Surgery, Florence Nightingale Hospital, Abide'i Hurriyet Cad. No:280, Sisli, Istanbul, Turkey, Phone: 090 212 2398790, Fax: 090 212 2398791, Email: belb@turk.net

Table 1. Demographic Data of Patients

Age (mean)	71 ± 4 (range 61-78)
Gender (male/female)	19/7
Aneurysm diameter (cm) (mean)	5.8 ± 0.6 (range 4.9-7)
Aortic dissection (type A)	1

Operative Technique

The right femoral artery was exposed and cannulated for arterial return in 22 patients. In four patients with severe atherosclerotic disease of the femoral vessels, the right axillary artery was prepared. An 8 mm Goretex graft was anastomosed to the axillary artery, and the arterial cannula was introduced through the graft. In all cases CPB was established with a two-stage venous cannula in the right atrium, and the left ventricle was vented via the right superior pulmonary vein. While the patient was cooled down to 28°C, the aorta was clamped and cardioplegia administered. Retrograde blood cardioplegia in combination with direct antegrade cardioplegia from the right coronary ostium was used for myocardial protection. The aorta was transected, and both coronary ostia were mobilized on generous buttons of aortic wall. The remaining tissue of the valsalva was excised and the diseased aortic wall was removed. While the Freestyle valve was being washed, we developed inflow sutures using 2-0 ticon sutures (Davis Geck, Danbury, CT). We then trimmed the porcine valve to create openings for the mobilized coronary ostia, removing generous buttons of porcine aortic tissue from the left and right coronary sinuses indicated on the valve. A thin strip of pericardium was incorporated in the inflow suture line for hemostasis. Continuous 6-0 polypropylene sutures were used to reimplant each coronary ostium by means of its button of aortic wall in its corresponding sinus of valsalva. During this time, the patient was cooled down to 18°C nasopharyngeal temperature. A Dacron tube graft one size smaller than the Freestyle valve was anasto-

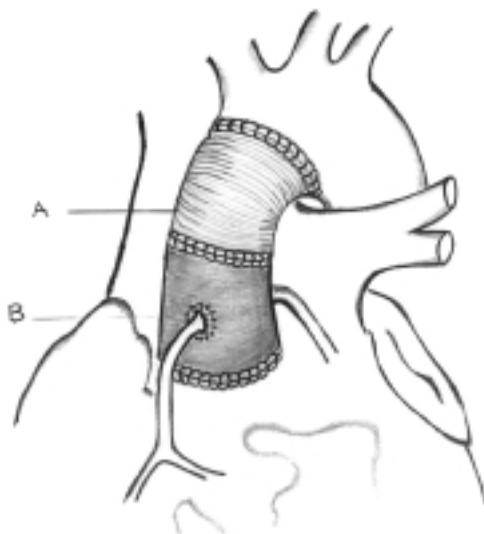


Figure 1.

mosed to the proximal arch using 4-0 polypropylene sutures and by incorporating a pericardial strip between the suture lines under total circulatory arrest (TCA) (Figure 1, ●). After this anastomosis was completed, the Dacron graft was clamped and circulation restarted. The connection between the Freestyle valve and the Dacron tube was established during rewarming also using 4-0 polypropylene sutures. We used four 25 mm, thirteen 27 mm, and nine 29 mm Freestyle valves. De-airing was performed using standard methods under transesophageal echocardiography (TEE) monitoring.

Two patients had a concomitant CABG procedure while one patient underwent a mitral valve repair.

Follow-Up Methods

Patients were followed for a mean period of 15 months (minimum 6 mo., maximum 40 mo.). Echocardiographic examination was performed at discharge and 15 months (mean) postoperatively.

RESULTS

All patients were weaned from CPB with moderate inotropic support. The mean cross-clamp time was 91 ± 11 minutes and mean CPB time was 120 ± 12 minutes, while TCA time was 9 ± 4 minutes (Table 2, ●). Operative mortality was zero and there was one 30-day mortality (3.8%). The patient who died had been readmitted to the hospital with a deep sternal wound infection five days after he was discharged. The infection did not respond to treatment and the patient died of sepsis 22 days after the operation. One patient was reoperated upon for bleeding and one patient developed a minor neurological deficit that resolved before discharge. Another patient had a prolonged ventilation period (Table 3, ●). Mean hospital stay was 9 ± 2 days. At discharge all patients had a competent valve with low transvalvular gradients. There was a slight decrease in transvalvular gradients during follow-up but this was not significant (Table 4, ●). One patient died of an unknown cause six months after the operation, and one patient was lost to follow-up. A patient who had mild mitral insufficiency during her first operation returned with severe mitral regurgitation one year later and underwent a mitral valve replacement. In the remaining patients, the mean functional class (NYHA) dropped significantly at the end of the 15-month follow-up period (Table 5, ●). During this time, no valve failure was detected. Electron beam tomography (EBT) of a patient 34 months after the operation showed no sign of wall calcification of the Freestyle valve (Figure 2, ●).

Table 2. Operative Data

Cross-clamp time (min.)	91 ± 11
By-pass time	120 ± 12
TCA time	9 ± 4
Associated Procedures	
CABG	2
Mitral valve repair	1

TCA = total circulatory arrest

Table 3. Complications

Bleeding	1
Pulmonary	1
Neurological	1
Infection	1

Statistical Analysis

All data are represented as mean \pm standard deviation. One-way analysis of variants (ANOVA) was used to test the significance of changes in measurements over the follow-up time.

DISCUSSION

Over the years, many surgical methods have been developed to treat AAA with aortic regurgitation [Mingke 1998, Shapira 1999]. The operation described by Bentall and DeBono continues to be the gold standard therapy for this pathology [Bentall 1968]. However, when it comes to the choice of the valve being used, there is no perfect device for this operation. Mechanical valves present the risk of thromboembolism, the need for anticoagulation, and bleeding complications. Stented biological valves are another option, but reoperation can be difficult in case of late degeneration since it is usually necessary to remove the entire conduit [Myken 1995, Akpinar 1999, Cartier 1999, Peterseim 1999]. Homografts may offer the ideal solution but they are not readily available, and reports of early wall calcification are disturbing [David 1994, Grodd 1995, Chon 1996, Cartier 1999]. Stentless xenografts are the porcine equivalent of the aortic homograft, with virtually identical flow characteristics [Westaby 1998c, Westaby 2000]. The concept of aortic valve replacement (AVR) with a stentless porcine valve originated with the pioneering work of O'Brien in the mid-1960s [O'Brien 1967]. Observation of optimal hemodynamics and hopes of longer durability due to absence of stents has revived attention for these valves [O'Brien 1967, Sidiropoulos 1997, Peterseim 1999]. Early and mid-term reports of ideal hemodynamic function comparable to homografts and the advantage of availability in all sizes have made the stentless valves highly attractive. The major advantages of stentless valves are better hemodynamics, fewer thromboembolic events, absence of dramatic failure, and increased durability [Westaby 1998a, Cartier 1999].

The combination of aortic root replacement with a xenograft and replacement of the ascending aorta with a Dacron tube is one of the proposed treatment options for this

Table 4. Echocardiographic Results

Valve size	Gradient (discharge)	Mean 13 months	AI
25	8 ± 1.1	7 ± 1.8	0
27	6 ± 1.5	5.0	0
29	4.0	3.2	0

AI = aortic insufficiency

Table 5. Improvement in Functional Class (NYHA)

Functional class	No. of patients pre-op	No. of patients after 6-44 months
1	0	20
2	8	2
3	13	1
4	5	0
N	26	23

NYHA = New York Heart Association

pathology. However, bleeding at the suture line between the two components can be troublesome, especially if the anastomosis is under tension [Urbanski 1999]. Urbanski and Hacker explained a method in which a valved composite graft consisting of a stentless valve and a Dacron tube prosthesis was prepared in the operating room after the annulus was measured. The stentless valve was sewn to the aortic annulus together with the tube graft using 4-0 polypropylene suture passing through both the vascular tube and the valve. The authors had to abandon this technique because of bleeding problems, and in later attempts they first sewed the valve to the tube graft and then anastomosed the tube graft to the aortic annulus with interrupted pledgeted sutures [Urbanski 1999, 2000]. The drawback to this option is that the assembly of the composite graft during surgery prolongs the ischemic arrest time and makes the procedure more complicated.

In our experience the major advantage of the Freestyle valve is its versatility. It can be used as a whole root or a mini-root, or a subcoronary implantation can be performed during ordinary AVR [Kon 1995]. An account of a root inclusion procedure with this valve for the treatment of an acutely dissected root in an elderly patient was published by Westaby [Westaby 1998b]. Excellent early and mid-term results (7 years) have

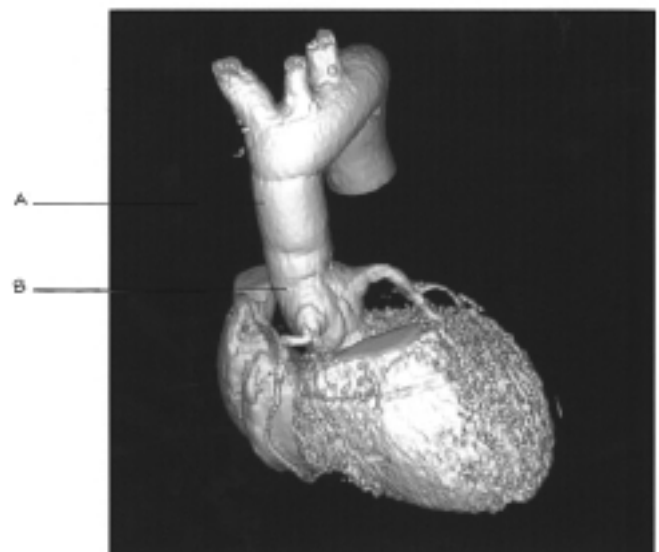


Figure 2.

made this valve our choice for patients undergoing AVR who are over 65 years of age [Cartier 1999]. This valve was an appealing option for our patients in this series because most of them were elderly and two could not use anticoagulants.

Replacement of the aortic valve with a stentless xenograft is a more demanding surgical procedure, and attention to detail is essential. There are some technical points that have to be mentioned. Myocardial protection with retrograde blood cardioplegia and direct cardioplegia from the right coronary ostia is very important, especially for right ventricle protection. Taking deep sutures from the annulus and incorporating a strip of pericardium between the Freestyle valve and the annulus is very helpful for hemostasis. The coronary ostia have to be freed completely and the corresponding openings on the Freestyle valve have to be generous in order to prevent tension. We advise the enlargement of the openings on the Freestyle valve to prevent any kinking of the coronary ostia and to permit a tension-free anastomosis. Finally, the length of the tube graft has to be measured correctly. A graft that is too short will cause tension on the anastomosis and may lead to bleeding and dehiscence, which has been reported by some authors [Urbanski 1999]. On the other hand, a graft that is too long may cause kinking, but this can be resolved with external traction sutures outside the graft.

The major drawback of the method is the need for a second tube graft to reach the proximal arch because the Freestyle valve is not long enough. This additional procedure requires a short time of TCA and prolongs the ischemic time. However, with good myocardial protection this is of minor importance. The problem of insufficient graft length may be solved in the near future with the introduction of longer Freestyle conduits (Medtronic Files, personal communication). Another criticism of the method may be the difficulty of a future reoperation caused by porcine aortic wall calcification. It is difficult to comment on this problem since we have not experienced it so far. EBT views of two patients three and four years after the operation revealed no sign of calcification over the porcine aortic wall, which is a promising sign. Cartier et al. have recently reported less wall calcification on the Freestyle valve than the homograft after 18 months of follow-up [Cartier 1999]. However, for the moment we agree with others who have suggested that the general guidelines for the use of other bioprostheses should be applied to these valves until longer term results are available. Although only the test of time, as reflected in results over ten years after implantation, will prove the value of these valves, the results so far are encouraging. There are numerous papers that confirm the effectiveness of cardiac and systemic physiological rehabilitation with the Freestyle valve leading to resolution of left ventricle hypertrophy and a low incidence of valve-related complications [Westaby 1998a, 1998b].

CONCLUSIONS

The technique of using the Freestyle valve and a Dacron tube graft provides a good alternative for patients who have an aortic aneurysm and require replacement of both the valve and the aneurysmal segment. If the patients are over 65 years of age one cannot use oral anticoagulants. The technique will become easier and more widely applied with the introduction

of longer Freestyle-valved conduits that can reach the proximal arch and thereby avoid the use of an additional tube graft.

REFERENCES

1. Akpınar B, Sanisoglu I, Konuralp C, et al. The use of a stentless porcine bioprosthesis. *Tex Heart Ins J* 26:195-7, 1999.
2. Bentall H, DeBono A. A technique for complete replacement of the ascending aorta. *Thorax* 23:338-9, 1968.
3. Cartier CP, Dumensil GJ, Metras J, et al. Clinical and hemodynamic performance of the Freestyle aortic root bioprosthesis. *Ann Thorac Surg* 67:345-51, 1999.
4. Chon LH, Rizzo RJ, Adams DH, et al. Reduced mortality and morbidity for ascending aortic aneurysm resection regardless of cause. *Ann Thorac Surg* 62:463-8, 1996.
5. David TE, Feindel CM, Bos J, et al. Aortic valve replacement with a stentless porcine aortic valve: a six year experience. *J Thorac Cardiovasc Surg* 108:1030-36, 1994.
6. Grodd C, Hasinger W, Mair R, et al. Aortic valve replacement: Is the stentless xenograft an alternative to the homograft? *Ann Thorac Surg* 60:S 418-21, 1995.
7. Kon ND, Westaby S, Amarensa N, et al. Comparison of implant techniques using the Freestyle stentless porcine aortic valve. *Ann Thorac Surg* 59:857-62, 1995.
8. Mingke D, Dresler C, Stone CD, et al. Composite graft replacement of the aortic root in 335 patients with aneurysm or dissection. *J Thorac Cardiovasc Surg* 46:12-19, 1998.
9. Myken PS, Caidahl K, Larsson P, et al. Mechanical versus biological valve prosthesis. *Ann Thorac Surg* 60:S447-S452, 1995.
10. O'Brien MF. Heterograft aortic valves for human use: valve bank, techniques of measurements and implantation. *J Thorac Cardiovasc Surg* 53:392-7, 1997.
11. O'Brien MF. Composite stentless xenograft for aortic valve replacement: clinical evaluation of function. *Ann Thorac Surg* 60:S406-9, 1995.
12. Shapira OM, Aldea GS, Cutter SM, et al. Improved clinical outcomes after operation of the proximal aorta. *Ann Thorac Surg* 67:1030-37, 1999.
13. Sidiropoulos A, Hotz H, Tschesnow J, et al. Stentless porcine bioprostheses for all types of aortic root pathology. *Eur J Cardiothorac Surg* 11:917-21, 1997.
14. Peterseim DS, Ye-Ying Cen, Cheruvu S, et al. Long term outcome after biologic versus mechanical aortic valve replacement in 841 patients. *J Thorac Cardiovasc Surg* 117:890-7, 1999.
15. Urbanski PP. Replacement of the ascending aorta and aortic valve with a valved stentless composite graft. *Ann Thorac Surg* 67:1501-02, 1999.
16. Urbanski PP, Hacker RW. Replacement of the aortic valve and ascending aorta with a valved stentless composite graft: technical considerations and early clinical results. *Ann Thorac Surg* 70:17-20, 2000.
17. Westaby S, Jin YK, Katsumata T, et al. Valve replacement with a stentless bioprosthesis: versatility of the porcine aortic root. *J Thorac Cardiovasc Surg* 116:477-84, 1998.
18. Westaby S, Katsumata T, Houel R, et al. Stentless xenograft repair of the dissected aortic root. *Ann Thorac Surg* 65:1448-50, 1998.
19. Westaby S, Horton M, Jin YK, et al. Survival advantage of stentless aortic bioprostheses. *Ann Thorac Surg* 70:785-92, 2000.
20. Westaby S, Huysmans HA, David TE. Stentless aortic bioprostheses. *Ann Thorac Surg* 65:235-40, 1998.

REVIEW AND COMMENTARY

1. Editorial Board Member RN41 writes:

This is a series with good results and offers another option in the treatment of patients with ascending aortic aneurysms. The jury is still out on the benefits of stentless valves, and the use of this valve varies markedly from center to center. The early results in this series are encouraging.

- a) During the same period, how many patients had an aortic root replacement with a composite graft (incorporating a mechanical valve)?
- b) Were there any contraindications to the use of this technique?

Authors' Response from Belhhan Akpinar, MD:

- a) During this period, 81 patients underwent aortic root replacement with a mechanical valve.
- b) One contraindication to the use of this technique would be young age (less than 60 years), and a second one would be a patient with severely depressed LV function undergoing concomitant procedures. For such a patient it might be wiser to use a composite graft that could shorten the ischemia time.

2. Editorial Board Member EK34 writes:

What is the difference between "operative" mortality and "30-day" mortality? You should list in-hospital or 30-day mortality.

What about brain function and/or neurological damage?

Authors' Response from Belhhan Akpinar, MD:

All patients survived the operation. In-hospital mortality was 3.7% (AU: 3.8%) (one patient). As for neurological

damage, one patient developed delirium on the second post-op day and had to be reintubated and sedated for two days. This problem was resolved in one week. There was no stroke or other neurological damage.

3. Editorial Board Member KE221 writes:

- a) The authors dismiss the option of using a stented xenograft within a Dacron tube by saying that replacement of the xenograft would require replacing the entire root prosthesis. This alternative should receive more discussion. First, durability is now excellent for modern stented xenografts in the older patients discussed in this paper, and there is little evidence that stentless valves are significantly more durable in older patients. Second, replacement of the Freestyle valve would also require replacing the entire root. Third, stented xenografts are very easy to incorporate into a Dacron graft at the time of surgery without the need for additional sutures, and with excellent hemostasis. Fourth, if a separate segment of graft is used for an anastomosis to the arch, the remaining anastomosis is an easy one between graft and graft.

Authors' Response from Belhhan Akpinar, MD:

Using a xenograft within a Dacron tube is another option in this group of patients. The author agrees that durability is excellent for modern stented grafts, but this requires the use of a stentless valve as a whole root. In any case, if reoperation becomes necessary, either valve would require re-replacing the root. As mentioned in the text, we have not had to reoperate for any of the Freestyle valves so far, but our experience with the two reoperations for the early Edwards Prima valve suggested to us that implanting a new valve within the previous tube was not possible.